A researcher is investigating the structure of the sarcomere using skeletal muscle obtained from an experimental animal. He develops monoclonal antibodies directed against a specific skeletal muscle protein and finds that these antibodies disrupt the binding of actin to structural support elements within the sarcomere. Electron microscopy of the sarcomere is shown in the image below.



Which of the following labeled regions do these antibodies most likely bind?

- A. A
- B. B
- C. C
- D. D
- E. E



Which of the following labeled regions do these antibodies most likely bind?

- ✓ A. A (47%)
- B. B (8%)
- C. C (12%)
- D. D (15%)
- E. E (13%)
- F. F (3%)

Omitted
Correct answer

47%
Answered correctly

14 secs
Time Spent

03/11/2020
Last Updated

Explanation

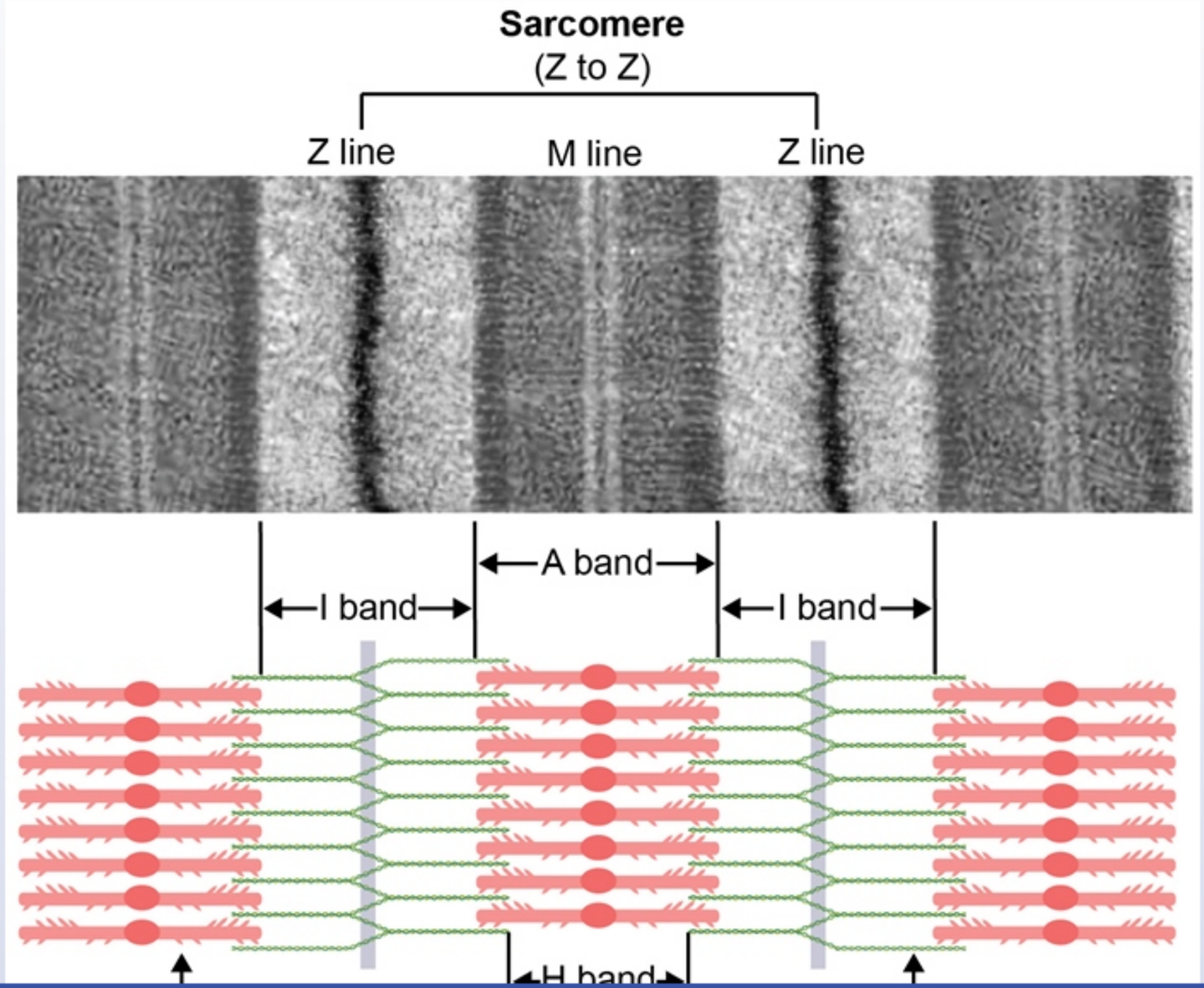

(Z to Z)

Exhibit Display

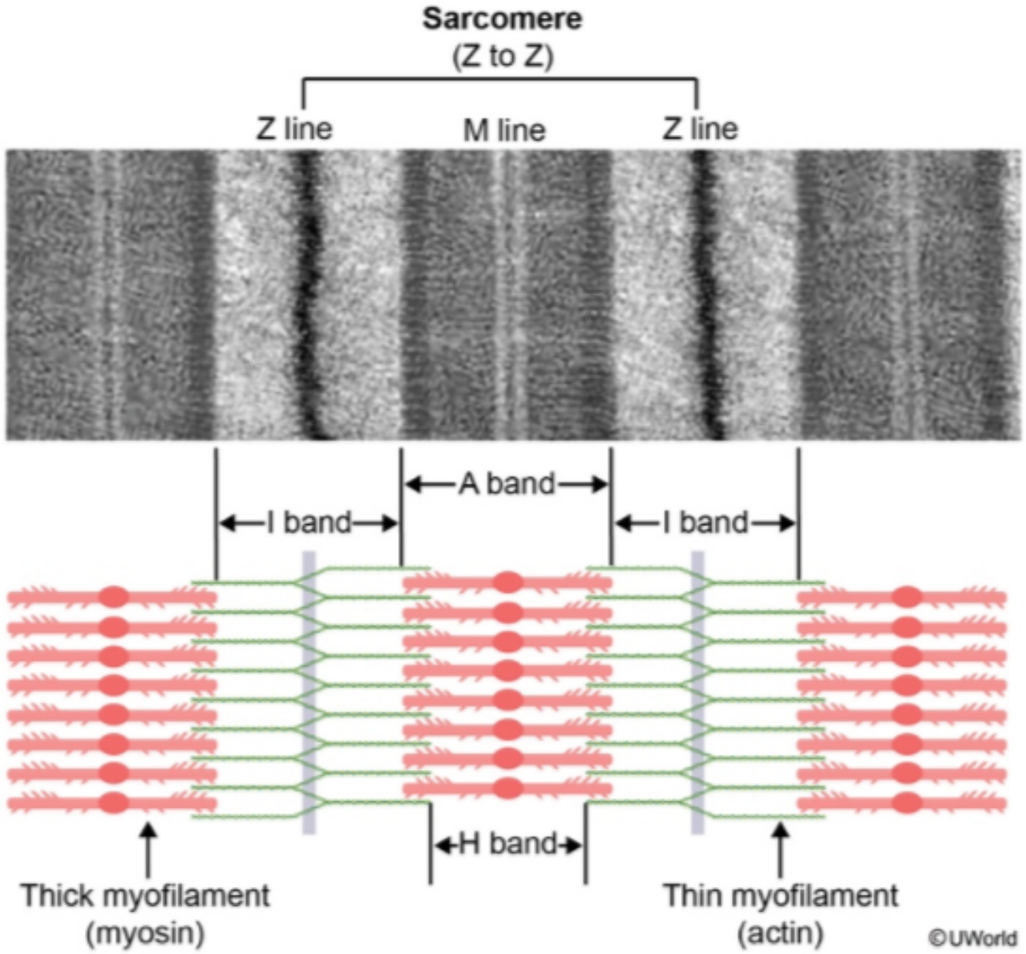

Zoom In | Zoom Out | Reset | Add To New Card | Existing Card

A **sarcomere** is composed of overlapping filaments of actin and myosin as well as structural and binding proteins (eg, titin, α-actinin). A single sarcomere is defined as the distance between two Z lines. **Thin (actin) filaments** are bound to structural proteins at the **Z line**. The unbound ends of the actin filaments project into the middle of the sarcomere, where they interact with thick (myosin) filaments during muscle contraction.

(Choice B) The A band corresponds to myosin filaments in the sarcomere. In this region, there are myosin filaments overlapped with actin filaments as well as non-overlapped myosin filaments. The A band always remains the same length during muscle contraction.

(Choice C) The M line lies at the center of the A band and is where myosin filaments anchor to structural elements in the center of the sarcomere.

(Choice D) Myosin and actin filaments overlap at the segment of the sarcomere between the H and I bands.

(Choices E and F) The I band is the region of the sarcomere in which actin does not overlap with myosin, and the H band is the region in which myosin does not overlap with actin. During muscle contraction, both H and I bands decrease in length.

Educational objective:
A single sarcomere is defined as the distance between two Z lines. Thin (actin) filaments in the I band are bound to structural proteins at the Z line, whereas thick (myosin) filaments in the A band are bound to structural proteins at the M line.

References

- The muscle ultrastructure: a structural perspective of the sarcomere.
- The sarcomeric cytoskeleton: from molecules to motion.

Histology	Rheumatology/Orthopedics & Sports	Muscle structure & physiology
Subject	System	Topic

Copyright © UWorld. All rights reserved.

A 28-year-old woman, gravida 3 para 3, comes to the emergency department with severe abdominal pain in the left lower quadrant and vaginal bleeding. She is saturating a pad every 3-4 hours. Her last menstrual period was 6 weeks ago. Past surgical history is significant for 3 cesarean deliveries and permanent sterilization via a bilateral tubal ligation. A urine pregnancy test is positive, and an ultrasound shows a 2-cm mass in the left adnexa adjacent to the ovary and a thickened endometrial stripe. If a uterine curettage is performed, which of the following findings would be expected in this patient?

A. Atypical endometrial cells, disorganized glands, and multiple mitoses

B. Dilated, coiled endometrial glands and edematous stroma

C. Enlarged chorionic villi and avascular edematous stroma

D. Inflammatory infiltration of endometrial glands

E. Straight, short endometrial glands and compact stroma

Submit

A 28-year-old woman, gravida 3 para 3, comes to the emergency department with severe abdominal pain in the left lower quadrant and vaginal bleeding. She is saturating a pad every 3-4 hours. Her last menstrual period was 6 weeks ago. Past surgical history is significant for 3 cesarean deliveries and permanent sterilization via a bilateral tubal ligation. A urine pregnancy test is positive, and an ultrasound shows a 2-cm mass in the left adnexa adjacent to the ovary and a thickened endometrial stripe. If a uterine curettage is performed, which of the following findings would be expected in this patient?

- A. Atypical endometrial cells, disorganized glands, and multiple mitoses (10%)
- ✓ B. Dilated, coiled endometrial glands and edematous stroma (56%)
- C. Enlarged chorionic villi and avascular edematous stroma (25%)
- D. Inflammatory infiltration of endometrial glands (3%)
- E. Straight, short endometrial glands and compact stroma (3%)

Omitted
Correct answer
B

56%
Answered correctly

02 secs
Time Spent

01/22/2020
Last Updated

Explanation

Ectopic pregnancy with ruptured fallopian tube

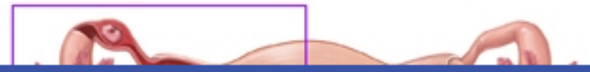

Settings

1
2
3
4
5
6
7
8
9
10
11
12
13
14
15
16
17
18
19
20
21
22
23
24
25
26

Item 2 of 26
Question Id: 334

Mark | Previous | Next | Full Screen | Tutorial | Lab Values | Notes | Calculator | Reverse Color | Text Zoom | Settings

Ectopic pregnancy with ruptured fallopian tube

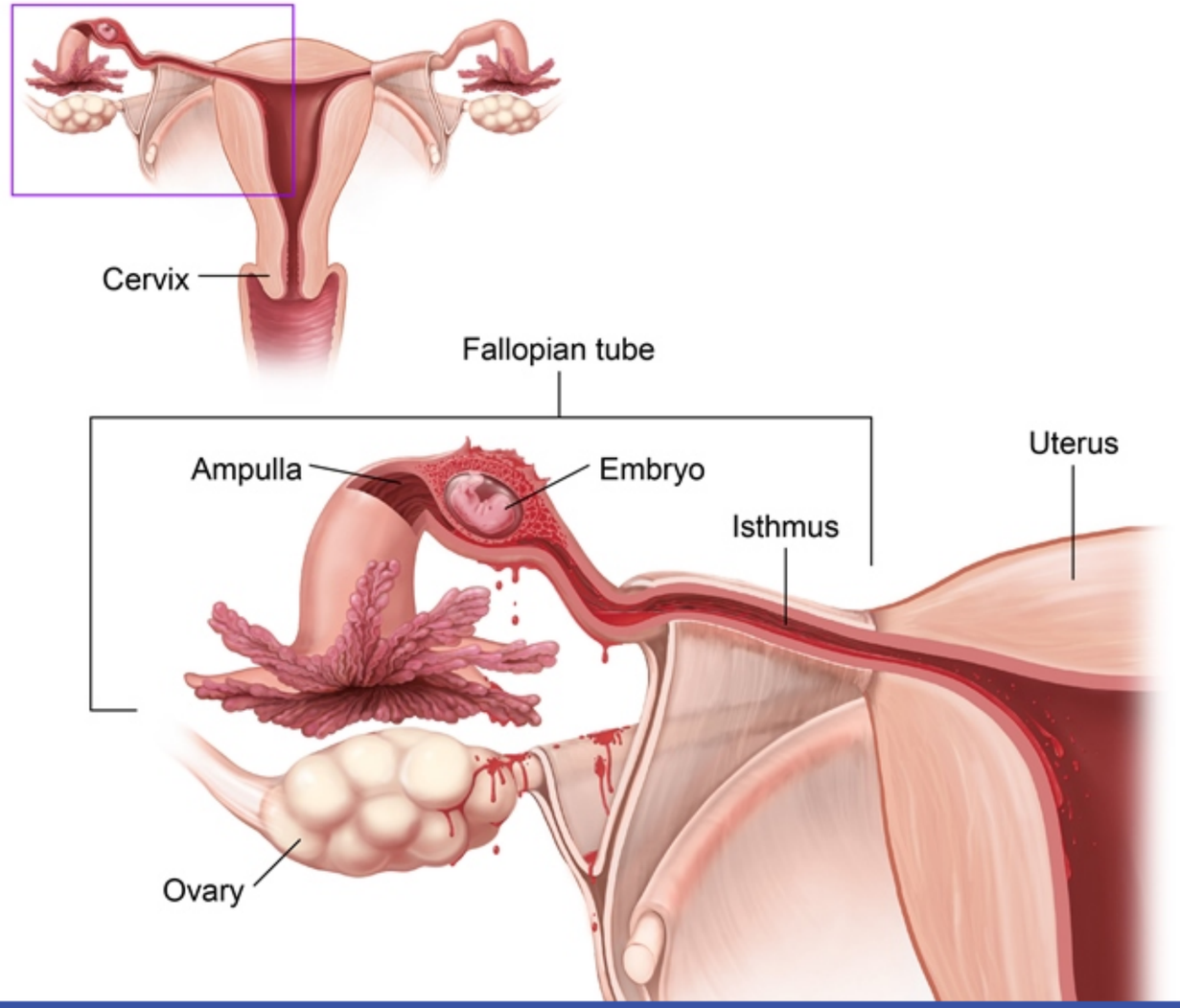

Block Time Remaining: 00:00:16
TUTOR

4 | Feedback | Suspend | End Block

©UWorld

Ectopic pregnancy occurs when a **fertilized ovum implants outside of the uterus**. The most common site is the **ampulla** of the fallopian tube, which may appear as an adnexal mass on ultrasound. Risk factors include tubal pathology, such as from previous infection or surgery (eg, **tubal ligation**). Pregnancy after permanent sterilization is extremely rare, but one-third of cases are ectopic if implantation occurs. An ectopic pregnancy may become life-threatening as the embryo and trophoblastic tissue proliferate. This growth will compromise the blood supply to the surrounding tissues, which can result in rupture and profuse intra-abdominal bleeding.

A ruptured ectopic pregnancy is managed surgically by removing the pregnancy and achieving hemostasis. Dilation and curettage of the uterus may be performed either to stop uterine bleeding or confirm whether the pregnancy is intrauterine or ectopic. In an ectopic pregnancy, the uterine specimen would reveal **decidualized endometrium** only, consistent with **dilated, coiled endometrial glands** and **vascularized edematous stroma**. These changes occur in the luteal phase of the menstrual cycle, under the influence of **progesterone**, as the endometrium prepares for implantation. Embryonic and trophoblastic tissue will be absent from the uterus.

(Choice A) The finding of atypical endometrial cells that form glands would suggest endometrial adenocarcinoma, a malignancy that typically occurs in postmenopausal women and manifests with vaginal bleeding.

(Choice C) A molar pregnancy or spontaneous abortion may present with vaginal bleeding. Uterine curettage may show enlarged chorionic villi and avascular edematous stroma. In contrast, intrauterine chorionic villi are absent in an ectopic pregnancy.

(Choice D) An inflammatory endometrial infiltrate would suggest endometritis, an infection of the decidua, which presents with uterine tenderness, fever, and tachycardia. An ectopic pregnancy is not an infectious process.

(Choice E) Straight, short endometrial glands and compact stroma are found in the early proliferative phase of the menstrual cycle. This microscopic appearance would be observed 4-7 days after the onset of menses.

Educational objective:
An ectopic pregnancy is characterized by implantation outside of the uterus. Uterine curettage would reveal decidual changes in the endometrium due to progesterone secretion but no embryonic or trophoblastic tissue (eg, no villi).

surrounding tissues, which can result in rupture and profuse intra-abdominal bleeding.

A ruptured ectopic pregnancy is managed surgically by removing the pregnancy and achieving hemostasis. Dilation and curettage of the uterus may be performed either to stop uterine bleeding or confirm whether the pregnancy is intrauterine or ectopic. In an ectopic pregnancy, the uterine specimen would reveal **decidualized endometrium** only, consistent with **dilated, coiled endometrial glands** and **vascularized edematous stroma**. These changes occur in the luteal phase of the menstrual cycle, under the influence of **progesterone**, as the endometrium prepares for implantation. Embryonic and trophoblastic tissue will be absent from the uterus.

(Choice A) The finding of atypical endometrial cells that form glands would suggest endometrial adenocarcinoma, a malignancy that typically occurs in postmenopausal women and manifests with vaginal bleeding.

(Choice C) A molar pregnancy or spontaneous abortion may present with vaginal bleeding. Uterine curettage may show enlarged chorionic villi and avascular edematous stroma. In contrast, intrauterine chorionic villi are absent in an ectopic pregnancy.

(Choice D) An inflammatory endometrial infiltrate would suggest endometritis, an infection of the decidua, which presents with uterine tenderness, fever, and tachycardia. An ectopic pregnancy is not an infectious process.

(Choice E) Straight, short endometrial glands and compact stroma are found in the early proliferative phase of the menstrual cycle. This microscopic appearance would be observed 4-7 days after the onset of menses.

Educational objective:
An ectopic pregnancy is characterized by implantation outside of the uterus. Uterine curettage would reveal decidual changes in the endometrium due to progesterone secretion but no embryonic or trophoblastic tissue (eg, no villi).

References

- Decidualization of the human endometrium: mechanisms, functions, and clinical perspectives.

Histology	Pregnancy, Childbirth & Puerperium	Ectopic pregnancy
Subject	System	Topic

Copyright © UWorld. All rights reserved.

surrounding tissues, which can result in rupture and profuse intra-abdominal bleeding.

Exhibit Display

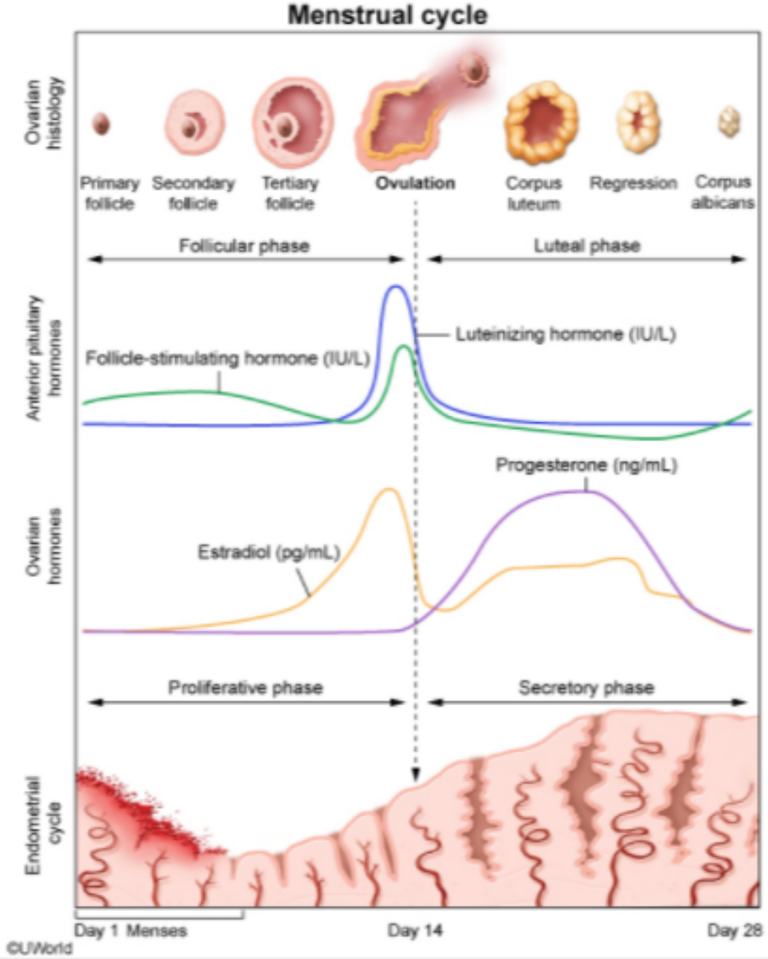

Zoom In | Zoom Out | Reset | Add To New Card | Existing Card

Settings

1
2
3
4
5
6
7
8
9
10
11
12
13
14
15
16
17
18
19
20
21
22
23
24
25
26

Item 2 of 26
Question Id: 334

Mark | Previous | Next | Full Screen | Tutorial | Lab Values | Notes | Calculator | Reverse Color | Text Zoom | Settings

Exhibit Display

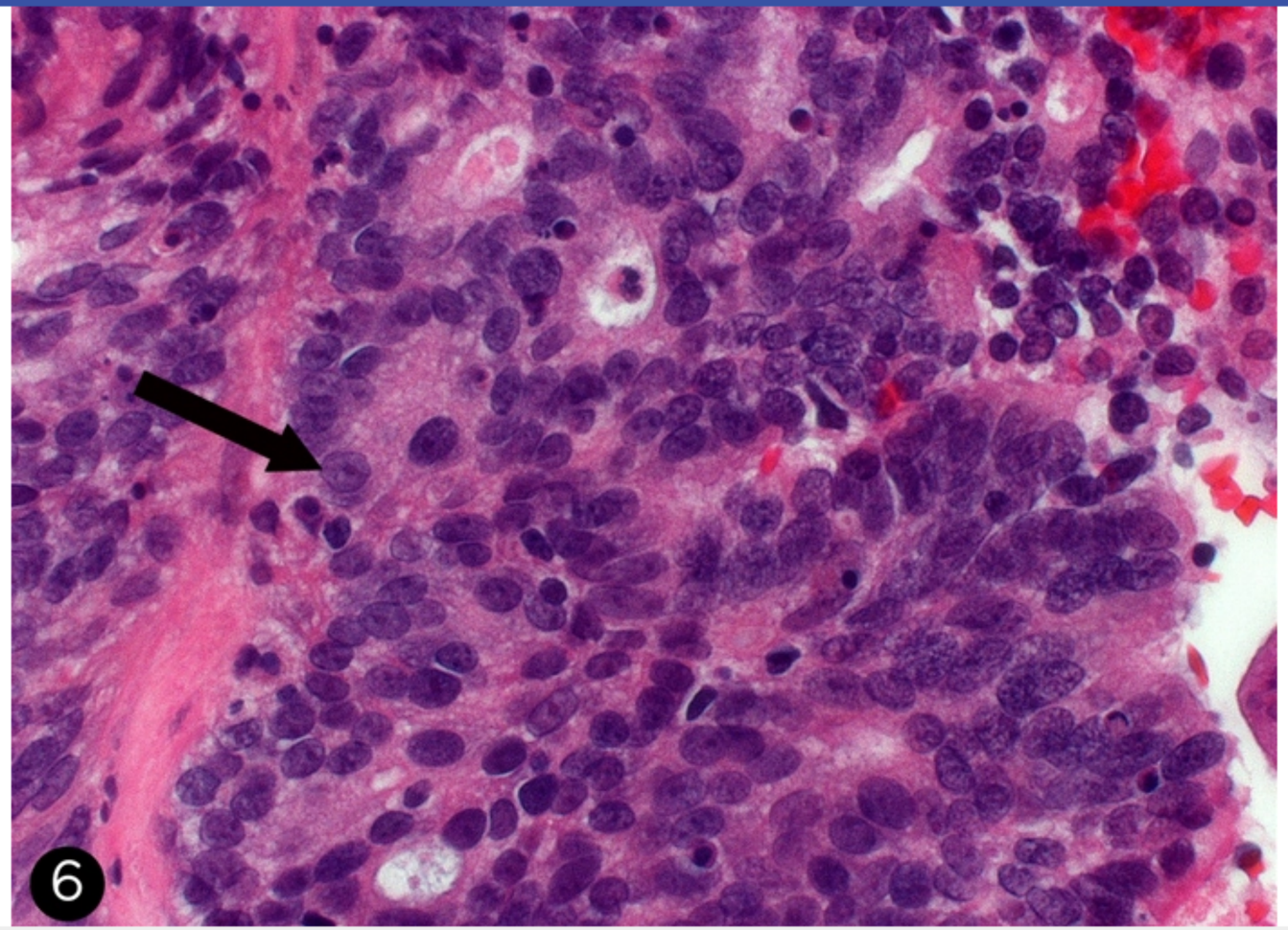

Zoom In | Zoom Out | Reset | Add To New Card | Existing Card

Block Time Remaining: 00:00:16
TUTOR

4 | Feedback | Suspend | End Block

Exhibit Display

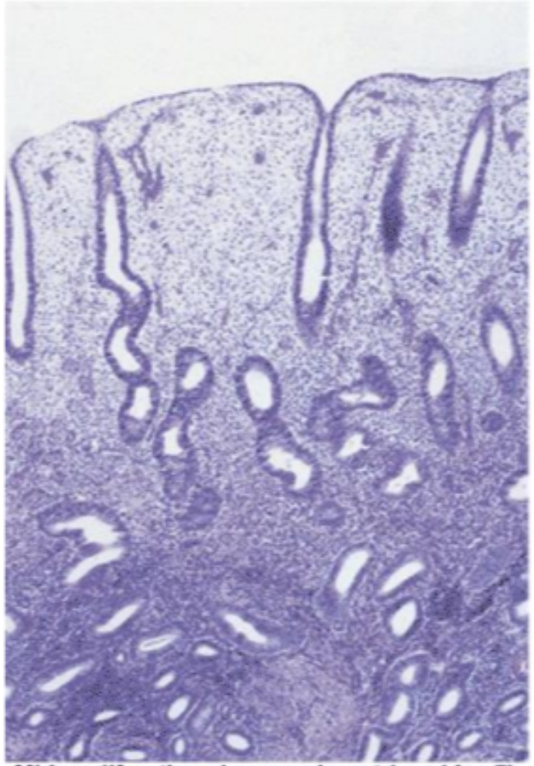

Mid-proliferative phase endometrium (day 7). The endometrium demonstrates uniform development, with a gland:stroma ratio of less than 1:1. The glands are straight and narrow, and contain small lumens.

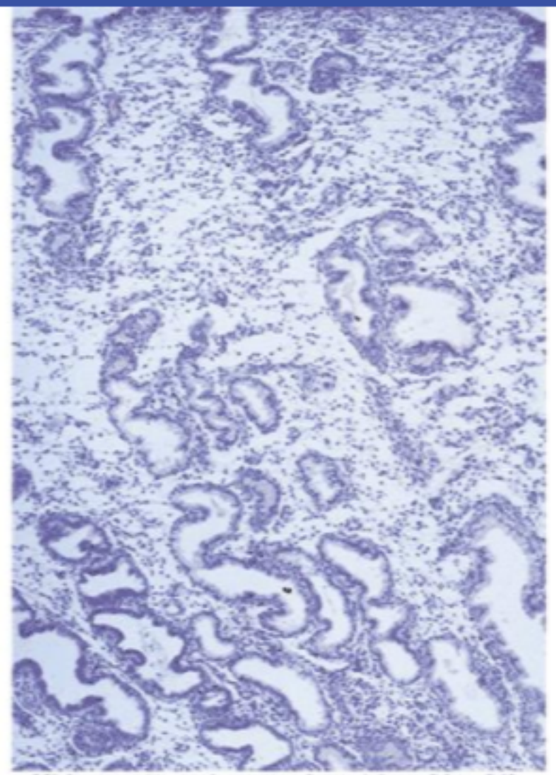

Mid-secretory phase endometrium (day 21). The gland:stroma ratio has increased to approximately 1:1 because the amplified stromal volume is associated with marked stromal edema. The glands are dilated and coiled, and contain wide lumens.

Displayed with permission from Current Medicine Group LLC © 2000.

Zoom In | Zoom Out | Reset | Add To New Card | Existing Card

A 23-year-old woman, gravida 2, para 1, comes to the labor and delivery unit at 39 weeks gestation with abdominal discomfort and regular contractions. The patient had an uncomplicated first pregnancy that resulted in a spontaneous vaginal delivery at full term 3 years ago, and the current pregnancy has been uncomplicated. She takes a prenatal vitamin daily and no other medications. In response to increasing estrogen levels, the myometrial cells start to express genes that encode connexin-43 and the oxytocin receptor. These molecular changes would result in increased formation of which of the following?

A. Adherens junctions

B. Desmosomes

C. Fenestrae

D. Gap junctions

E. Hemidesmosomes

F. Tight junctions

Submit

A 23-year-old woman, gravida 2, para 1, comes to the labor and delivery unit at 39 weeks gestation with abdominal discomfort and regular contractions. The patient had an uncomplicated first pregnancy that resulted in a spontaneous vaginal delivery at full term 3 years ago, and the current pregnancy has been uncomplicated. She takes a prenatal vitamin daily and no other medications. In response to increasing estrogen levels, the myometrial cells start to express genes that encode connexin-43 and the oxytocin receptor. These molecular changes would result in increased formation of which of the following?

- A. Adherens junctions (10%)
- B. Desmosomes (8%)
- C. Fenestrae (6%)
- ✓ D. Gap junctions (62%)
- E. Hemidesmosomes (3%)
- F. Tight junctions (9%)

Omitted
Correct answer
D

62%
Answered correctly

02 secs
Time Spent

02/19/2020
Last Updated

Explanation

Cell junctions

Cell junctions		
Type	**Proteins**	**Function**
Gap junction	Connexins	Intercellular communication
Tight junction	Claudins, occludin	Paracellular barrier
Adherens junction	Cadherins	Cellular anchor
Desmosomes	Cadherins (eg, desmogleins, desmoplakin)	
Hemidesmosomes	Integrins	

©UWorld

Initiation of labor requires a series of biochemical changes in the uterus and cervix mediated by endocrine changes. Cell junctions are multiprotein complexes that allow contact between adjacent cells or between a cell and the extracellular matrix. Communicating (gap) junctions are especially important during labor and delivery, which require coordination and synchronization of individual myometrial cells. Gap junctions permit diffusion of molecules between neighboring cellular cytoplasms through a connexon (cylinder with a central channel composed of 6 connexin proteins).

Immediately prior to delivery, **estrogen** stimulates upregulation of **gap junctions** between individual myometrial smooth muscle cells. An increase in gap junction density at delivery heightens **myometrial** excitability. Gap junctions consist of aggregated **connexin** proteins (eg, connexin-43)

©UWorld

Initiation of labor requires a series of biochemical changes in the uterus and cervix mediated by endocrine changes. Cell junctions are multiprotein complexes that allow contact between adjacent cells or between a cell and the extracellular matrix. Communicating (gap) junctions are especially important during labor and delivery, which require coordination and synchronization of individual myometrial cells. Gap junctions permit diffusion of molecules between neighboring cellular cytoplasms through a connexon (cylinder with a central channel composed of 6 connexin proteins).

Immediately prior to delivery, **estrogen** stimulates upregulation of **gap junctions** between individual myometrial smooth muscle cells. An increase in gap junction density at delivery heightens **myometrial** excitability. Gap junctions consist of aggregated **connexin** proteins (eg, connexin-43) that allow passage of ions between myometrial cells.

Estrogen also increases expression of uterotonic (eg, oxytocin) receptors, which mediate calcium transport through ligand-activated calcium channels. The combination of an increase in gap junction density and uterotonic receptors results in coordinated, synchronous labor contractions.

(Choices A and B) Both adherens junctions and desmosomes are composed of cadherins and are involved in intercellular adhesion. The cytoplasmic anchor of adherens junctions is the actin filament, whereas the cytoplasmic anchor of desmosomes is the intermediate filament. Autoantibodies against desmoglein, a cadherin protein for desmosomes, are found in pemphigus vulgaris.

(Choice C) Fenestrae are gaps between endothelial cells that allow for paracellular transport. Swollen fenestrae in renal glomerular capillary endothelial cells are implicated in preeclampsia (presents with new-onset hypertension and proteinuria or end-organ dysfunction at ≥20 weeks gestation).

(Choice E) Hemidesmosomes link cells to the basement membrane via integrins, the transmembrane anchor proteins. Autoantibodies to these proteins cause bullous pemphigoid and pemphigoid gestationis.

(Choice F) Tight junctions are comprised of claudins and occludin and serve as paracellular barriers to water and solutes. The enterotoxin from *Clostridium perfringens*, a common cause of food poisoning, binds claudin and interferes with tight junctions in the intestinal barrier. Water loss from the tissue to the intestinal lumen results in watery diarrhea.

Educational objective:
Gap junctions facilitate communication and coordination between cells and play an important role in labor contractions. Connexins are proteins that assemble into gap junctions and their density increases in the uterus before delivery in response to rising estrogen levels.

©UWorld

Exhibit Display

Cell junctions

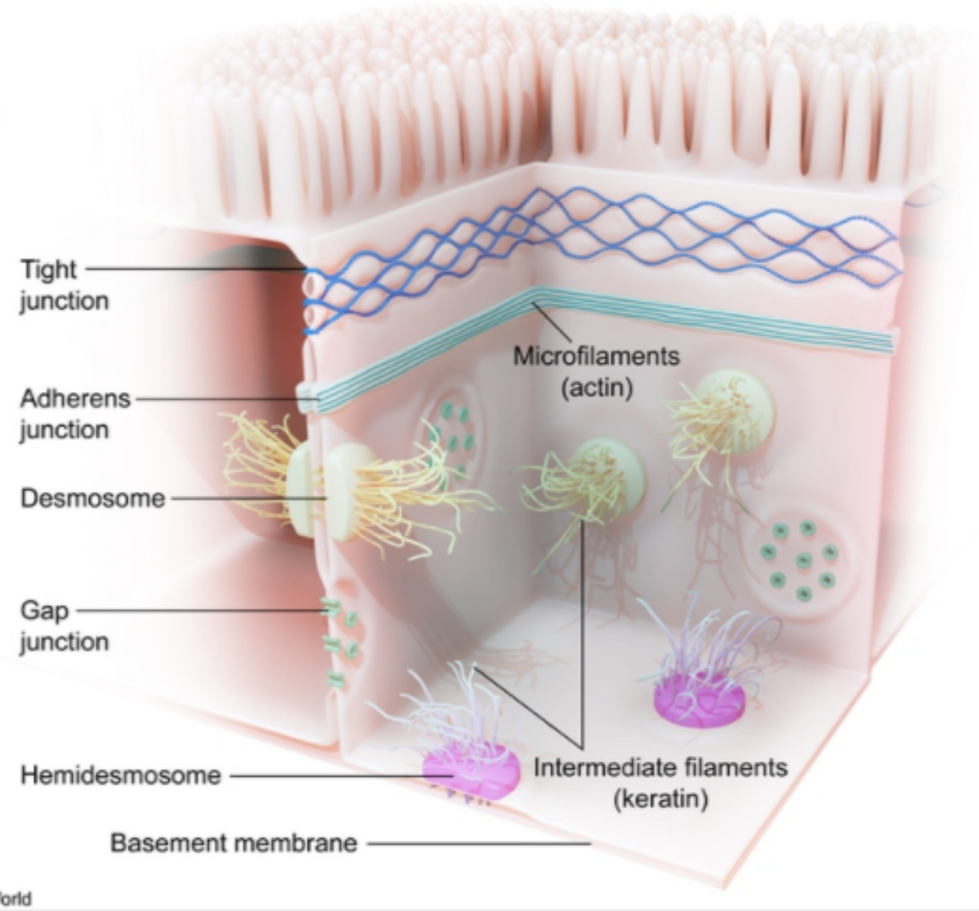

©UWorld

Zoom In | Zoom Out | Reset | Add To New Card | Existing Card

that assemble into gap junctions and their density increases in the uterus before delivery in response to rising estrogen levels.

Settings

1
2
3
4
5
6
7
8
9
10
11
12
13
14
15
16
17
18
19
20
21
22
23
24
25
26

Item 3 of 26
Question Id: 11888

Mark | Previous | Next | Full Screen | Tutorial | Lab Values | Notes | Calculator | Reverse Color | Text Zoom | Settings

©UWorld

Exhibit Display

Zoom In | Zoom Out | Reset | Add To New Card | Existing Card

that assemble into gap junctions and their density increases in the uterus before delivery in response to rising estrogen levels.

Block Time Remaining: 00:00:18
TUTOR

7 | Feedback | Suspend | End Block

Settings

1
2
3
4
5
6
7
8
9
10
11
12
13
14
15
16
17
18
19
20
21
22
23
24
25
26

Item 3 of 26
Question Id: 11888

Mark | Previous | Next | Full Screen | Tutorial | Lab Values | Notes | Calculator | Reverse Color | Text Zoom | Settings

Exhibit Display

Zoom In | Zoom Out | Reset | Add To New Card | Existing Card

Block Time Remaining: 00:00:18
TUTOR

7 | Feedback | Suspend | End Block

Settings

1
2
3
4
5
6
7
8
9
10
11
12
13
14
15
16
17
18
19
20
21
22
23
24
25
26

Item 3 of 26
Question Id: 11888

Mark | Previous | Next | Full Screen | Tutorial | Lab Values | Notes | Calculator | Reverse Color | Text Zoom | Settings

Exhibit Display

Zoom In | Zoom Out | Reset | Add To New Card | Existing Card

Block Time Remaining: 00:00:18
TUTOR

7 | Feedback | Suspend | End Block

An autopsy is being performed on a 72-year-old man with a history of myocardial infarction. Light microscopy of a portion of the left ventricle reveals the findings shown in the image below:

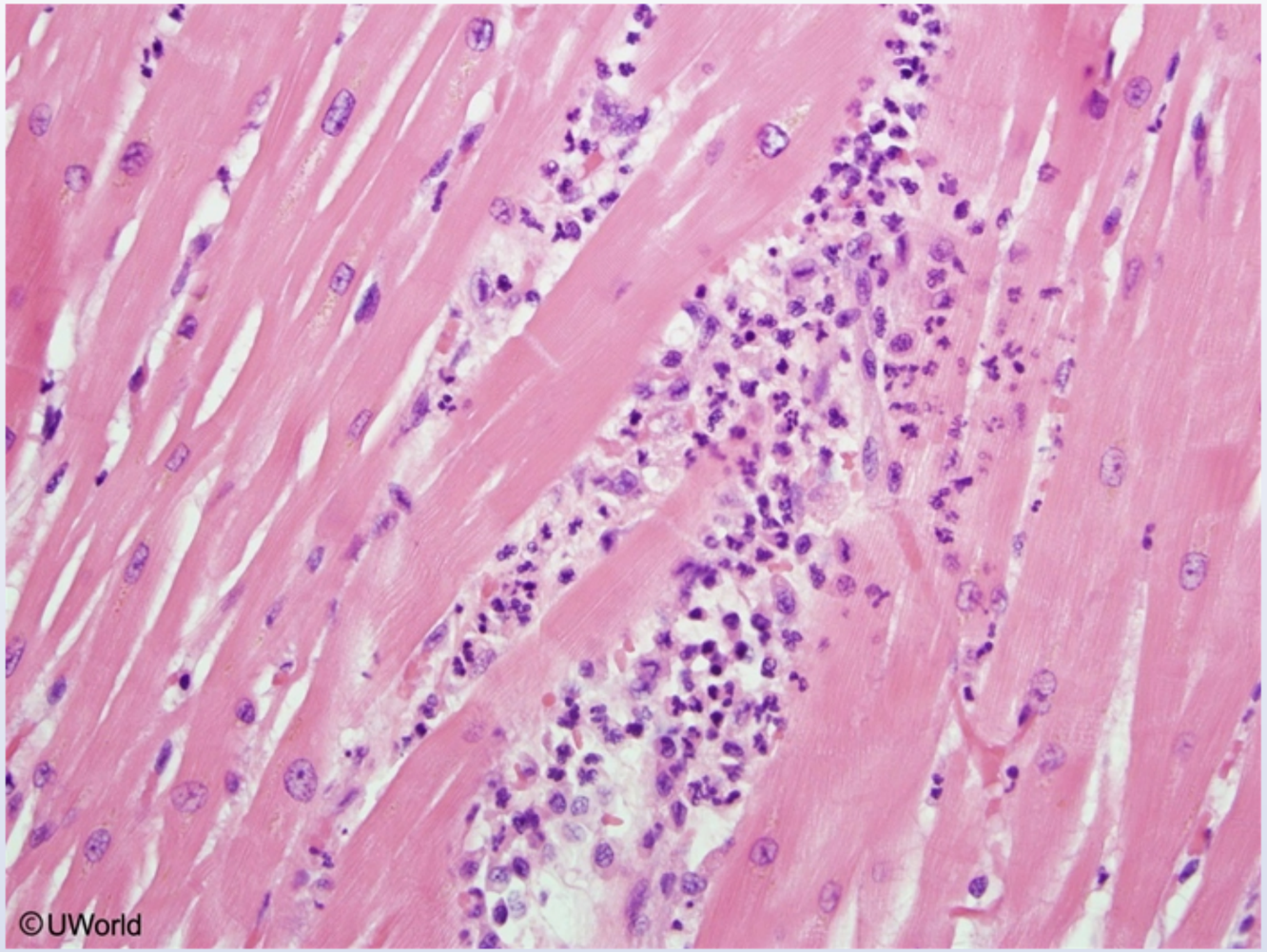

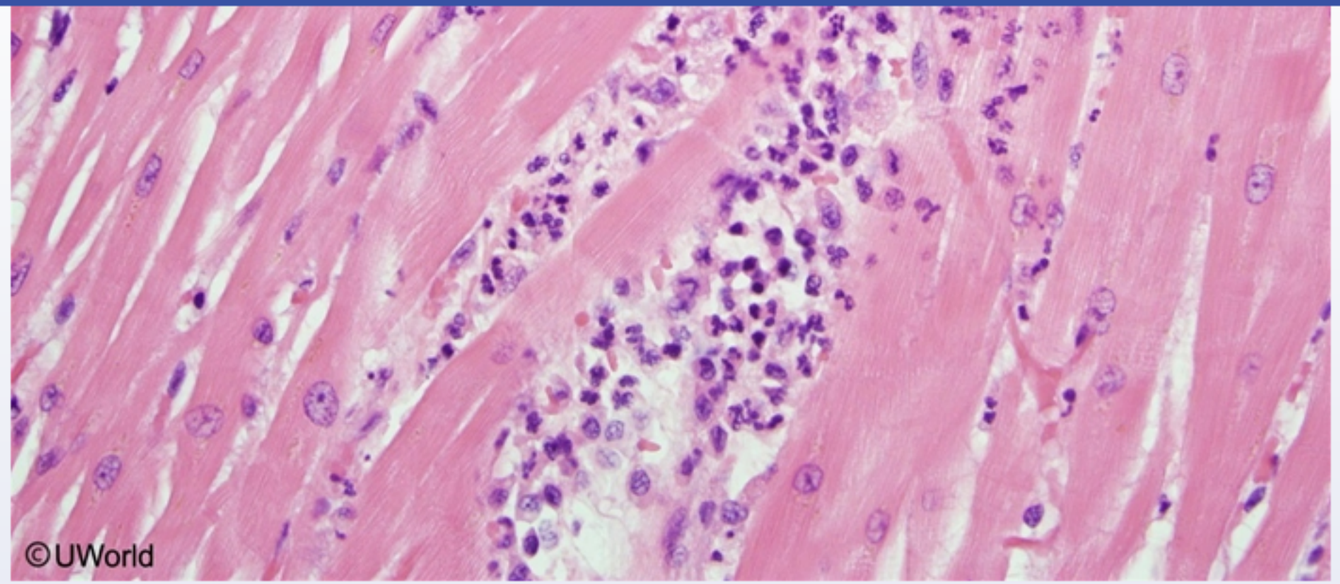

This patient most likely sustained the myocardial infarction during which of the following time frames prior to his death?

- A. Less than 4 hours
- B. 1 to 3 days
- C. 7 to 10 days
- D. 2 weeks to 2 months
- E. More than 2 months

Submit

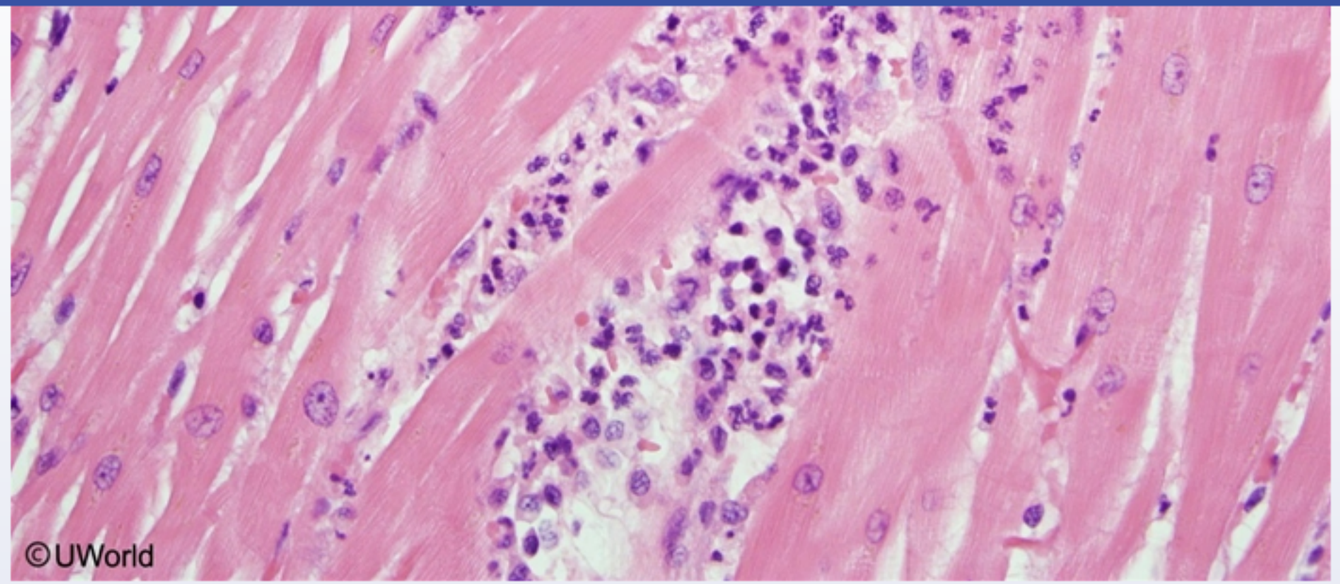

This patient most likely sustained the myocardial infarction during which of the following time frames prior to his death?

- A. Less than 4 hours (6%)
- ✓ B. 1 to 3 days (80%)
- C. 7 to 10 days (10%)
- D. 2 weeks to 2 months (1%)
- E. More than 2 months (1%)

Omitted
Correct answer

80%
Answered correctly

21 secs
Time Spent

05/09/2020
Last Updated

Time after myocardial infarction	Predominant light microscopic changes
0-4 hours	• No visible change
4-12 hours	• Wavy fibers with narrow, elongated myocytes
12-24 hours	• Myocyte hypereosinophilia with pyknotic (shrunken) nuclei
1-3 days	• Coagulation necrosis (loss of nuclei & striations) • Prominent neutrophilic infiltrate
3-7 days	• Disintegration of dead neutrophils & myofibers • Macrophage infiltration at border areas
7-10 days	• Robust phagocytosis of dead cells by macrophages • Beginning formation of granulation tissue at margins
10-14 days	• Well-developed granulation tissue with neovascularization
2 weeks-2 months	• Progressive collagen deposition & scar formation

Postmortem histopathology of this patient's myocardium reveals a dense neutrophilic infiltrate surrounded by relatively normal myocytes consistent with the morphologic changes expected in the border zone of ischemic injury **1-3 days after** myocardial infarction (MI). Myocardial cells are highly metabolically active and susceptible to **ischemic injury** after as little as 3-4 minutes of oxygen deprivation due to coronary artery blockage.

After irreversible myocardial injury, a series of characteristic **microscopic changes** occur over predictable time frames due to **coagulative necrosis** of myocardial fibers and infiltration of **inflammatory cells**, which play an essential role in the healing process:

- During the first 4 hours post-MI, no visible change occurs although cardiac-specific enzymes can be detected in the patient's bloodstream **(Choice A)**.
- From 4 to 24 hours post-MI, changes due to digestion of cytoplasmic organelles, denaturation of proteins, and loss of RNA become visible (eg, wavy, hypereosinophilic myocytes with shrunken nuclei), especially in the central portion of the infarct.

2 weeks-2 months	• Progressive collagen deposition & scar formation

Postmortem histopathology of this patient's myocardium reveals a dense neutrophilic infiltrate surrounded by relatively normal myocytes consistent with the morphologic changes expected in the border zone of ischemic injury **1-3 days after** myocardial infarction (MI). Myocardial cells are highly metabolically active and susceptible to **ischemic injury** after as little as 3-4 minutes of oxygen deprivation due to coronary artery blockage.

After irreversible myocardial injury, a series of characteristic **microscopic changes** occur over predictable time frames due to **coagulative necrosis** of myocardial fibers and infiltration of **inflammatory cells**, which play an essential role in the healing process:

- During the first 4 hours post-MI, no visible change occurs although cardiac-specific enzymes can be detected in the patient's bloodstream **(Choice A)**.
- From 4 to 24 hours post-MI, changes due to digestion of cytoplasmic organelles, denaturation of proteins, and loss of RNA become visible (eg, wavy, hypereosinophilic myocytes with shrunken nuclei), especially in the central portion of the infarct.
- From **1 to 3 days** post-MI, **neutrophils infiltrate** the **border zone** of the injured tissue in response to proinflammatory cytokines (eg, IL-6, IL-8), eventually migrating to the central portion of the infarct. These neutrophils phagocytize dead myocytes and release **lysosomal enzymes**, reactive oxygen species, and **cytokines** (eg, IL-1, TNF-α) that can prevent infiltration by pathogens and facilitate wound healing.
- From 3 to 10 days post-MI, macrophages infiltrate and phagocytize dead myocytes and neutrophils while initiating the formation of granulation tissue by producing cytokines (eg, IL-10) and growth factors (TGF-β) **(Choice C)**.
- From 10 to 14 days post-MI, prominent fibroblast proliferation, collagen deposition, and neovascularization of granulation tissue are present.
- From 2 weeks to 2 months post-MI, collagen remodeling and fibroblast differentiation into myofibroblasts drive the formation of scar tissue **(Choice D)**.
- After 2 months post-MI, remodeling continues to a slower rate as the scar matures and contracts **(Choice E)**.

Educational objective:
Irreversible myocardial ischemic injury initiates a series of predictable morphologic changes over the hours to weeks after the initial injury. From 1 and 3 days after the initial injury, neutrophils infiltrate the border zone of the injured tissue (where myocytes are relatively normal) in response to proinflammatory cytokines (eg, IL-6, IL-8), eventually migrating to the central portion of the infarct.

necrosis of myocardial fibers and infiltration of **inflammatory cells**, which play an essential role in the healing process:

- During the first 4 hours post-MI, no visible change occurs although cardiac-specific enzymes can be detected in the patient's bloodstream **(Choice A)**.
- From 4 to 24 hours post-MI, changes due to digestion of cytoplasmic organelles, denaturation of proteins, and loss of RNA become visible (eg, wavy, hypereosinophilic myocytes with shrunken nuclei), especially in the central portion of the infarct.
- From **1 to 3 days** post-MI, **neutrophils infiltrate** the **border zone** of the injured tissue in response to proinflammatory cytokines (eg, IL-6, IL-8), eventually migrating to the central portion of the infarct. These neutrophils phagocytize dead myocytes and release **lysosomal enzymes**, reactive oxygen species, and **cytokines** (eg, IL-1, TNF-α) that can prevent infiltration by pathogens and facilitate wound healing.
- From 3 to 10 days post-MI, macrophages infiltrate and phagocytize dead myocytes and neutrophils while initiating the formation of granulation tissue by producing cytokines (eg, IL-10) and growth factors (TGF-β) **(Choice C)**.
- From 10 to 14 days post-MI, prominent fibroblast proliferation, collagen deposition, and neovascularization of granulation tissue are present.
- From 2 weeks to 2 months post-MI, collagen remodeling and fibroblast differentiation into myofibroblasts drive the formation of scar tissue **(Choice D)**.
- After 2 months post-MI, remodeling continues to a slower rate as the scar matures and contracts **(Choice E)**.

Educational objective:
Irreversible myocardial ischemic injury initiates a series of predictable morphologic changes over the hours to weeks after the initial injury. From 1 and 3 days after the initial injury, neutrophils infiltrate the border zone of the injured tissue (where myocytes are relatively normal) in response to proinflammatory cytokines (eg, IL-6, IL-8), eventually migrating to the central portion of the infarct.

Histology	Cardiovascular System	Myocardial infarction
Subject	System	Topic

Copyright © UWorld. All rights reserved.

Time after myocardial infarction	Predominant light microscopic changes

Exhibit Display

Acute myocardial infarction

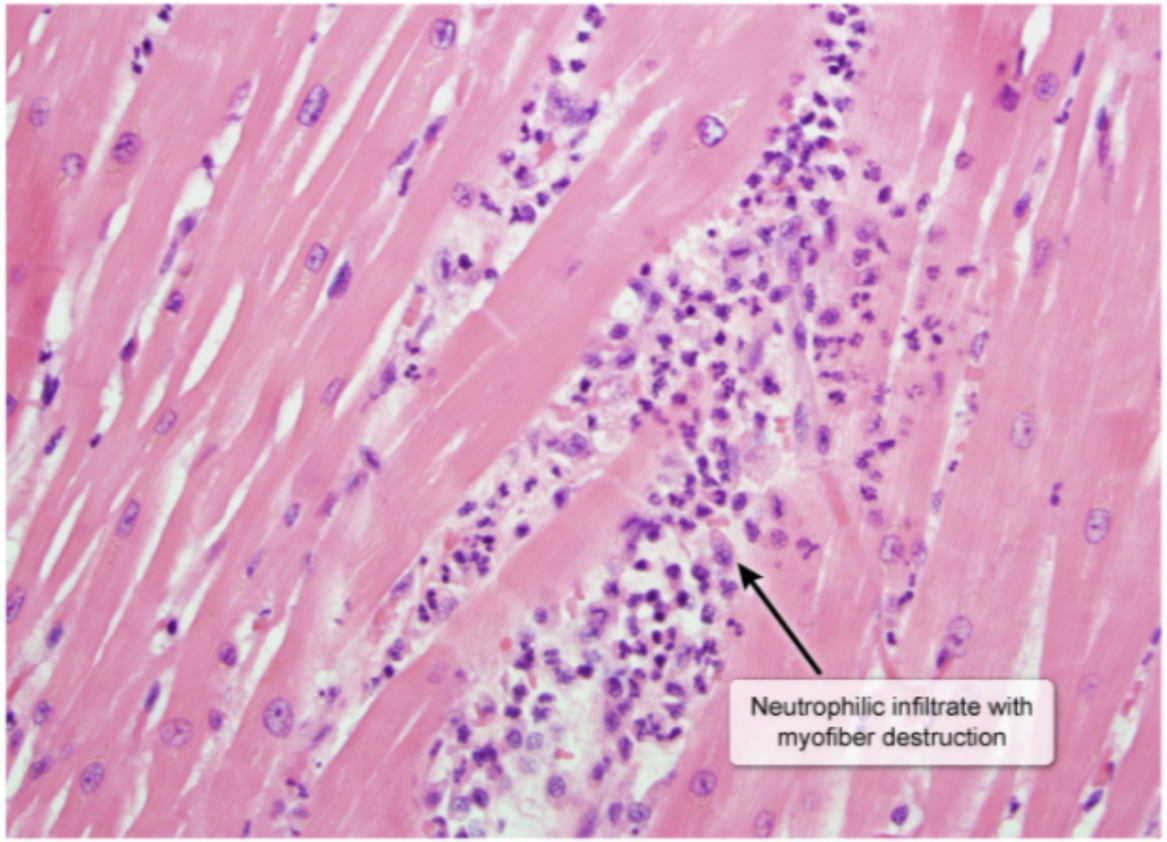

©UWorld

Zoom In | Zoom Out | Reset | Add To Flash Card

(eg, wavy, hypereosinophilic myocytes with shrunken nuclei), especially in the central portion of the infarct.

necrosis of myocardial fibers and infiltration of **inflammatory cells**, which play an essential role in the healing process:

Exhibit Display

Resolved myocardial infarcts

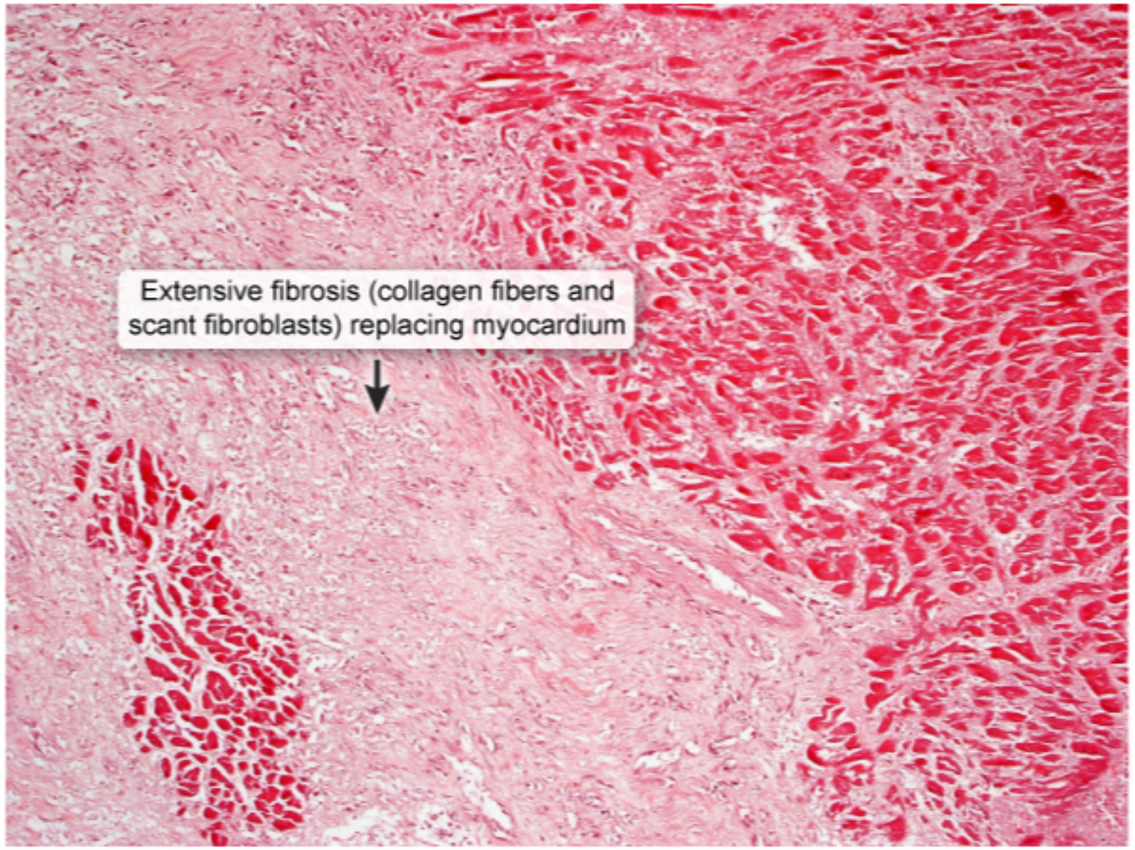

©UWorld

Zoom In Zoom Out Reset Add To Flash Card

Molecular biologists are investigating the functional significance of non-coding RNA molecules. During an experiment, they isolate large complexes containing both protein and RNA from exocrine pancreatic cells. The complexes are found both freely floating in the cytoplasm and bound to the endoplasmic reticulum. The RNA found within these complexes is primarily synthesized at which of the following intracellular sites?

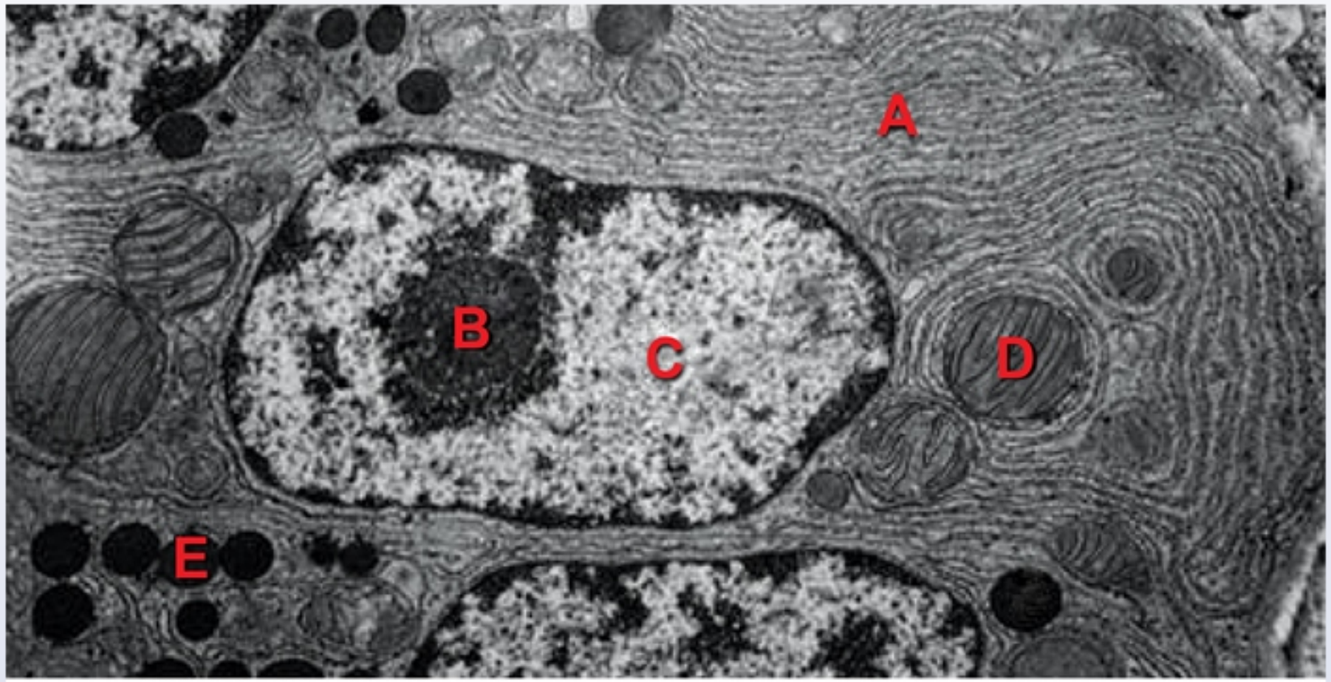

©UWorld

A. A

B. B

C. C

D. D

Settings

1
2
3
4
5
6
7
8
9
10
11
12
13
14
15
16
17
18
19
20
21
22
23
24
25
26

Item 5 of 26
Question Id: 1417

Mark | Previous | Next | Full Screen | Tutorial | Lab Values | Notes | Calculator | Reverse Color | Text Zoom | Settings

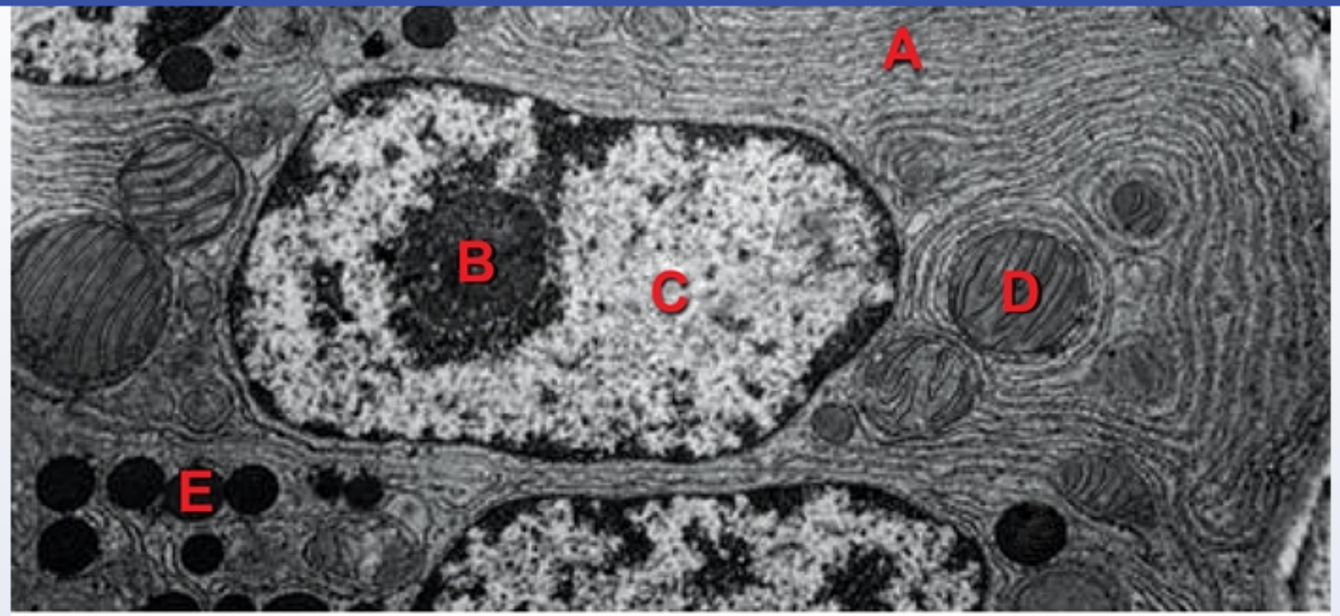

©UWorld

A. A

B. B

C. C

D. D

E. E

Submit

Block Time Remaining: 00:00:43
TUTOR

Feedback | Suspend | End Block

Settings

1 2 3 4 5 6 7 8 9 10 11 12 13 14 15 16 17 18 19 20 21 22 23 24 25 26

Item 5 of 26
Question Id: 1417

Mark | Previous | Next | Full Screen | Tutorial | Lab Values | Notes | Calculator | Reverse Color | Text Zoom | Settings

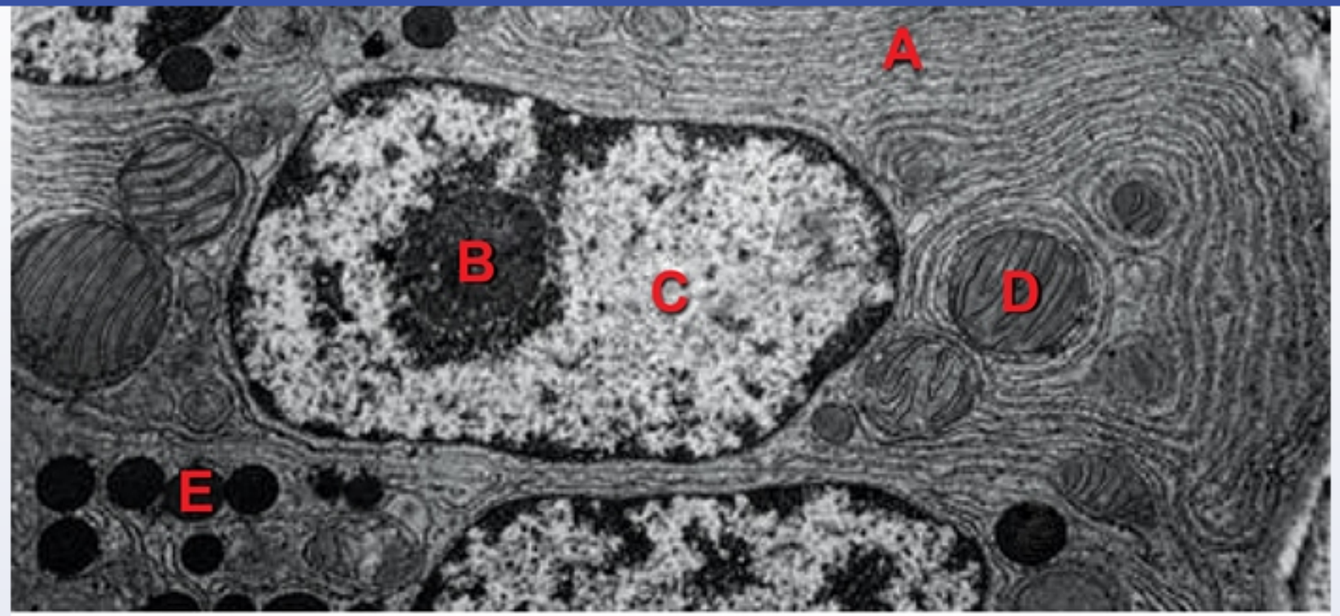

©UWorld

A. A (10%)
✓ B. B (53%)
C. C (22%)
D. D (10%)
E. E (3%)

Omitted
Correct answer

53%
Answered correctly

08 secs
Time Spent

04/12/2020
Last Updated

Block Time Remaining: 00:00:47
TUTOR

Feedback | Suspend | End Block

Explanation

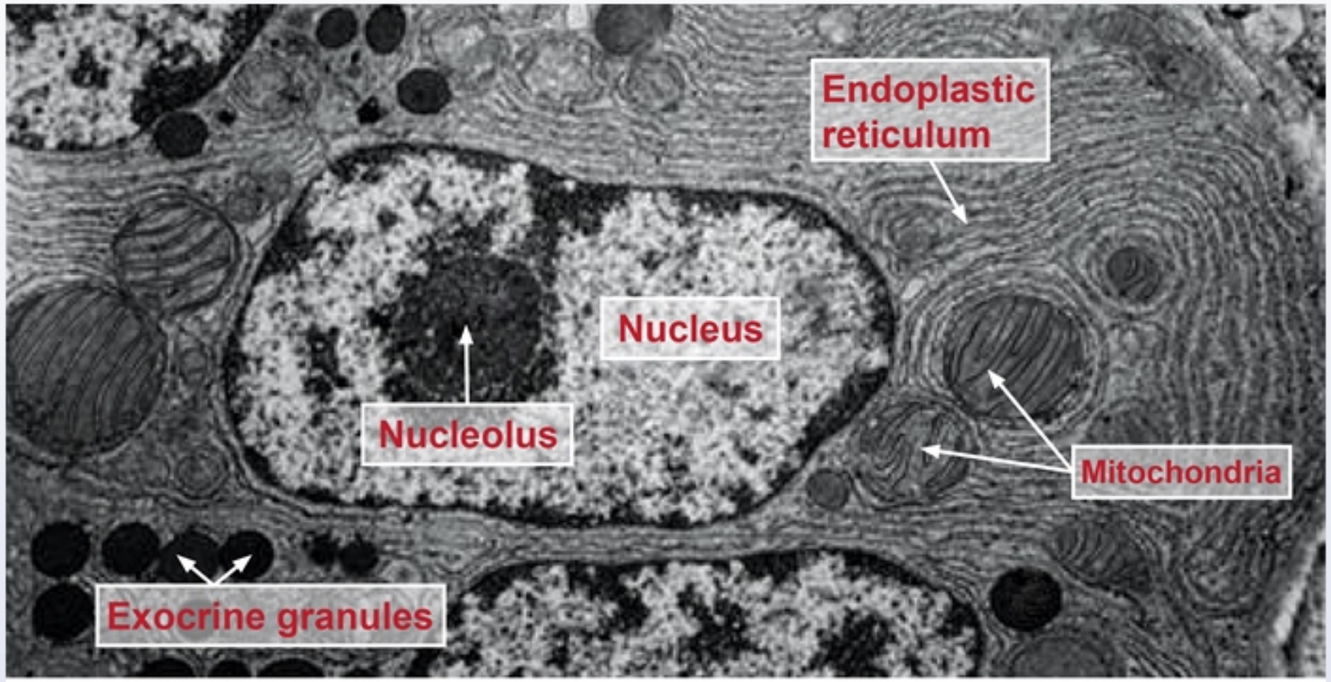

©UWorld

The large complexes containing both protein and RNA that are found freely floating and bound to the endoplasmic reticulum are most likely **ribosomes**. Ribosome biogenesis occurs primarily within the **nucleolus**, a dense **round structure** inside the nucleus that is in direct contact with the rest of the nucleoplasm. The nucleolus contains ribosomal DNA coding for the 28S, 5.8S, and 18S ribosomal RNA (rRNA) components, and it is here where most of the **rRNA is transcribed**. After synthesis, rRNA is combined with ribosomal protein components that are translated in the cytoplasm and then imported into the nucleus. The immature 60S and 40S ribosomal subunits are then exported from the nucleus to fully mature in the cytoplasm.

(Choice A) The rough endoplasmic reticulum is identifiable due to its characteristic long, folded membranes that are coated with ribosomes, giving it a speckled or rough appearance.

©UWorld

The large complexes containing both protein and RNA that are found freely floating and bound to the endoplasmic reticulum are most likely **ribosomes**. Ribosome biogenesis occurs primarily within the **nucleolus**, a dense **round structure** inside the nucleus that is in direct contact with the rest of the nucleoplasm. The nucleolus contains ribosomal DNA coding for the 28S, 5.8S, and 18S ribosomal RNA (rRNA) components, and it is here where most of the **rRNA is transcribed**. After synthesis, rRNA is combined with ribosomal protein components that are translated in the cytoplasm and then imported into the nucleus. The immature 60S and 40S ribosomal subunits are then exported from the nucleus to fully mature in the cytoplasm.

(Choice A) The rough endoplasmic reticulum is identifiable due to its characteristic long, folded membranes that are coated with ribosomes, giving it a speckled or rough appearance.

(Choice C) The nucleus is identifiable as a membrane-bound structure that contains the nucleolus, electron-lucent euchromatin, and electron-dense heterochromatin (condensed DNA typically found around the periphery). However, most of the ribosomal DNA is found in the form of tandem repeats within the nucleolus; only the 5S rRNA is transcribed outside of the nucleolus.

(Choice D) Mitochondria are organelles with dual phospholipid bilayer membranes that can be recognized by the presence of foldings (ie, cristae) in their inner membranes. Mitochondria have their own ribosomes, but they are typically found within the mitochondrial matrix or bound to the inner mitochondrial membrane.

(Choice E) Pancreatic zymogen granules are electron-dense structures containing digestive proenzymes that are released from the cell via exocytosis.

Educational objective:
The nucleolus is a dense intranuclear body visible by light and electron microscopy that functions as the primary site of ribosome synthesis and assembly. All ribosomal RNA except 5S rRNA is transcribed in the nucleolus.

Histology	General Principles	Rna structure & function
Subject	System	Topic

Copyright © UWorld. All rights reserved.

A 42-year-old woman, gravida 4, para 4, comes to the clinic due to heavy and painful menstrual bleeding over the past 3 months. Her last menstrual period was 4 weeks ago. Menarche was at age 10, and menstrual periods last for 3-5 days and occur every 30 days. She is sexually active with her husband and does not have pain with intercourse. The patient had a bilateral tubal ligation 3 years ago after the birth of her last child. She takes no medications and has no allergies. BMI is 24 kg/m^2. Vital signs are normal. On bimanual examination, the uterus is uniformly enlarged. Urine β-hCG is negative. Biopsy shows secretory endometrium. Which of the following is the most likely cause of this patient's symptoms?

A. Benign myometrial smooth muscle cell proliferation

B. Blastocyst implantation in the fallopian tube

C. Deficiency of von Willebrand factor

D. Endometrial tissue in the myometrium

E. Greater increase in endometrial gland proliferation compared to stroma

F. Hyperplastic growth of tissue from endometrial surface

Submit

A 42-year-old woman, gravida 4, para 4, comes to the clinic due to heavy and painful menstrual bleeding over the past 3 months. Her last menstrual period was 4 weeks ago. Menarche was at age 10, and menstrual periods last for 3-5 days and occur every 30 days. She is sexually active with her husband and does not have pain with intercourse. The patient had a bilateral tubal ligation 3 years ago after the birth of her last child. She takes no medications and has no allergies. BMI is 24 kg/m^2. Vital signs are normal. On bimanual examination, the uterus is uniformly enlarged. Urine β-hCG is negative. Biopsy shows secretory endometrium. Which of the following is the most likely cause of this patient's symptoms?

- A. Benign myometrial smooth muscle cell proliferation (12%)
- B. Blastocyst implantation in the fallopian tube (2%)
- C. Deficiency of von Willebrand factor (0%)
- ✓ D. Endometrial tissue in the myometrium (43%)
- E. Greater increase in endometrial gland proliferation compared to stroma (18%)
- F. Hyperplastic growth of tissue from endometrial surface (23%)

Omitted
Correct answer
D

43%
Answered correctly

02 secs
Time Spent

04/25/2020
Last Updated

Explanation

Normal uterus vs adenomyosis

Settings

1
2
3
4
5
6
7
8
9
10
11
12
13
14
15
16
17
18
19
20
21
22
23
24
25
26

Item 6 of 26
Question Id: 1957

Mark

Previous | Next | Full Screen | Tutorial | Lab Values | Notes | Calculator | Reverse Color | Text Zoom | Settings

Normal uterus vs adenomyosis

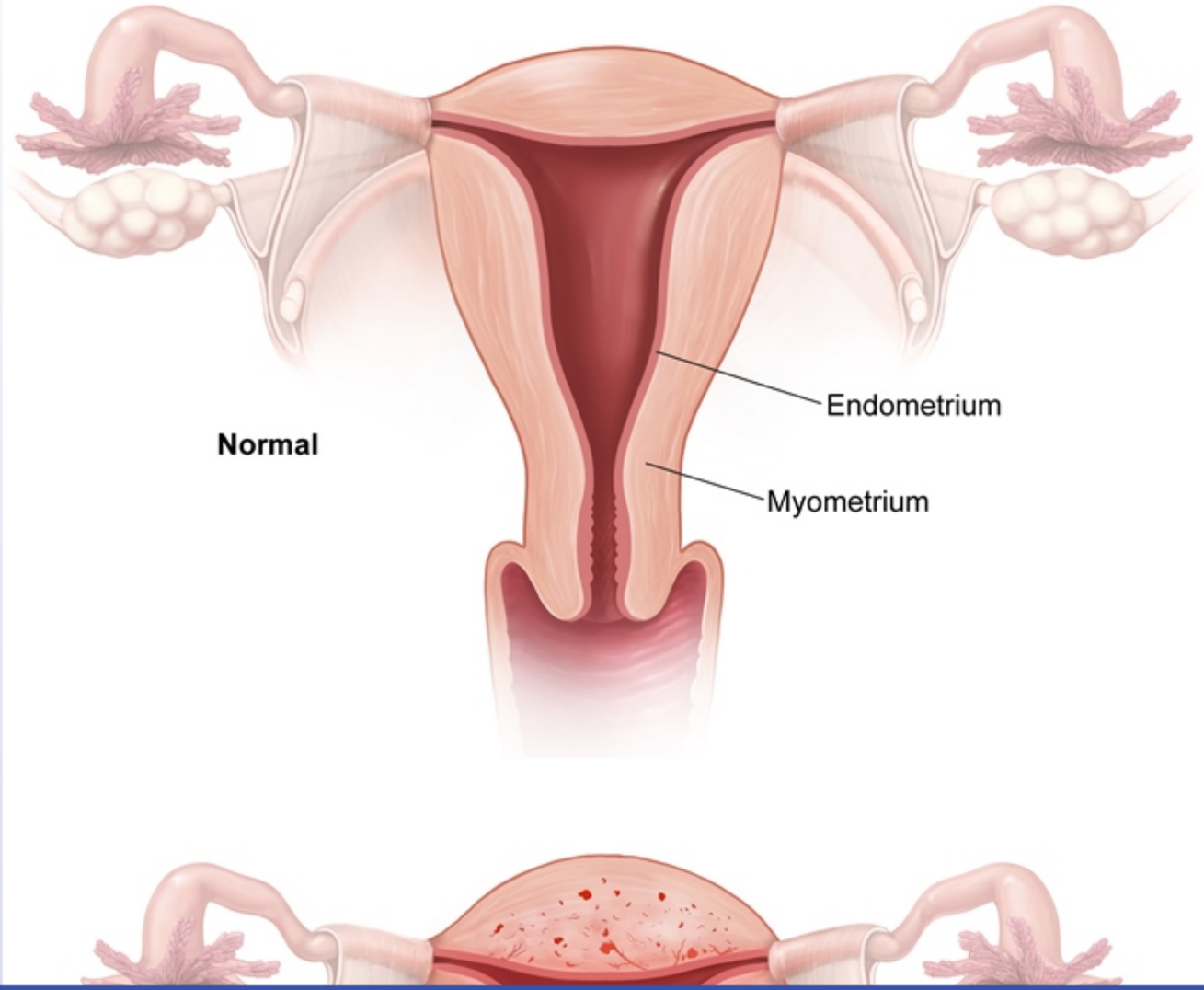

Block Time Remaining: 00:00:49
TUTOR

4 | Feedback | Suspend | End Block

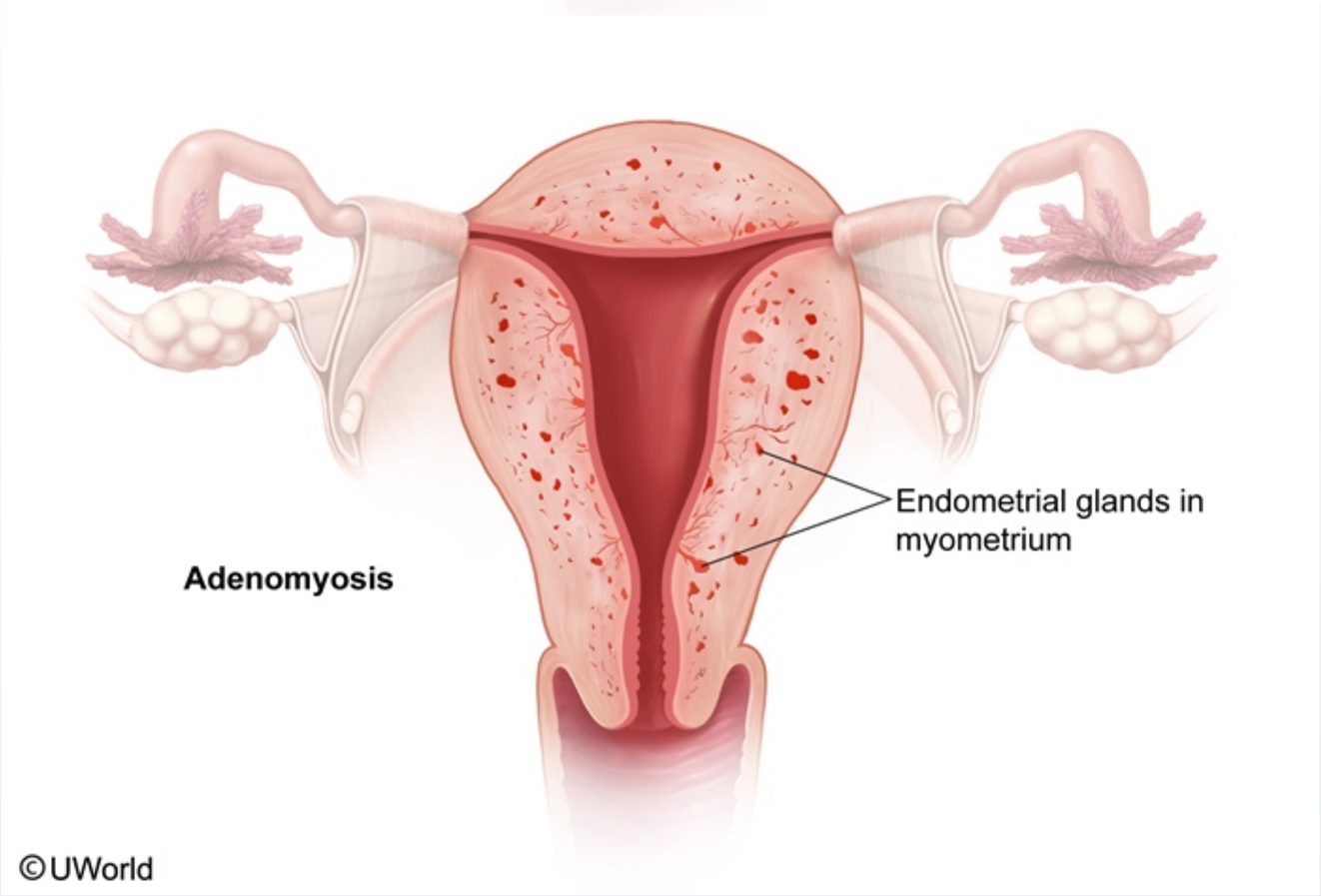

Adenomyosis is the presence of **endometrial glandular tissue** within the **myometrium**. The condition is relatively common in middle-aged parous females. Symptoms include **heavy menstrual bleeding**, which is due to an increased endometrial surface, and **dysmenorrhea**, which results from endometrial tissue growth in the confined myometrial space. Physical examination classically shows a **uniformly enlarged uterus** (as seen in this patient). Uterine enlargement results from hormonal stimulation of endometrial glandular tissue in the myometrium. An endometrial biopsy is a sample of the tissue in the endometrial lining, and therefore, this patient's biopsy result of secretory endometrium is a normal finding for a woman in day 21 of her menstrual cycle. Adenomyosis can only be diagnosed definitively by microscopic examination of a

Adenomyosis is the presence of **endometrial glandular tissue** within the **myometrium**. The condition is relatively common in middle-aged parous females. Symptoms include **heavy menstrual bleeding**, which is due to an increased endometrial surface, and **dysmenorrhea**, which results from endometrial tissue growth in the confined myometrial space. Physical examination classically shows a **uniformly enlarged uterus** (as seen in this patient). Uterine enlargement results from hormonal stimulation of endometrial glandular tissue in the myometrium. An endometrial biopsy is a sample of the tissue in the endometrial lining, and therefore, this patient's biopsy result of secretory endometrium is a normal finding for a woman in day 21 of her menstrual cycle. Adenomyosis can only be diagnosed definitively by microscopic examination of a hysterectomy specimen.

(Choice A) Leiomyomas (also known as fibroids) are caused by proliferation of myometrial smooth muscle cells. Fibroids may cause heavy menstrual bleeding, but the uterus is usually irregularly enlarged.

(Choice B) The fallopian tube is the most common location for an ectopic pregnancy. Patients with extrauterine blastocyst implantation typically have amenorrhea with or without acute lower abdominal pain and a positive urine pregnancy test.

(Choice C) Von Willebrand disease is a commonly inherited coagulopathy. A deficiency or dysfunction in von Willebrand factor causes ineffective hemostasis, resulting in long-standing, heavy menstrual and peripartum bleeding. This patient's heavy menstrual bleeding started recently, and she delivered 4 children without bleeding complications.

(Choice E) Endometrial hyperplasia is characterized by a greater increase in endometrial gland proliferation as compared to stroma. It often presents with irregular, but not painful, menstrual bleeding.

(Choice F) Endometrial polyps are a common cause of abnormal uterine bleeding. They are usually benign projections from the uterine lining resulting from hyperplastic growth of endometrial glands and stroma. They do not cause uterine enlargement.

Educational objective:
Adenomyosis is the presence of endometrial glandular tissue within the myometrium. Menorrhagia and dysmenorrhea are common presenting symptoms. Patients have a uniformly enlarged uterus with normal-appearing endometrial tissue on biopsy.

References

- Evaluation and management of abnormal uterine bleeding in premenopausal women.

Settings

1
2
3
4
5
6
7
8
9
10
11
12
13
14
15
16
17
18
19
20
21
22
23
24
25
26

Item 6 of 26
Question Id: 1957

Mark | Previous | Next | Full Screen | Tutorial | Lab Values | Notes | Calculator | Reverse Color | Text Zoom | Settings

Adenomyosis is the presence of **endometrial glandular tissue** within the **myometrium**. The condition is relatively common in middle-aged

Exhibit Display

Zoom In | Zoom Out | Reset | Add To New Card | Existing Card

Block Time Remaining: 00:00:49
TUTOR

4 | Feedback | Suspend | End Block

Adenomyosis is the presence of **endometrial glandular tissue** within the **myometrium**. The condition is relatively common in middle-aged

Exhibit Display

Uterine fibroids

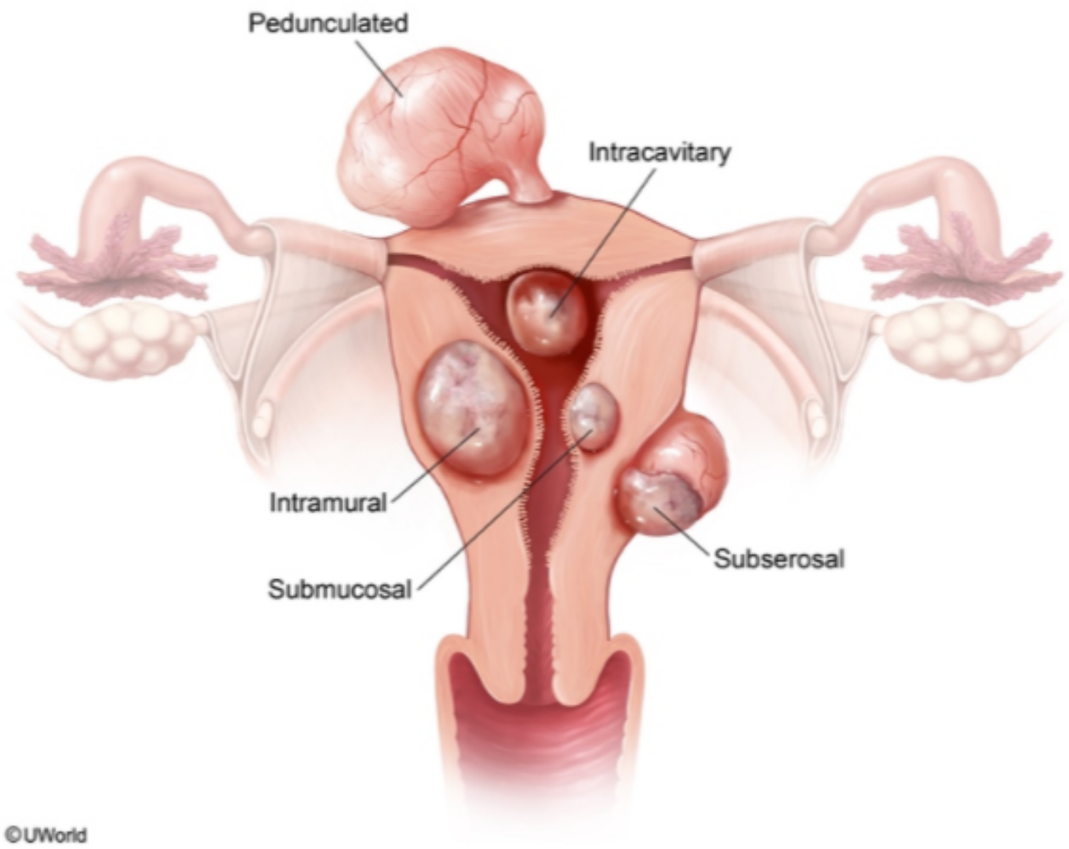

Zoom In | Zoom Out | Reset | Add To New Card | Existing Card

Settings

1
2
3
4
5
6
7
8
9
10
11
12
13
14
15
16
17
18
19
20
21
22
23
24
25
26

Item 6 of 26
Question Id: 1957

Mark | Previous | Next | Full Screen | Tutorial | Lab Values | Notes | Calculator | Reverse Color | Text Zoom | Settings

Adenomyosis is the presence of **endometrial glandular tissue** within the **myometrium**. The condition is relatively common in middle-aged

Exhibit Display

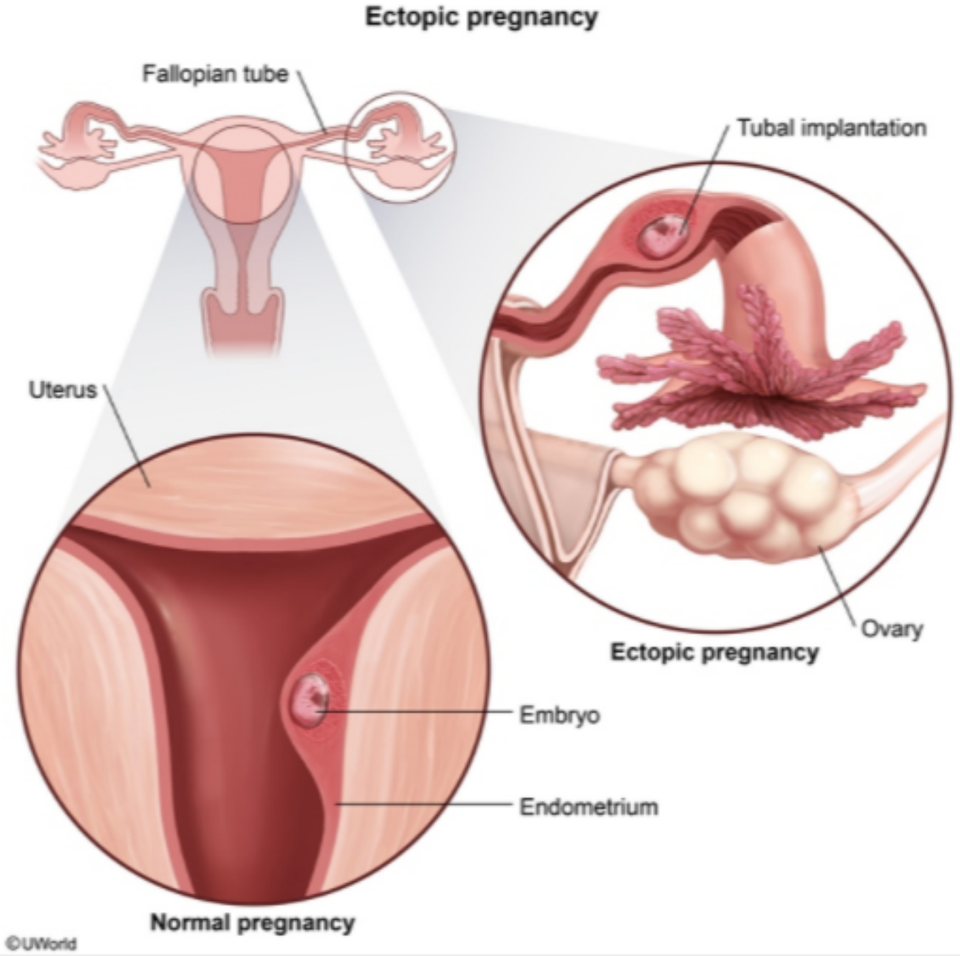

Zoom In | Zoom Out | Reset | Add To New Card | Existing Card

Block Time Remaining: 00:00:49
TUTOR

4 | Feedback | Suspend | End Block

A 35-year-old woman, gravida 1, para 0, at 12 weeks gestation comes to the office for evaluation of genital warts. She first noticed the warts last week and is concerned that it has persisted. The patient has occasional mild pruritus but no pain. She is currently sexually active with her boyfriend and engages in oral and vaginal intercourse. Examination shows several verrucous, skin-colored lesions over the labia majora. The patient asks whether the lesion could affect her future child. The virus involved in this patient's condition also has an affinity to infect which of the following structures?

A. Alveoli

B. False vocal cords

C. Paranasal sinuses

D. Trachea

E. True vocal cords

Submit

A 35-year-old woman, gravida 1, para 0, at 12 weeks gestation comes to the office for evaluation of genital warts. She first noticed the warts last week and is concerned that it has persisted. The patient has occasional mild pruritus but no pain. She is currently sexually active with her boyfriend and engages in oral and vaginal intercourse. Examination shows several verrucous, skin-colored lesions over the labia majora. The patient asks whether the lesion could affect her future child. The virus involved in this patient's condition also has an affinity to infect which of the following structures?

- A. Alveoli (4%)
- B. False vocal cords (25%)
- C. Paranasal sinuses (16%)
- D. Trachea (9%)
- ✓ E. True vocal cords (44%)

Omitted
Correct answer
E

44%
Answered correctly

02 secs
Time Spent

02/20/2020
Last Updated

Explanation

Respiratory epithelium		
Type	Location	Function

Explanation

Respiratory epithelium		
Type	**Location**	**Function**
Ciliated, pseudostratified, columnar	Nasal cavity, upper pharynx, false vocal cords, trachea, bronchi	• Mucus-secreting cells moisten air & trap debris/pathogens • Ciliary beating sweeps debris toward pharynx for swallowing
Squamous stratified	True vocal cords	Protects from abrasion & chemical attack
Cuboidal	Bronchioles	Conduct air to alveoli
Simple squamous	Alveoli	Gas exchange

©UWorld

This patient's verrucous, skin-colored genital lesion is most consistent with condylomata acuminatum, also known as anogenital warts. Condylomata acuminatum is caused by **human papillomavirus (HPV)**, a small **double-stranded DNA virus** with >100 subtypes. HPV is the most common sexually transmitted disease and can be transmitted by vaginal, anal, and oral intercourse. Most infections are cleared by host immunity, but **types 6** and **11** can result in warts.

HPV infects basal epithelial cells through small breaks in the skin or mucosal surfaces. It has a predilection for **stratified squamous epithelium**, which is found in the anal canal, vagina, and cervix. In the respiratory tract, the **true vocal cords** are the only area covered with stratified

This patient's verrucous, skin-colored genital lesion is most consistent with condylomata acuminatum, also known as anogenital warts. Condylomata acuminatum is caused by **human papillomavirus (HPV)**, a small **double-stranded DNA virus** with >100 subtypes. HPV is the most common sexually transmitted disease and can be transmitted by vaginal, anal, and oral intercourse. Most infections are cleared by host immunity, but **types 6** and **11** can result in warts.

HPV infects basal epithelial cells through small breaks in the skin or mucosal surfaces. It has a predilection for **stratified squamous epithelium**, which is found in the anal canal, vagina, and cervix. In the respiratory tract, the **true vocal cords** are the only area covered with stratified squamous epithelium. The vocal cords undergo near-constant friction and abrasion to produce speech. Stratified squamous epithelium is protective, as deeper cells can replace surface cells that are damaged.

Infants can acquire respiratory papillomatosis via passage through the birth canal of mothers infected with the virus. Warty growths on the true vocal cords can lead to a weak cry, hoarseness, and stridor.

(Choice A) The alveoli are comprised of simple squamous epithelium. This thin and flat epithelium facilitates rapid transmembrane exchange of oxygen and carbon dioxide.

(Choice B) The false vocal cords, also known as ventricular folds, are folds of mucous membrane lined in respiratory epithelium, which is ciliated, pseudostratified, columnar, and mucus-secreting. The false vocal cords are adjacent to the true vocal cords and help to lubricate the true vocal cords with mucus and protect the airway from foreign bodies.

(Choices C and D) The paranasal sinuses and trachea also are lined in respiratory epithelium. This ciliated, pseudostratified, columnar, and mucus-secreting epithelium protects the respiratory tract from debris and pathogens. Goblet cells secrete mucus to trap particulate matter, and the cilia beat in a rhythmic fashion to propel this mucus/debris toward the oral cavity, where it can be swallowed or coughed up.

Educational objective:
Human papilloma virus (HPV) is a small DNA virus with a tropism for stratified squamous epithelium, which protectively lines anatomical areas that undergo frequent friction and abrasion, including the true vocal cords, cervix, and anus. Infants can acquire respiratory papillomatosis via passage through an HPV-infected birth canal.

References

- Epithelial Cell Responses to Infection with Human Papillomavirus

Infants can acquire respiratory papillomatosis via passage through the birth canal of mothers infected with the virus. Warty growths on the true vocal cords can lead to a weak cry, hoarseness, and stridor.

(Choice A) The alveoli are comprised of simple squamous epithelium. This thin and flat epithelium facilitates rapid transmembrane exchange of oxygen and carbon dioxide.

(Choice B) The false vocal cords, also known as ventricular folds, are folds of mucous membrane lined in respiratory epithelium, which is ciliated, pseudostratified, columnar, and mucus-secreting. The false vocal cords are adjacent to the true vocal cords and help to lubricate the true vocal cords with mucus and protect the airway from foreign bodies.

(Choices C and D) The paranasal sinuses and trachea also are lined in respiratory epithelium. This ciliated, pseudostratified, columnar, and mucus-secreting epithelium protects the respiratory tract from debris and pathogens. Goblet cells secrete mucus to trap particulate matter, and the cilia beat in a rhythmic fashion to propel this mucus/debris toward the oral cavity, where it can be swallowed or coughed up.

Educational objective:
Human papilloma virus (HPV) is a small DNA virus with a tropism for stratified squamous epithelium, which protectively lines anatomical areas that undergo frequent friction and abrasion, including the true vocal cords, cervix, and anus. Infants can acquire respiratory papillomatosis via passage through an HPV-infected birth canal.

References

- Epithelial Cell Responses to Infection with Human Papillomavirus
- Prevalence of human papillomavirus (HPV) in upper respiratory tract mucosa in a group of pre-school children.
- Genital warts: a comprehensive review

Histology	Infectious Diseases	Human papilloma virus
Subject	System	Topic

Copyright © UWorld. All rights reserved.

An 8-year-old boy is brought to the office due to acute facial puffiness. His mother reports that for the preceding 24 hours he has been easily fatigued and has had dark urine. The patient was treated for a skin infection 3 weeks ago but has no chronic medical conditions. Temperature is 36.1 C (97 F) and blood pressure is 140/94 mm Hg. Physical examination shows periorbital edema and mild pitting edema along the ankles. The remainder of the examination shows no abnormalities. A representative renal biopsy sample is shown in the below image.

The fluorescent areas on the slide most likely indicate the presence of which of the following substances?

- A. Albumin
- B. C1q
- C. C3
- D. Fibrin
- E. IgE
- F. M protein

Submit

An 8-year-old boy is brought to the office due to acute facial puffiness. His mother reports that for the preceding 24 hours he has been easily fatigued and has had dark urine. The patient was treated for a skin infection 3 weeks ago but has no chronic medical conditions. Temperature is 36.1 C (97 F) and blood pressure is 140/94 mm Hg. Physical examination shows periorbital edema and mild pitting edema along the ankles. The remainder of the examination shows no abnormalities. A representative renal biopsy sample is shown in the below image.

The fluorescent areas on the slide most likely indicate the presence of which of the following substances?

- A. Albumin (1%)
- B. C1q (3%)
- ✓ C. C3 (74%)
- D. Fibrin (1%)
- E. IgE (5%)
- F. M protein (12%)

Omitted
Correct answer
C

74%
Answered correctly

21 secs
Time Spent

02/08/2020
Last Updated

Explanation

This pediatric patient with nephritic syndrome (eg, periorbital edema, hematuria, hypertension) following a recent skin infection most likely has **poststreptococcal glomerulonephritis** (PSGN). PSGN is the most common cause of nephritic syndrome in children and typically occurs 2-4

This pediatric patient with nephritic syndrome (eg, periorbital edema, hematuria, hypertension) following a recent skin infection most likely has **poststreptococcal glomerulonephritis** (PSGN). PSGN is the most common cause of nephritic syndrome in children and typically occurs 2-4 weeks after exposure to group A beta-hemolytic *Streptococcus* (eg, pharyngitis, skin infection). Antigens expressed on nephritogenic streptococcal species combine with antibodies to form immune complexes, which are deposited on the glomerular basement membrane (GBM) and induce complement activation and inflammation.

These immune complexes are visible on immunofluorescence microscopy as **granular deposits of IgG, IgM, and C3** on the GBM and mesangium, producing a "**starry sky**" appearance. Electron microscopy can show the immune deposits as discrete, electron-dense, subepithelial humps on the GBM. The classic light microscopy finding in PSGN is enlarged, diffusely hypercellular glomeruli due to leukocyte infiltration (neutrophils and monocytes) and mesangial and endothelial cell proliferation.

Laboratory studies show decreased serum complement (eg, C3) due to consumption, and elevated titers of streptococcal antibodies (eg, anti-DNAse B, antihyaluronidase, antistreptolysin O [ASO, which is typically elevated with pharyngitis but often undetectable after skin infections]).

(Choice A) Disruption of the GBM in PSGN causes increased filtration of proteins such as albumin, which are lost in urine and do not deposit in the GBM. The loss of albumin results in decreased plasma oncotic pressure and subsequent peripheral edema.

(Choice B) Complement activation in PSGN occurs primarily via the alternative and lectin pathways, resulting in glomerular C3 deposition without significant C1 or C4 deposits. Subendothelial C1q deposits are characteristic of type 1 membranoproliferative GN.

(Choice D) Fibrin deposits are found in rapidly proliferative (crescentic) GN.

(Choice E) IgE deposits are sometimes seen in lupus nephritis and are confined to the capillary wall. These are associated with a poorer prognosis.

(Choice F) M protein is a component of the streptococcal cell wall that acts as an antiphagocytic virulence factor. The cross-reactivity of antibodies directed against M protein within myocardial cells may be responsible for rheumatic heart disease. However, M protein has not been isolated in the immune complexes in PSGN.

Educational objective:

Exhibit Display

Nephritic vs nephrotic syndrome

	Nephritic	Nephrotic
Onset	Abrupt	Insidious
GFR	Low	Normal or low
Serum albumin	Normal	Low
Edema	±	++
Hypertension	++	±
Casts	RBC casts	Fatty or none
Proteinuria	±	++
Hematuria	++	±
Pyuria	+	None

GFR = glomerular filtration rate; RBC = red blood cell.
+ = present; ++ = significant.

Add To New Card | Existing Card

membrane

An 8-year-old boy is brought to the office due to acute facial puffiness. His mother reports that for the preceding 24 hours he has been easily fatigued and has had dark urine. The patient was treated for a skin infection 3 weeks ago but has no chronic medical conditions. Temperature is 36.1 C (97 F) and blood pressure is 140/94 mm Hg. Physical examination shows periorbital edema and mild pitting edema along the ankles. The remainder of the examination shows no abnormalities. A representative renal biopsy sample is shown in the below image.

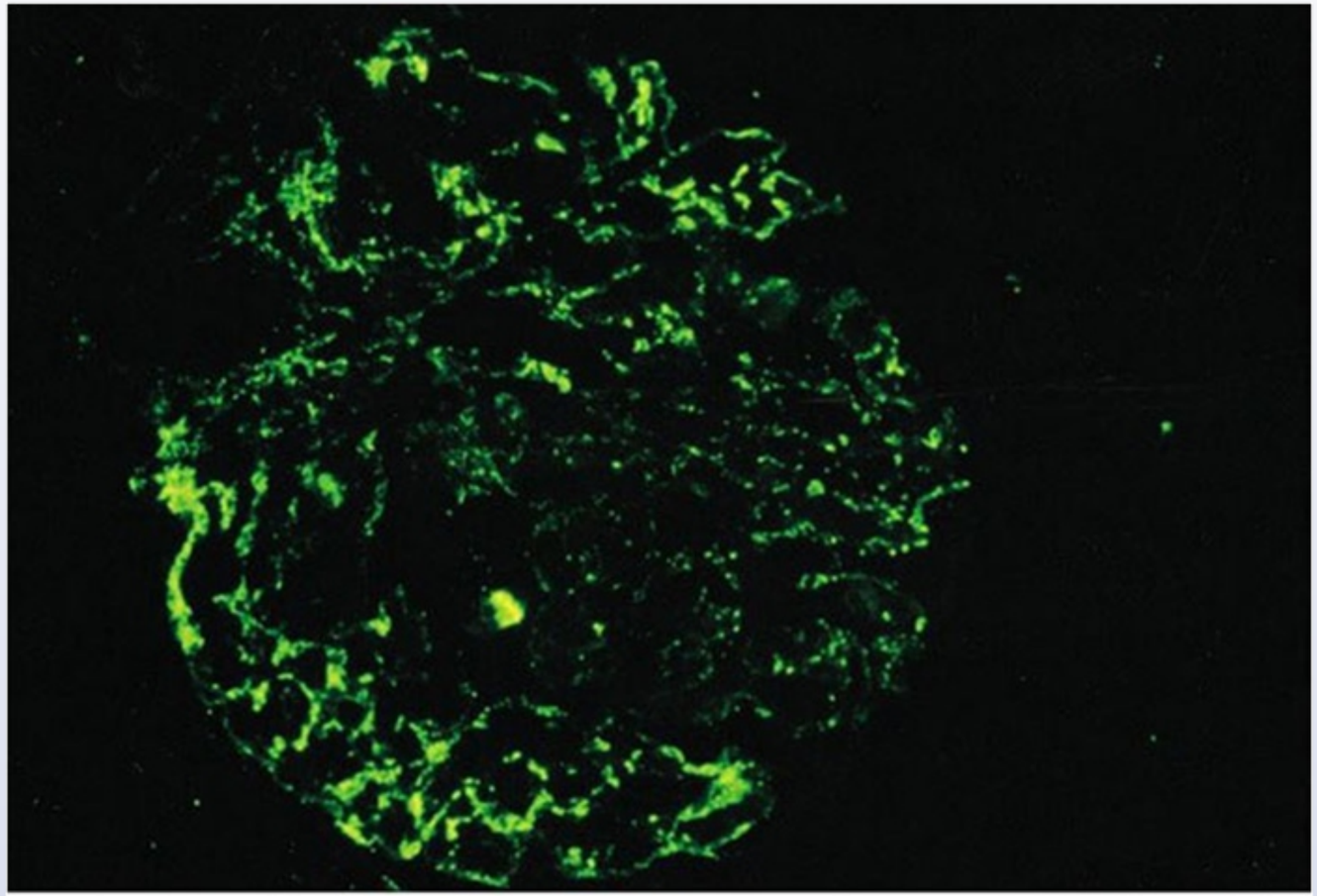

Displayed with permission from Springer Healthcare Ltd. © Copyright 1999 by Current Medicine

Immunofluorescence patterns in the glomerulus

Linear appearance
- Anti-glomerular basement membrane disease

Granular appearance
- Immune-complex deposition diseases (eg, poststreptococcal glomerulonephritis, membranous nephropathy)

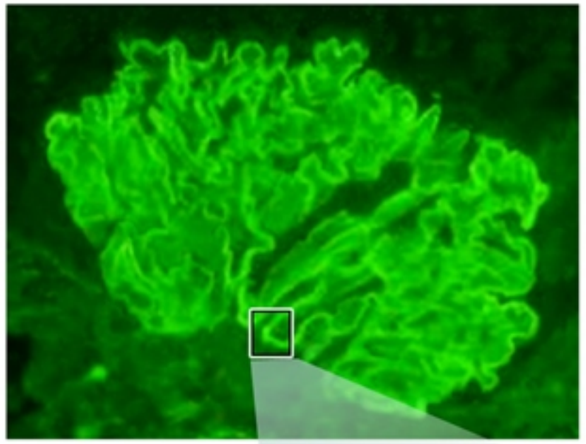

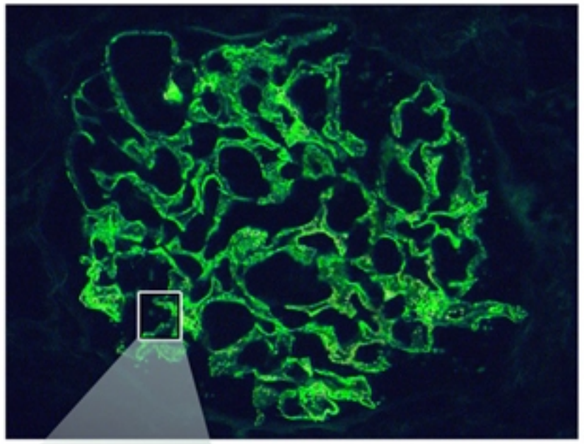

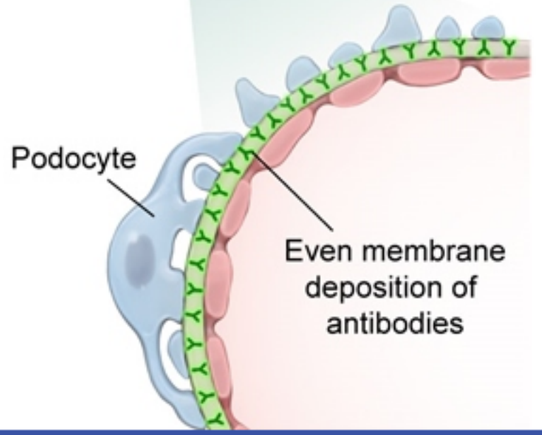

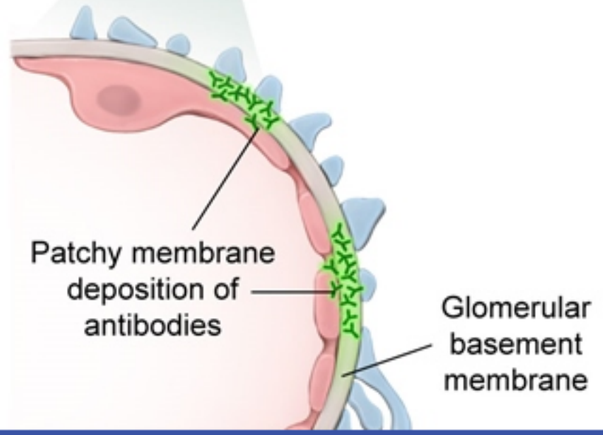

Settings

1
2
3
4
5
6
7
8
9
10
11
12
13
14
15
16
17
18
19
20
21
22
23
24
25
26

Item 8 of 26
Question Id: 8

Mark | Previous | Next | Full Screen | Tutorial | Lab Values | Notes | Calculator | Reverse Color | Text Zoom | Settings

Exhibit Display

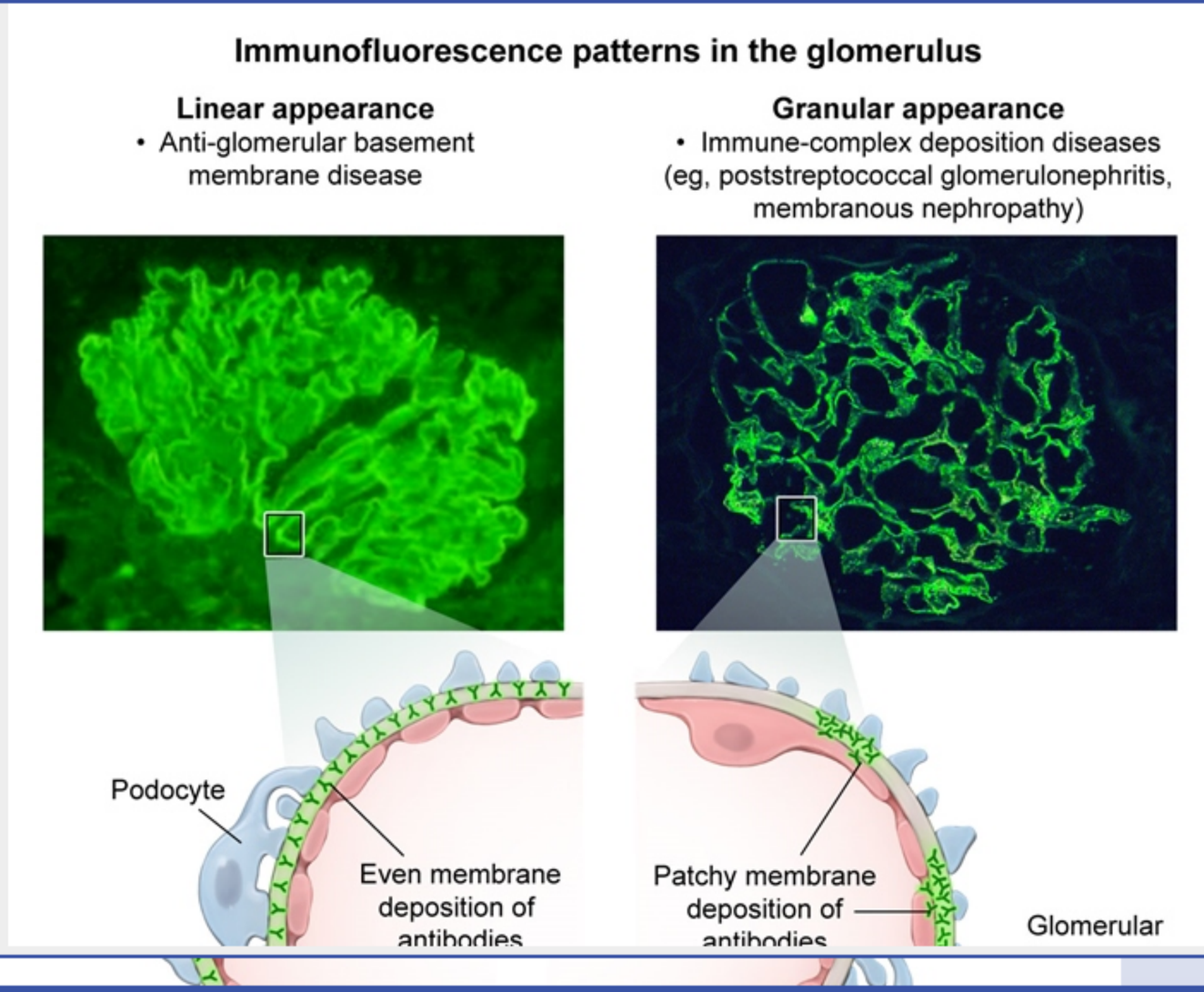

Block Time Remaining: 00:01:12
TUTOR

4 | Feedback | Suspend | End Block

Exhibit Display

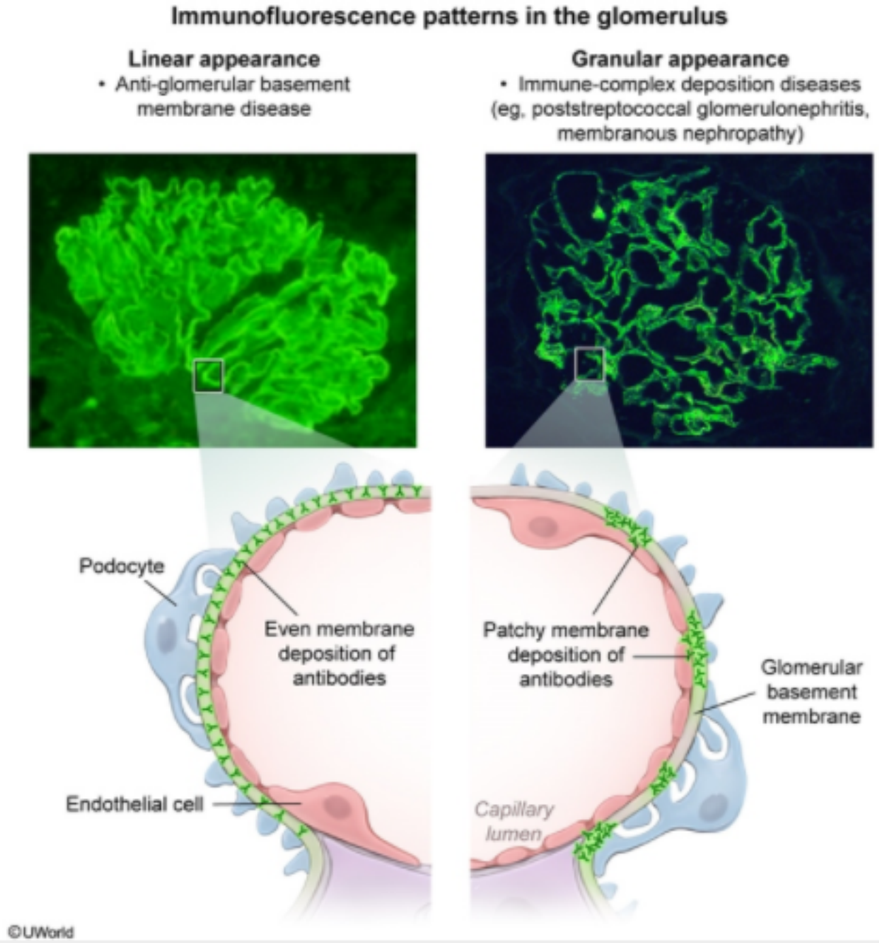

Zoom In | Zoom Out | Reset | Add To New Card | Existing Card

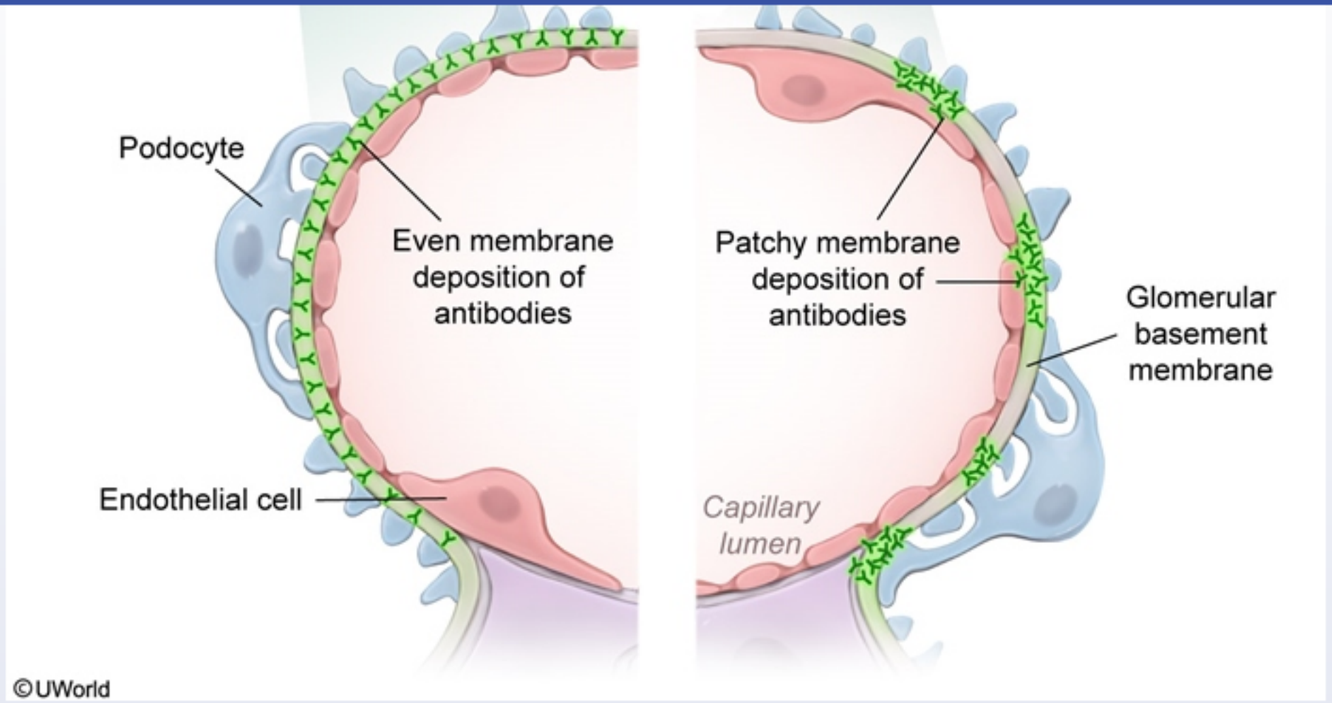

This pediatric patient with nephritic syndrome (eg, periorbital edema, hematuria, hypertension) following a recent skin infection most likely has **poststreptococcal glomerulonephritis** (PSGN). PSGN is the most common cause of nephritic syndrome in children and typically occurs 2-4 weeks after exposure to group A beta-hemolytic *Streptococcus* (eg, pharyngitis, skin infection). Antigens expressed on nephritogenic streptococcal species combine with antibodies to form immune complexes, which are deposited on the glomerular basement membrane (GBM) and induce complement activation and inflammation.

These immune complexes are visible on immunofluorescence microscopy as **granular deposits of IgG, IgM, and C3** on the GBM and mesangium, producing a "**starry sky**" appearance. Electron microscopy can show the immune deposits as discrete, electron-dense, subepithelial humps on the GBM. The classic light microscopy finding in PSGN is enlarged, diffusely hypercellular glomeruli due to leukocyte infiltration (neutrophils and monocytes) and mesangial and endothelial cell proliferation.

Laboratory studies show decreased serum complement (eg, C3) due to consumption, and elevated titers of streptococcal antibodies (eg, anti-

©UWorld

This pediatric patient with nephritic syndrome (eg, periorbital edema, hematuria, hypertension) following a recent skin infection most likely has **poststreptococcal glomerulonephritis** (PSGN). PSGN is the most common cause of nephritic syndrome in children and typically occurs 2-4 weeks after exposure to group A beta-hemolytic *Streptococcus* (eg, pharyngitis, skin infection). Antigens expressed on nephritogenic streptococcal species combine with antibodies to form immune complexes, which are deposited on the glomerular basement membrane (GBM) and induce complement activation and inflammation.

These immune complexes are visible on immunofluorescence microscopy as **granular deposits of IgG, IgM, and C3** on the GBM and mesangium, producing a "**starry sky**" appearance. Electron microscopy can show the immune deposits as discrete, electron-dense, subepithelial humps on the GBM. The classic light microscopy finding in PSGN is enlarged, diffusely hypercellular glomeruli due to leukocyte infiltration (neutrophils and monocytes) and mesangial and endothelial cell proliferation.

Laboratory studies show decreased serum complement (eg, C3) due to consumption, and elevated titers of streptococcal antibodies (eg, anti-DNAse B, antihyaluronidase, antistreptolysin O [ASO, which is typically elevated with pharyngitis but often undetectable after skin infections]).

(Choice A) Disruption of the GBM in PSGN causes increased filtration of proteins such as albumin, which are lost in urine and do not deposit in the GBM. The loss of albumin results in decreased plasma oncotic pressure and subsequent peripheral edema.

(Choice B) Complement activation in PSGN occurs primarily via the alternative and lectin pathways, resulting in glomerular C3 deposition without significant C1 or C4 deposits. Subendothelial C1q deposits are characteristic of type 1 membranoproliferative GN.

(Choice D) Fibrin deposits are found in rapidly proliferative (crescentic) GN.

(Choice E) IgE deposits are sometimes seen in lupus nephritis and are confined to the capillary wall. These are associated with a poorer prognosis.

(Choice F) M protein is a component of the streptococcal cell wall that acts as an antiphagocytic virulence factor. The cross-reactivity of antibodies directed against M protein within myocardial cells may be responsible for rheumatic heart disease. However, M protein has not been isolated in the immune complexes in PSGN.

Educational objective:
Poststreptococcal glomerulonephritis is most common in children and presents with nephritic syndrome (eg, renal failure, hypertension, hematuria

Settings

1
2
3
4
5
6
7
8
9
10
11
12
13
14
15
16
17
18
19
20
21
22
23
24
25
26

Item 8 of 26
Question Id: 8

Mark | Previous | Next | Full Screen | Tutorial | Lab Values | Notes | Calculator | Reverse Color | Text Zoom | Settings

©UWorld

Exhibit Display

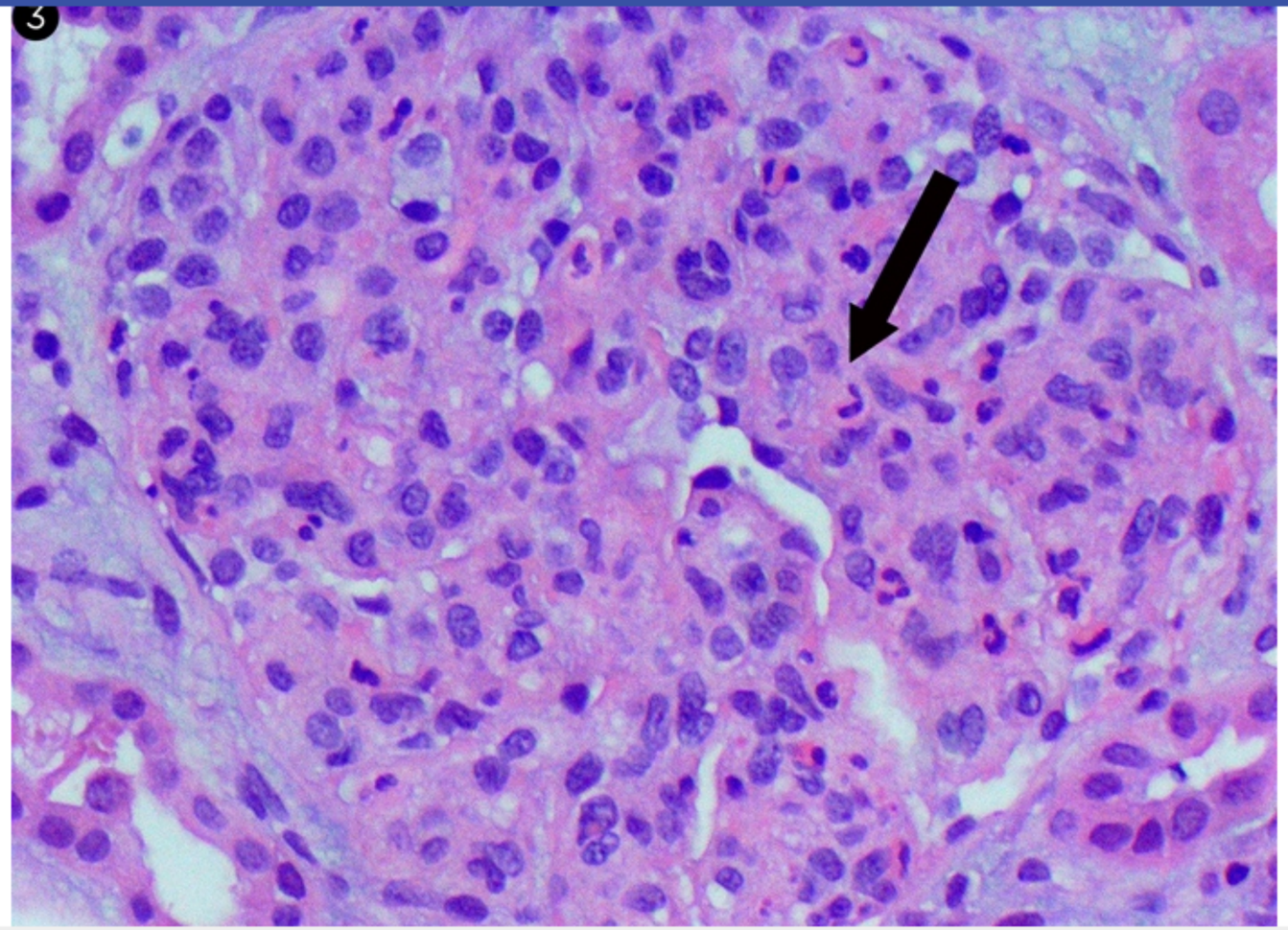

Zoom In | Zoom Out | Reset | Add To New Card | Existing Card

Poststreptococcal glomerulonephritis is most common in children and presents with nephritic syndrome (eg, renal failure, hypertension, hematuria

Block Time Remaining: 00:01:12
TUTOR

4 | Feedback | Suspend | End Block

Settings

1
2
3
4
5
6
7
8
9
10
11
12
13
14
15
16
17
18
19
20
21
22
23
24
25
26

Item 9 of 26
Question Id: 1536

Mark | Previous | Next | Full Screen | Tutorial | Lab Values | Notes | Calculator | Reverse Color | Text Zoom | Settings

A 68-year-old man with a history of Parkinson disease is hospitalized for pneumonia and sepsis. The patient is treated with intravenous (IV) fluids and antibiotics. He is also started on an infusion of IV dopamine for hemodynamic support. Although the manifestations of Parkinson disease are attributed to dopaminergic neuron degeneration in the substantia nigra, IV dopamine does not improve this patient's Parkinson symptoms. Which of the following cell structures accounts for this lack of responsiveness?

A. Desmosomes
B. Fenestrae
C. Gap junctions
D. Hemidesmosomes
E. Intermediate junctions
F. Tight junctions

Submit

Block Time Remaining: 00:01:13
TUTOR

3 | Feedback | Suspend | End Block

A 68-year-old man with a history of Parkinson disease is hospitalized for pneumonia and sepsis. The patient is treated with intravenous (IV) fluids and antibiotics. He is also started on an infusion of IV dopamine for hemodynamic support. Although the manifestations of Parkinson disease are attributed to dopaminergic neuron degeneration in the substantia nigra, IV dopamine does not improve this patient's Parkinson symptoms. Which of the following cell structures accounts for this lack of responsiveness?

- A. Desmosomes (1%)
- B. Fenestrae (4%)
- C. Gap junctions (7%)
- D. Hemidesmosomes (1%)
- E. Intermediate junctions (0%)
- ✓ F. Tight junctions (85%)

Omitted
Correct answer
F

85%
Answered correctly

02 secs
Time Spent

02/09/2020
Last Updated

Explanation

Cell junctions

Settings

1
2
3
4
5
6
7
8
9
10
11
12
13
14
15
16
17
18
19
20
21
22
23
24
25
26

Item 9 of 26
Question Id: 1536

Mark | Previous | Next | Full Screen | Tutorial | Lab Values | Notes | Calculator | Reverse Color | Text Zoom | Settings

Cell junctions

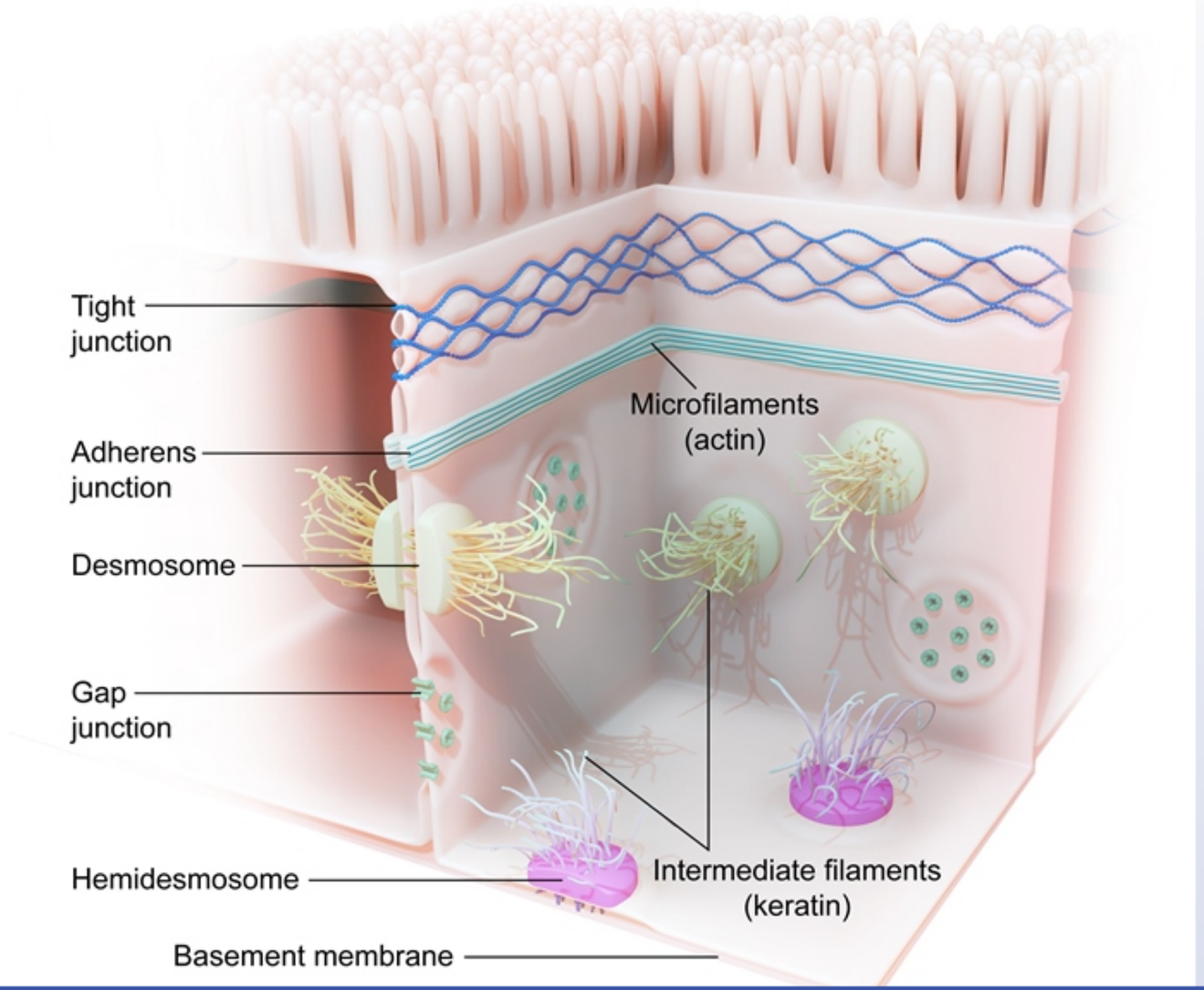

Block Time Remaining: 00:01:14
TUTOR

3 | Feedback | Suspend | End Block

This patient's Parkinson symptoms do not improve with intravenous dopamine infusion because dopamine is unable to cross the blood-brain barrier. The **blood-brain barrier** is formed by tight junctions between nonfenestrated capillary endothelial cells that prevent the **paracellular** passage of fluid and solutes. **Tight junctions**, also known as zonulae occludentes, are composed of transmembrane proteins (eg, claudins and occludins) that associate with actin filaments, forming a **beltlike seal** around the apical intercellular space. This seal only permits the passage of substances from the blood to the brain via transcellular movement.

Transcellular movement of dopamine is limited by the molecule's low lipid solubility and the lack of dopamine-specific transport carriers in capillary endothelial cells of the blood-brain barrier. L-DOPA (dopamine precursor) also has low lipid solubility, but it is able to enter the brain due to its high affinity for the large neutral amino acid transporter.

(Choice A) Desmosomes (maculae adherentes) are spotlike junctions that anchor adjacent cells together via keratin intermediate filament interactions. Autoantibodies against desmosomes in the stratum spinosum of the skin cause pemphigus vulgaris.

(Choice B) Fenestrae are small pores within endothelial cells that allow free fluid exchange between the intravascular and extravascular spaces. They are found in capillaries perfusing the intestine, renal tubules, and endocrine glands.

(Choice C) Gap junctions are composed of connexin proteins that create channels between cells, permitting the free passage of small ions (eg, Ca^{2+}) and molecules.

(Choice D) Hemidesmosomes are similar to desmosomes but bind the basal layer of epithelial cells to the basement membrane. Autoantibodies against hemidesmosomes in the skin cause bullous pemphigoid.

(Choice E) Intermediate junctions (zonula adherens or belt desmosomes) are located below tight junctions and form a beltlike anchor between adjacent cells in association with actin microfilaments.

Educational objective:
The blood-brain barrier is formed by tight junctions between nonfenestrated capillary endothelial cells that prevent the paracellular passage of fluid and solutes. This barrier only permits the passage of substances from the blood to the brain via transcellular movement across the endothelial plasma membrane, which is limited by diffusion or carrier-mediated transport.

References

Settings

1
2
3
4
5
6
7
8
9
10
11
12
13
14
15
16
17
18
19
20
21
22
23
24
25
26

Item 10 of 26
Question Id: 1936

Mark | Previous | Next | Full Screen | Tutorial | Lab Values | Notes | Calculator | Reverse Color | Text Zoom | Settings

In an experiment, laboratory animals are subjected to a toxic insult that specifically targets the protein kinesin. Which of the following is most likely to be absent from tissues on histological examination as a result?

A. Nissl substance in pyramidal neurons
B. Secretory vesicles in nerve terminals
C. T-tubules in skeletal muscle cells
D. Desmosomes in epithelial lining cells
E. Microvilli in intestinal epithelial cells

Submit

Block Time Remaining: 00:01:16
TUTOR

2 | Feedback | Suspend | End Block

In an experiment, laboratory animals are subjected to a toxic insult that specifically targets the protein kinesin. Which of the following is most likely to be absent from tissues on histological examination as a result?

- A. Nissl substance in pyramidal neurons (7%)
- ✓ B. Secretory vesicles in nerve terminals (58%)
- C. T-tubules in skeletal muscle cells (14%)
- D. Desmosomes in epithelial lining cells (6%)
- E. Microvilli in intestinal epithelial cells (12%)

Omitted
Correct answer
B

58%
Answered correctly

03 secs
Time Spent

02/03/2020
Last Updated

Explanation

Kinesin is a microtubule associated motor protein whose function is anterograde transport of intracellular vesicles and organelles toward the plus (rapidly growing) ends of microtubules. Kinesin uses energy derived from ATP hydrolysis to move along the microtubule. The plus ends of microtubules typically lie at sites distant from the nucleus; thus, in neurons, kinesin carries vesicles and organelles away from the cell body and toward the nerve terminal. A targeted toxic insult to this protein would be expected to impair anterograde transport resulting in a deficiency of synaptic vesicles at the nerve terminal.

(Choice A) The Nissl substance in neurons corresponds to the rough endoplasmic reticulum.

B

Answered correctly | Time Spent | Last Updated

Explanation

Kinesin is a microtubule associated motor protein whose function is anterograde transport of intracellular vesicles and organelles toward the plus (rapidly growing) ends of microtubules. Kinesin uses energy derived from ATP hydrolysis to move along the microtubule. The plus ends of microtubules typically lie at sites distant from the nucleus; thus, in neurons, kinesin carries vesicles and organelles away from the cell body and toward the nerve terminal. A targeted toxic insult to this protein would be expected to impair anterograde transport resulting in a deficiency of synaptic vesicles at the nerve terminal.

(Choice A) The Nissl substance in neurons corresponds to the rough endoplasmic reticulum.

(Choice C) The transverse tubule (T-tubule) system is a tubular network located at the junction of the A and I bands of striated myocytes. T-tubules are open to the extracellular space and facilitate the spread of depolarization to the inside of the cell.

(Choice D) Desmosomes are protein aggregates that mediate cell-cell adhesion between epithelial cells.

(Choice E) Microvilli are small cylindrical extensions of the apical plasma membrane that contain actin thin filaments. Microvilli cover the apical surfaces of intestinal epithelial cells. They do not contain microtubules or microtubule associated proteins.

Educational Objective:
Kinesin is a microtubule-associated, ATP-powered motor protein that facilitates the anterograde transport of neurotransmitter-containing secretory vesicles down axons to synaptic terminals.

Histology	Nervous System	Neuronal physiology
Subject	System	Topic

Copyright © UWorld. All rights reserved.

A researcher is investigating factors affecting adrenal hormone synthesis and release. Intact adrenal glands are obtained from several autopsy specimens. Cells from a specific part of the gland, indicated by the arrow on the image of a whole adrenal gland shown below, are extracted for further analysis.

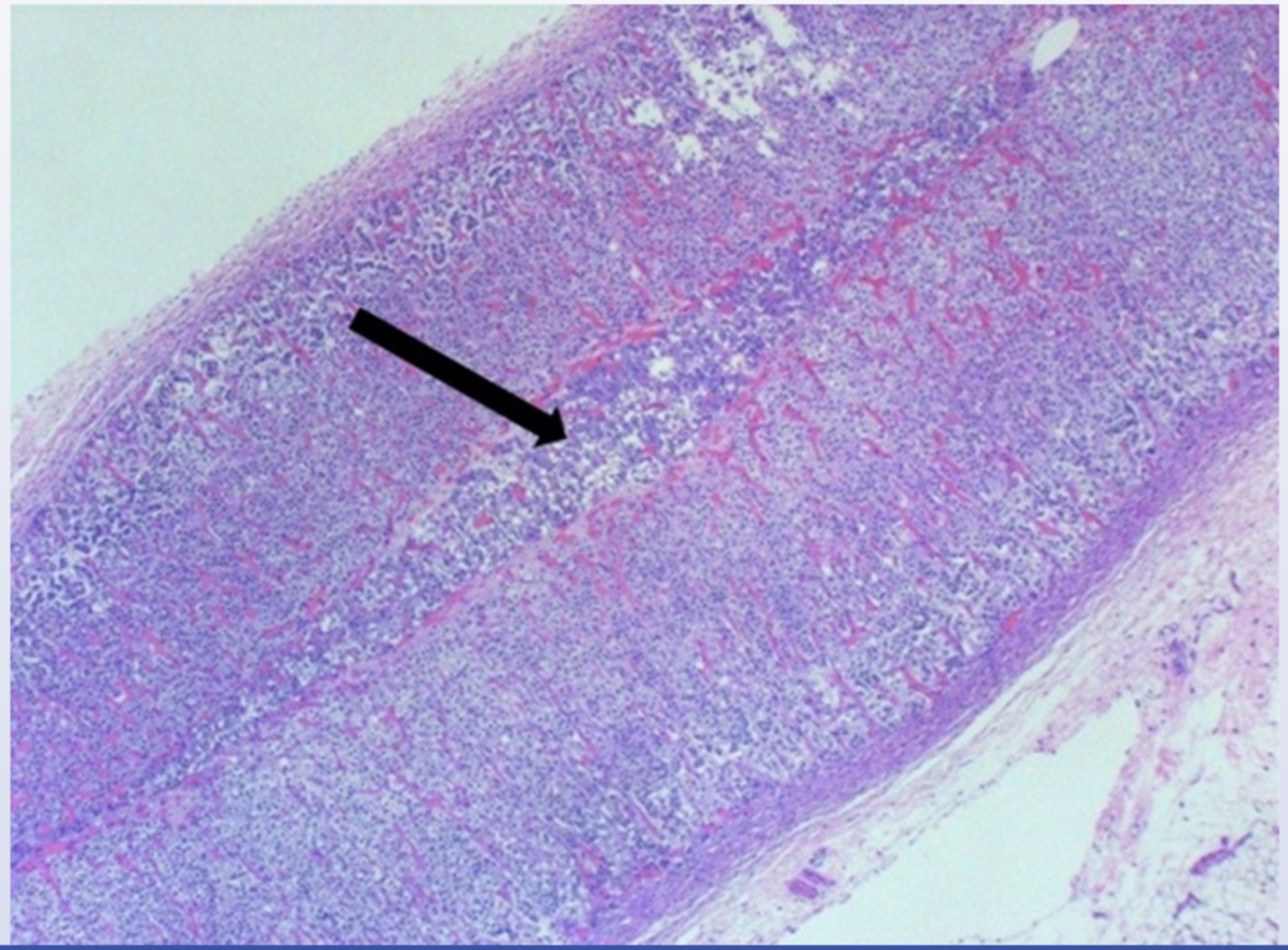

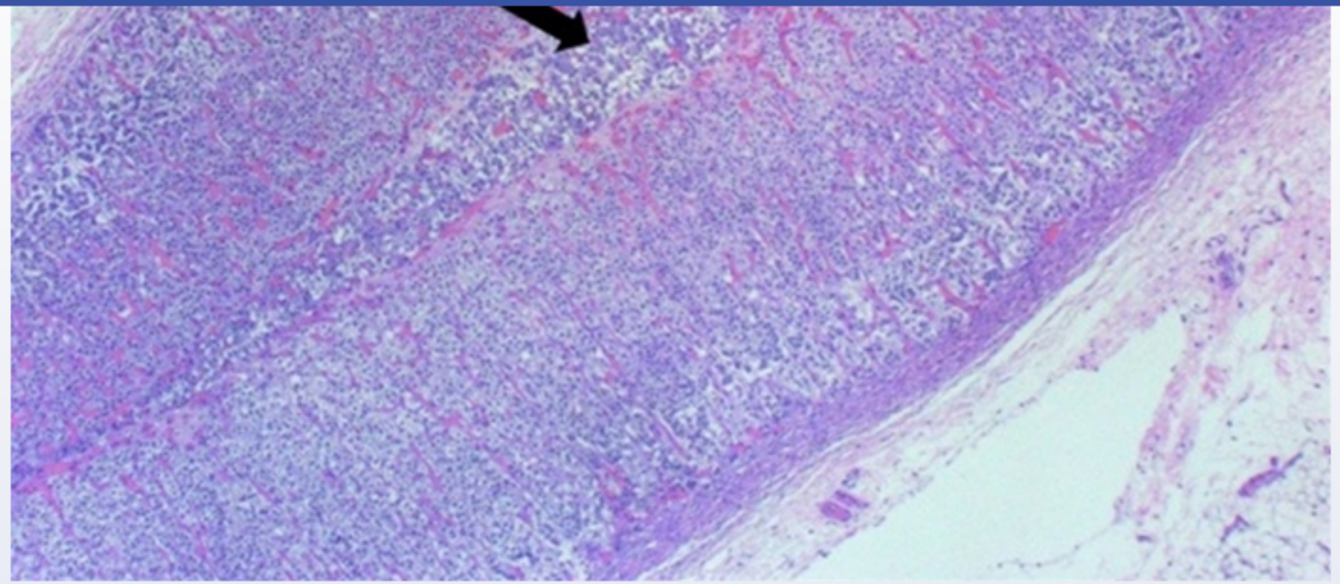

These cells are most likely to be directly activated by which of the following substances?

- A. Acetylcholine
- B. ACTH
- C. Angiotensin II
- D. Epinephrine
- E. Norepinephrine

Submit

Settings

1 2 3 4 5 6 7 8 9 10 11 12 13 14 15 16 17 18 19 20 21 22 23 24 25 26

Item 11 of 26
Question Id: 8424

Mark | Previous | Next | Full Screen | Tutorial | Lab Values | Notes | Calculator | Reverse Color | Text Zoom | Settings

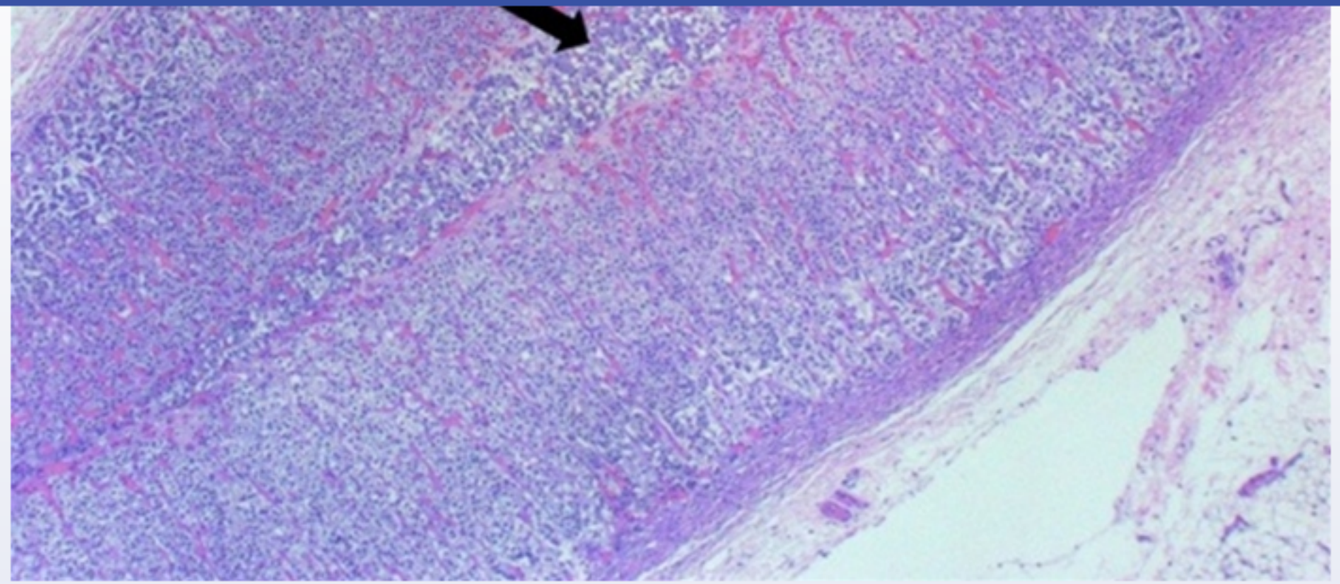

These cells are most likely to be directly activated by which of the following substances?

- ✓ A. Acetylcholine (47%)
- B. ACTH (32%)
- C. Angiotensin II (6%)
- D. Epinephrine (6%)
- E. Norepinephrine (6%)

Omitted
Correct answer

47%
Answered correctly

08 secs
Time Spent

07/05/2020
Last Updated

Block Time Remaining: 00:01:25
TUTOR

7 | Feedback | Suspend | End Block

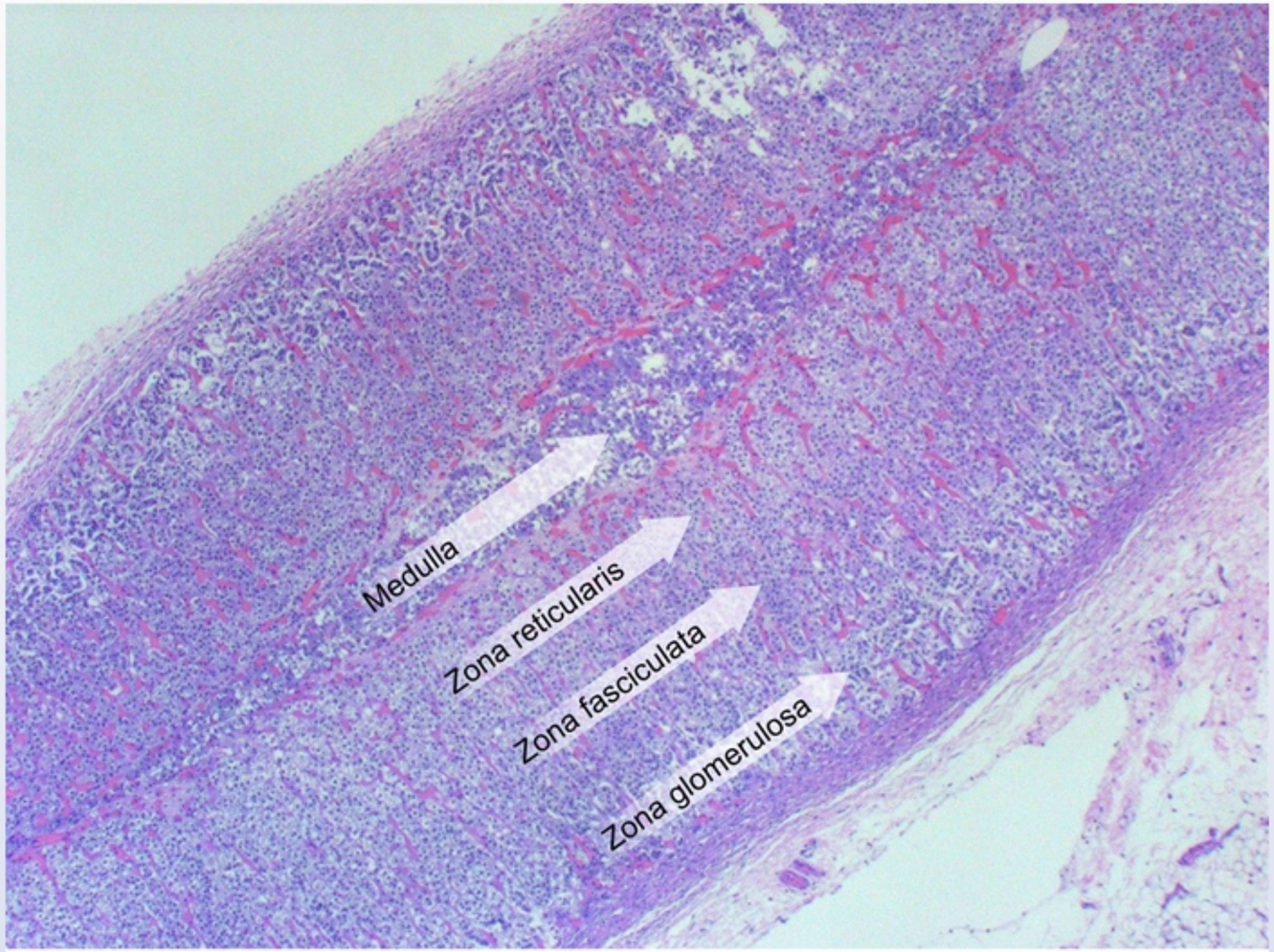

©UWorld

The adrenal gland is made up of an outer cortex (divided into 3 zones) and an inner medulla:

1. The zona glomerulosa is the outermost zone of the cortex and is composed of cells arranged in rounded or arched clusters (*glomus* is Latin

©UWorld

The adrenal gland is made up of an outer cortex (divided into 3 zones) and an inner medulla:

1. The zona glomerulosa is the outermost zone of the cortex and is composed of cells arranged in rounded or arched clusters (*glomus* is Latin for ball) that secrete mineralocorticoid hormones (primarily aldosterone).
2. The zona fasciculata is the middle zone and contains foamy-appearing cells in columns (*fascis* is Latin for bundle or stack) that secrete glucocorticoid hormones (primarily cortisol).
3. The zona reticularis is the inner zone of the cortex and contains cells in anastomosing cords (*rete* is Latin for net) that secrete androgens.
4. The adrenal medulla is sharply demarcated from the cortex and is composed of chromaffin cells with a deeply basophilic cytoplasm.

Chromaffin cells are modified neuroendocrine cells derived from the neural crest. They are **stimulated by acetylcholine** released by sympathetic preganglionic neurons and **secrete catecholamines** (80% epinephrine, 20% norepinephrine) directly into the bloodstream to amplify sympathetic nervous system activity.

(Choice B) ACTH stimulates secretion of glucocorticoid hormones from the zona fasciculata. Cortisol produced in response to ACTH increases the activity of the adrenal medullary enzyme phenylethanolamine N-methyltransferase, which catalyzes the conversion of norepinephrine to epinephrine. ACTH therefore indirectly upregulates medullary activity but does not directly control it.

(Choice C) Aldosterone secretion from the zona glomerulosa is regulated by angiotensin II and extracellular potassium levels.

(Choice D) Epinephrine released by the adrenal medulla acts on adrenergic receptors in the heart, lungs, liver, and skeletal muscle to increase sympathetic tone and mediate the acute stress response.

(Choice E) Most sympathetic postganglionic neurons release norepinephrine to activate adrenergic receptors on the target tissues. However, the preganglionic fibers innervating the adrenal medulla (and the postganglionic neurons innervating eccrine sweat glands) release acetylcholine.

Educational objective:
Chromaffin cells are modified neuroendocrine cells derived from the neural crest. Chromaffin cells in the adrenal medulla are stimulated by acetylcholine released by sympathetic preganglionic neurons and secrete catecholamines directly into the bloodstream to amplify sympathetic

4. The adrenal medulla is sharply demarcated from the cortex and is composed of chromaffin cells with a deeply basophilic cytoplasm.

Chromaffin cells are modified neuroendocrine cells derived from the neural crest. They are **stimulated by acetylcholine** released by sympathetic preganglionic neurons and **secrete catecholamines** (80% epinephrine, 20% norepinephrine) directly into the bloodstream to amplify sympathetic nervous system activity.

(Choice B) ACTH stimulates secretion of glucocorticoid hormones from the zona fasciculata. Cortisol produced in response to ACTH increases the activity of the adrenal medullary enzyme phenylethanolamine N-methyltransferase, which catalyzes the conversion of norepinephrine to epinephrine. ACTH therefore indirectly upregulates medullary activity but does not directly control it.

(Choice C) Aldosterone secretion from the zona glomerulosa is regulated by angiotensin II and extracellular potassium levels.

(Choice D) Epinephrine released by the adrenal medulla acts on adrenergic receptors in the heart, lungs, liver, and skeletal muscle to increase sympathetic tone and mediate the acute stress response.

(Choice E) Most sympathetic postganglionic neurons release norepinephrine to activate adrenergic receptors on the target tissues. However, the preganglionic fibers innervating the adrenal medulla (and the postganglionic neurons innervating eccrine sweat glands) release acetylcholine.

Educational objective:
Chromaffin cells are modified neuroendocrine cells derived from the neural crest. Chromaffin cells in the adrenal medulla are stimulated by acetylcholine released by sympathetic preganglionic neurons and secrete catecholamines directly into the bloodstream to amplify sympathetic nervous system activity.

References

- Acetylcholine nicotinic receptor subtypes in chromaffin cells.

Histology	Endocrine, Diabetes & Metabolism	Pheochromocytoma
Subject	System	Topic

Copyright © UWorld. All rights reserved.

Settings

1
2
3
4
5
6
7
8
9
10
11
12
13
14
15
16
17
18
19
20
21
22
23
24
25
26

Item 11 of 26
Question Id: 8424

Mark | Previous | Next | Full Screen | Tutorial | Lab Values | Notes | Calculator | Reverse Color | Text Zoom | Settings

Exhibit Display

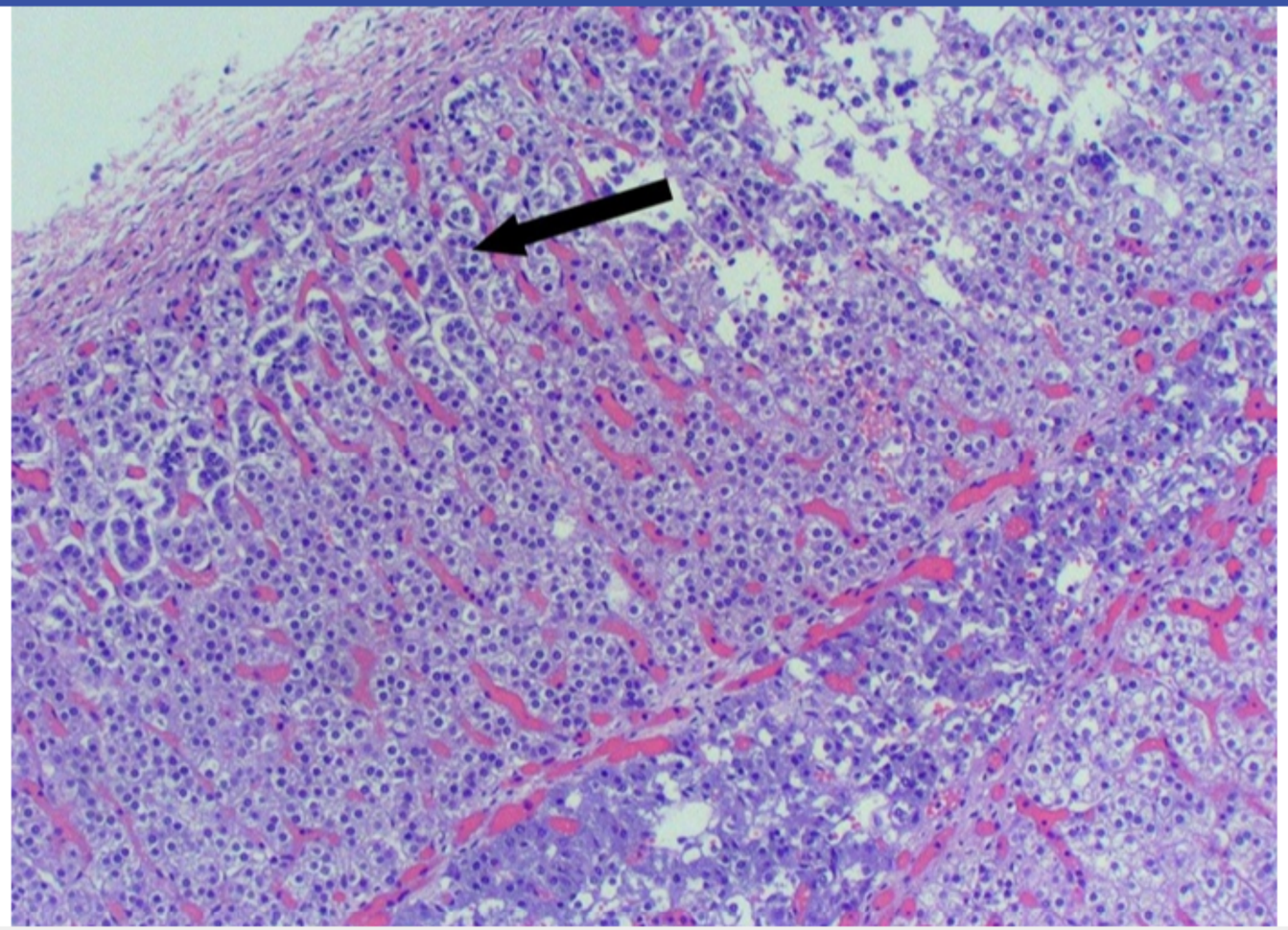

Zoom In | Zoom Out | Reset | Add To New Card | Existing Card

sympathetic nervous system activity

Block Time Remaining: 00:01:25
TUTOR

7 | Feedback | Suspend | End Block

Settings

1
2
3
4
5
6
7
8
9
10
11
12
13
14
15
16
17
18
19
20
21
22
23
24
25
26

Item 11 of 26
Question Id: 8424

Mark | Previous | Next | Full Screen | Tutorial | Lab Values | Notes | Calculator | Reverse Color | Text Zoom | Settings

Exhibit Display

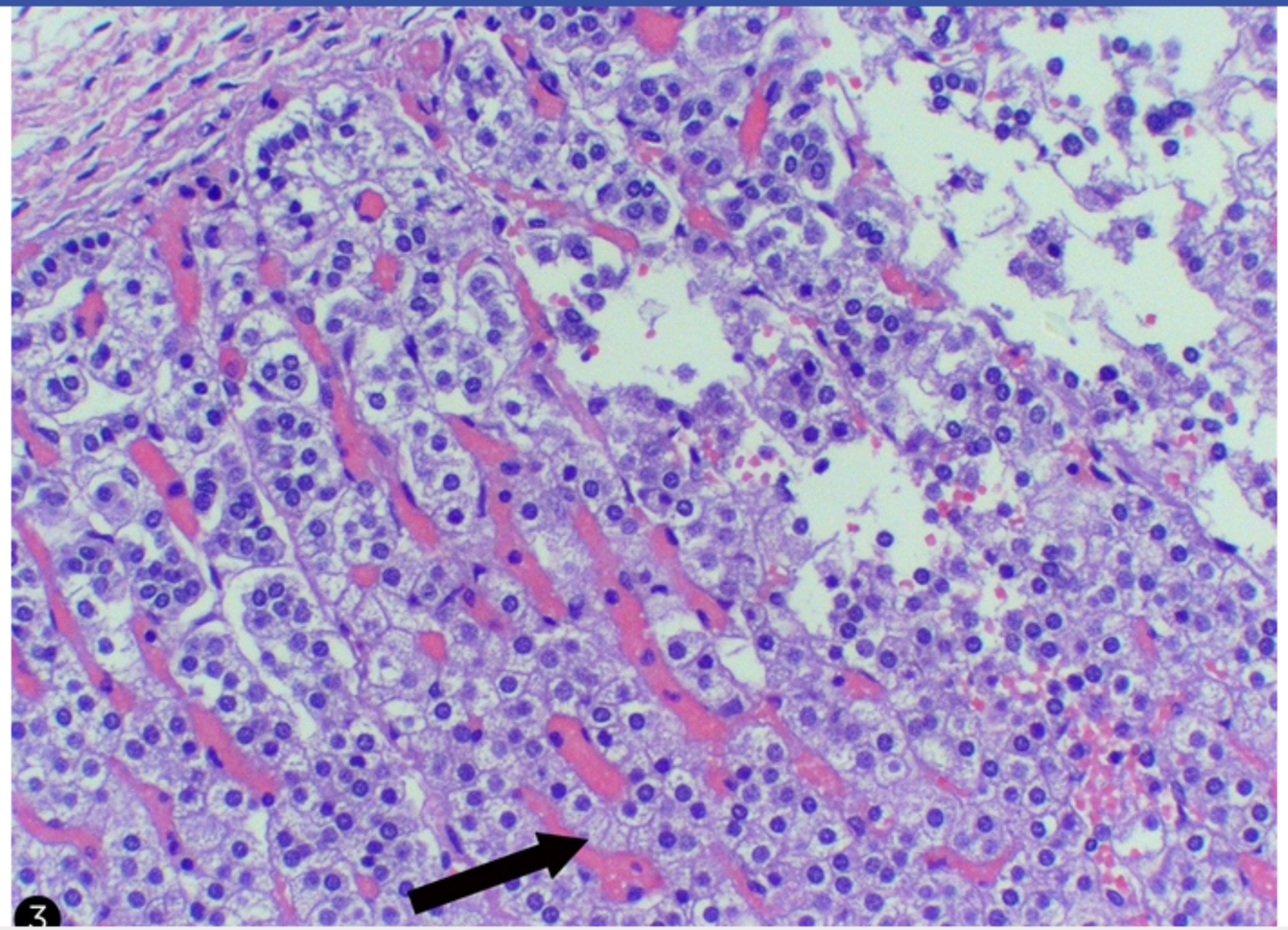

Zoom In | Zoom Out | Reset | Add To New Card | Existing Card

sympathetic nervous system activity

Block Time Remaining: 00:01:25
TUTOR

7 | Feedback | Suspend | End Block

Settings

1
2
3
4
5
6
7
8
9
10
11
12
13
14
15
16
17
18
19
20
21
22
23
24
25
26

Item 11 of 26
Question Id: 8424

Mark | Previous | Next | Full Screen | Tutorial | Lab Values | Notes | Calculator | Reverse Color | Text Zoom | Settings

Exhibit Display

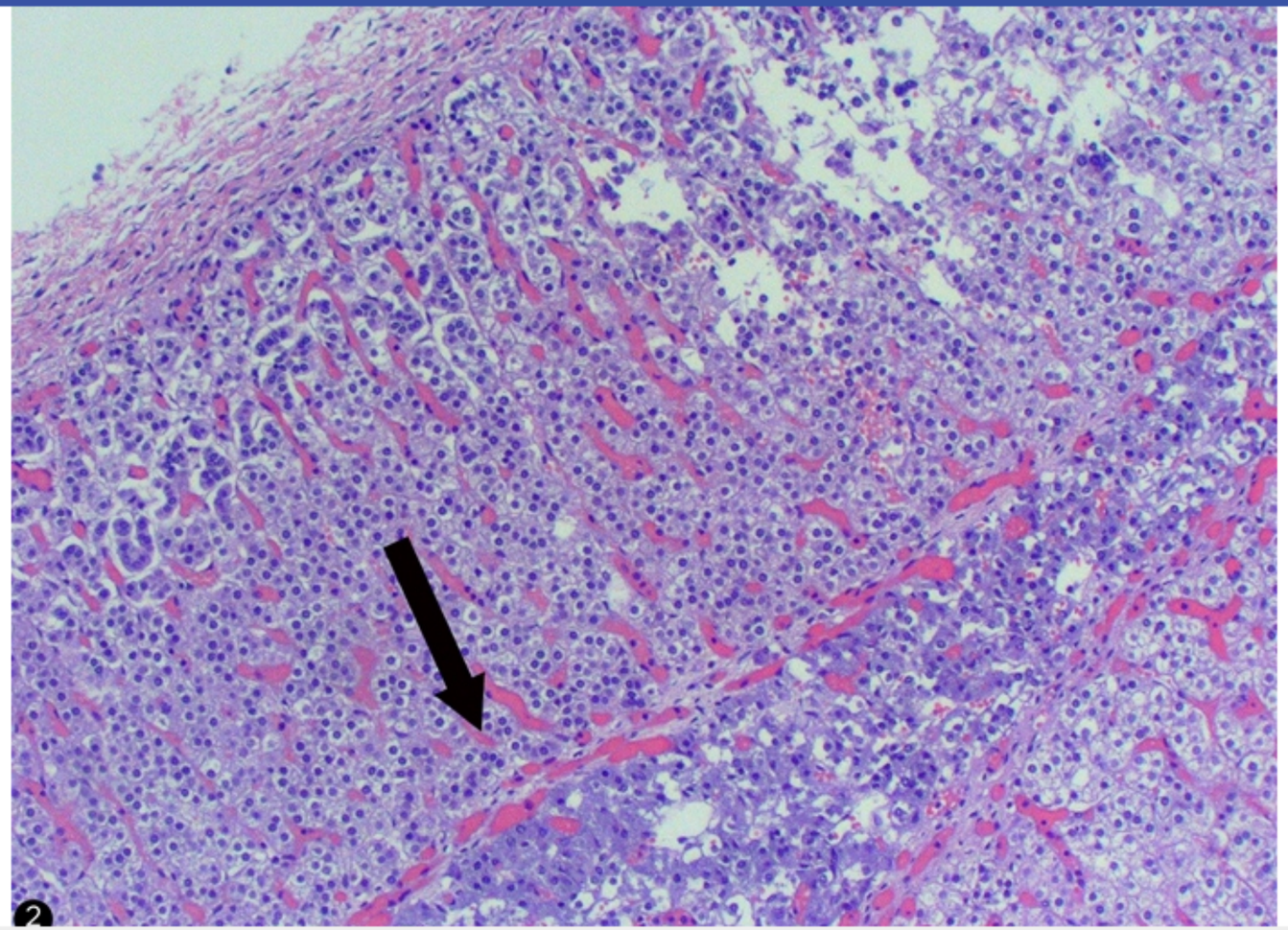

Zoom In | Zoom Out | Reset | Add To New Card | Existing Card

sympathetic nervous system activity

Block Time Remaining: 00:01:25
TUTOR

7 | Feedback | Suspend | End Block

Settings

1
2
3
4
5
6
7
8
9
10
11
12
13
14
15
16
17
18
19
20
21
22
23
24
25
26

Item 11 of 26
Question Id: 8424

Mark | Previous | Next | Full Screen | Tutorial | Lab Values | Notes | Calculator | Reverse Color | Text Zoom | Settings

Exhibit Display

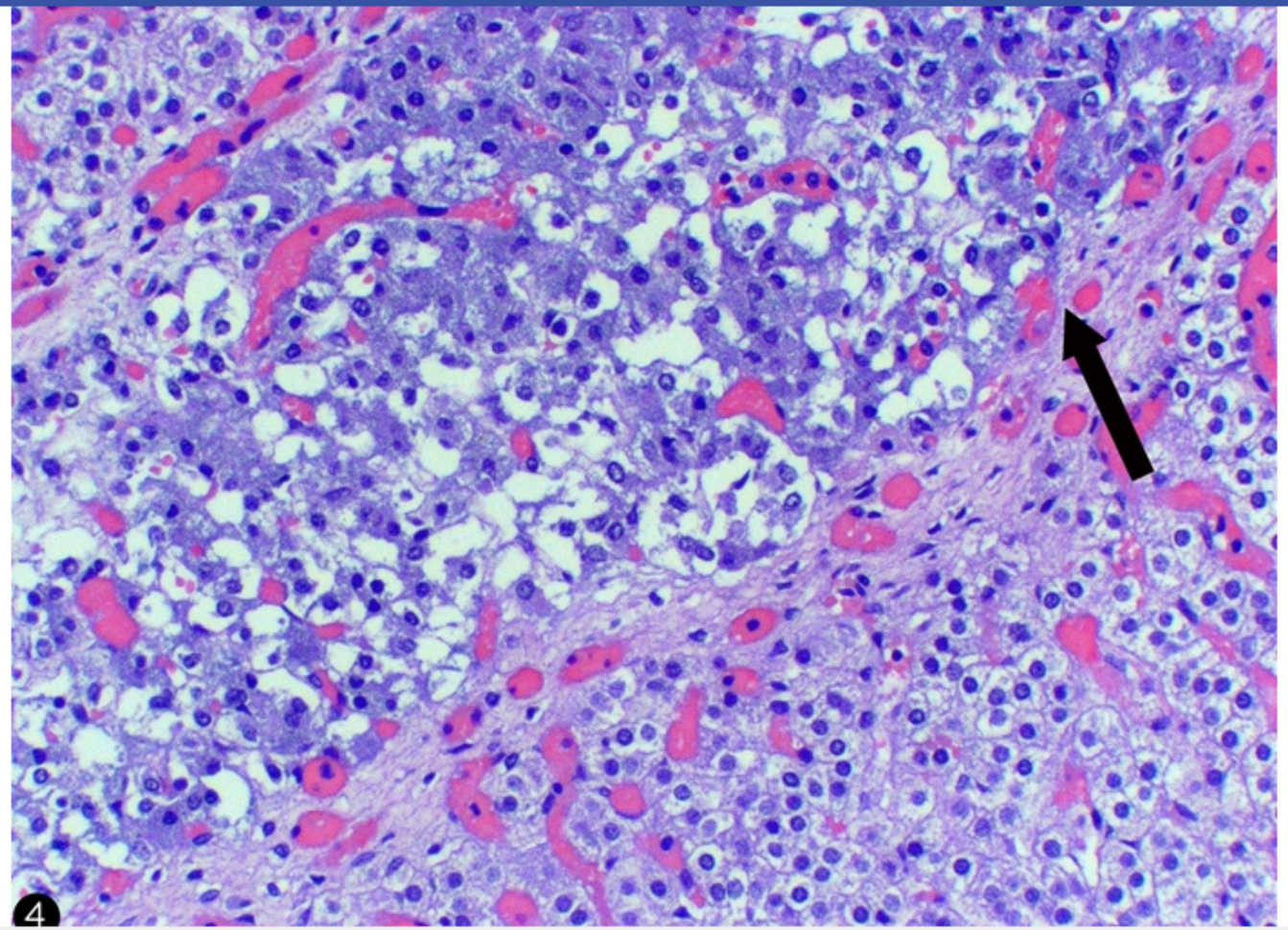

Zoom In | Zoom Out | Reset | Add To New Card | Existing Card

sympathetic nervous system activity

Block Time Remaining: 00:01:25
TUTOR

7 | Feedback | Suspend | End Block

A 43-year-old man comes to the office due to shortness of breath and fatigue. Over the last 2 weeks, his fatigue has been so profound that he has "little energy, even to get out of bed." The patient has no chills but has experienced recent weight gain and ankle swelling. He has no prior medical conditions and takes no medications. Blood pressure is 168/94 mm Hg, and pulse is 95/min and regular. The patient has bilateral lower extremity pitting edema limited to the ankles. Urinalysis reveals 2+ protein, white blood cell count of 5-7/hpf, and red blood cell count of 75-100/hpf. He undergoes a kidney biopsy; immunofluorescent microscopy findings are shown in the image below.

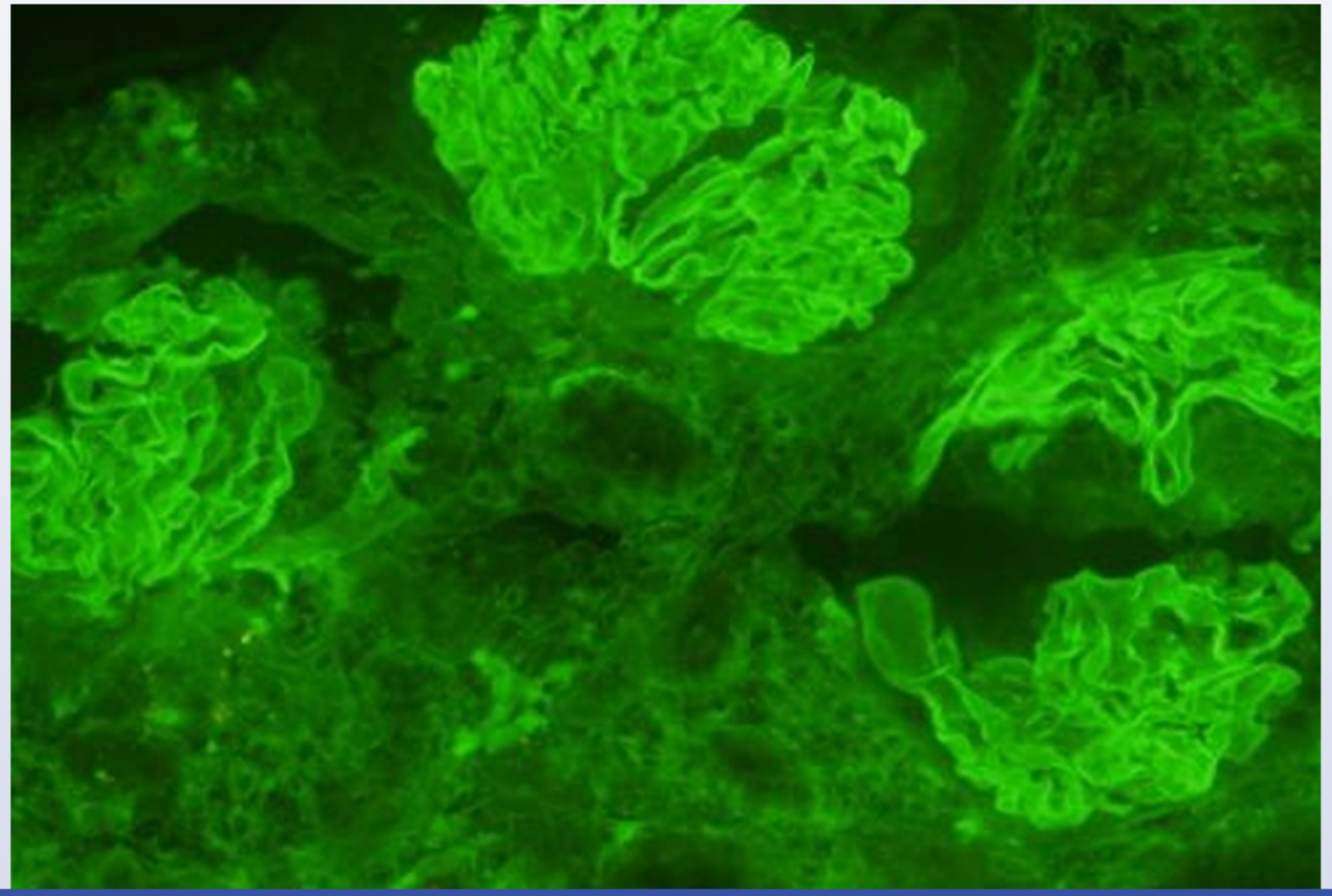

Settings

1
2
3
4
5
6
7
8
9
10
11
12
13
14
15
16
17
18
19
20
21
22
23
24
25
26

Item 12 of 26
Question Id: 9

Mark | Previous | Next | Full Screen | Tutorial | Lab Values | Notes | Calculator | Reverse Color | Text Zoom | Settings

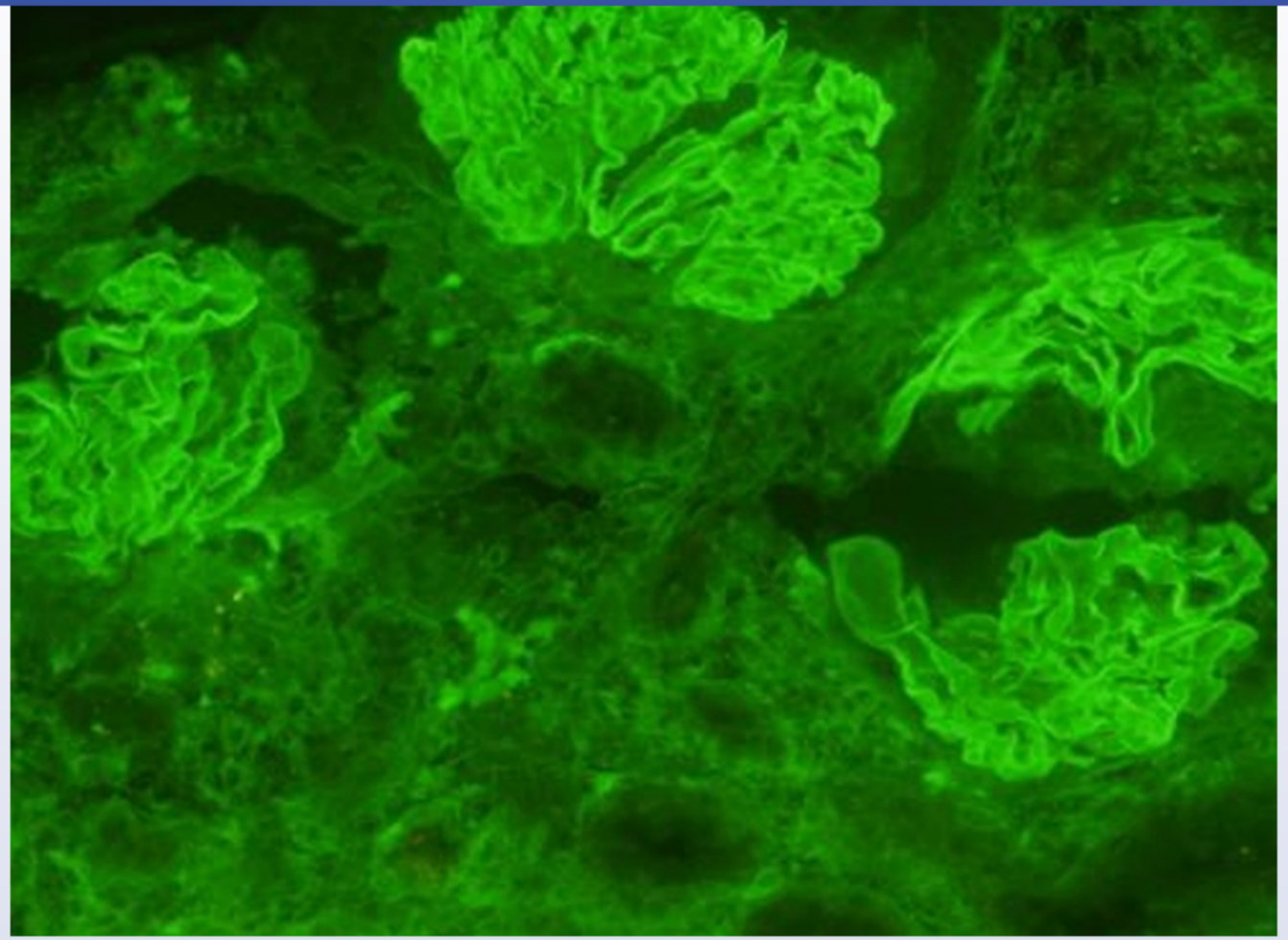

Which of the following would be the most likely finding on light microscopy in this patient?

A. Amyloid deposition

B. Crescent formation

Block Time Remaining: 00:01:29
TUTOR

8 | Feedback | Suspend | End Block

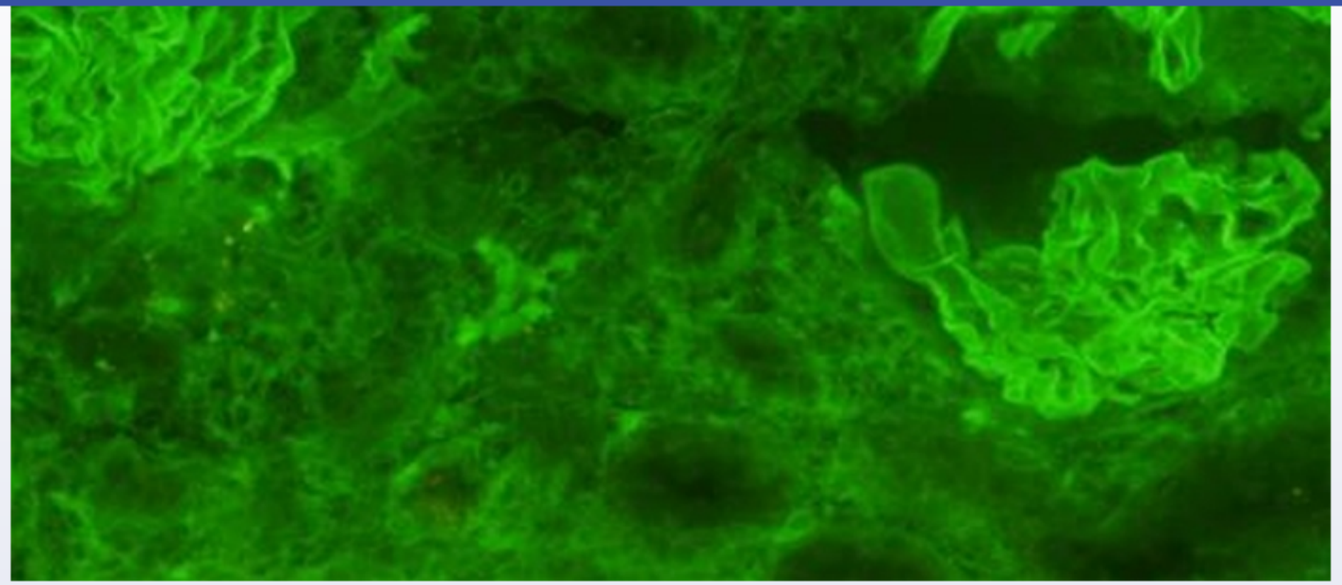

Which of the following would be the most likely finding on light microscopy in this patient?

A. Amyloid deposition

B. Crescent formation

C. Diffuse capillary wall thickening

D. Nodular glomerulosclerosis

E. Normal glomeruli

Submit

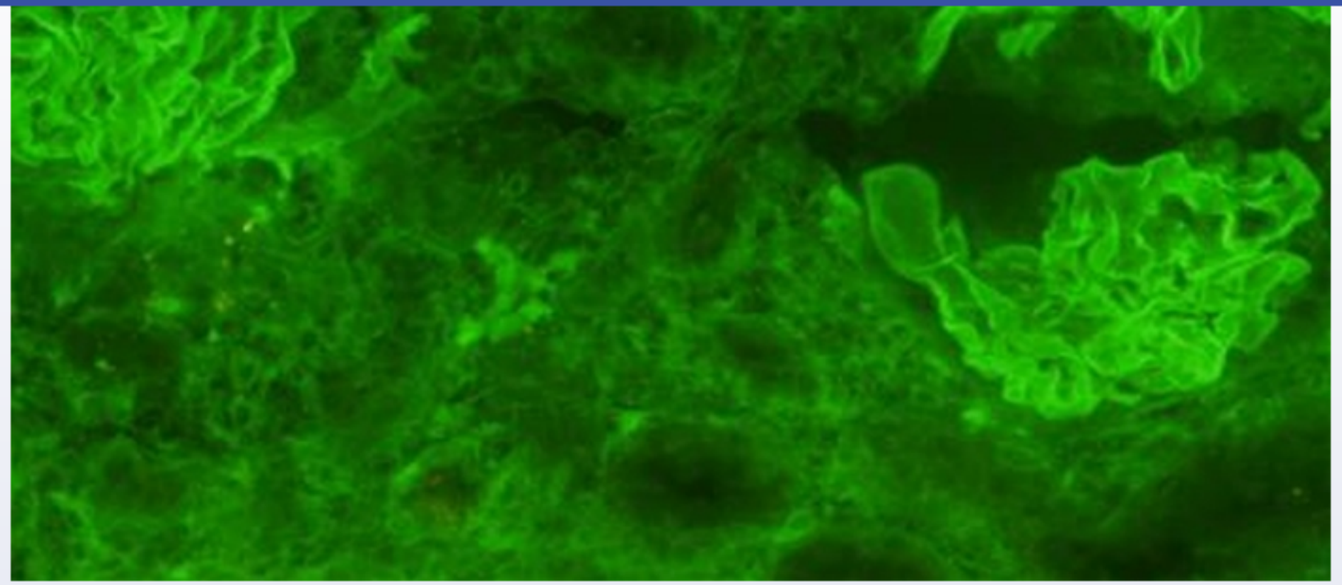

Which of the following would be the most likely finding on light microscopy in this patient?

- A. Amyloid deposition (13%)
- ✓ B. Crescent formation (51%)
- C. Diffuse capillary wall thickening (21%)
- D. Nodular glomerulosclerosis (10%)
- E. Normal glomeruli (3%)

Omitted
Correct answer

51%
Answered correctly

07 secs
Time Spent

03/20/2020
Last Updated

Immunofluorescence patterns in the glomerulus

Linear appearance
- Anti-glomerular basement membrane disease

Granular appearance
- Immune-complex deposition diseases (eg, poststreptococcal glomerulonephritis, membranous nephropathy)

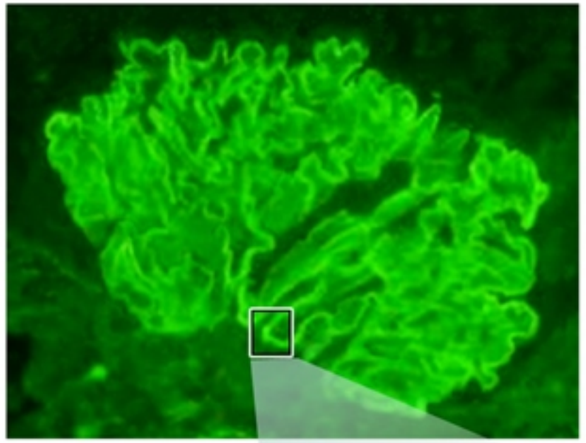

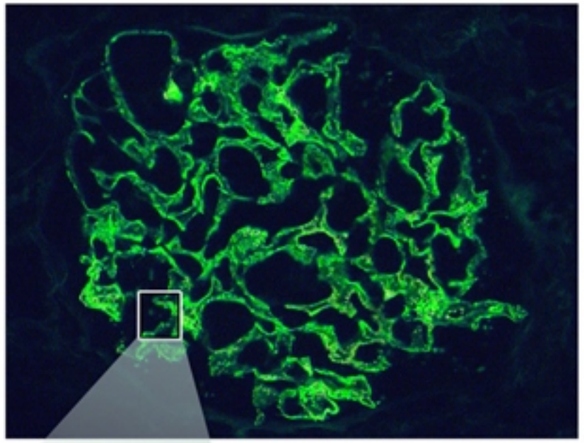

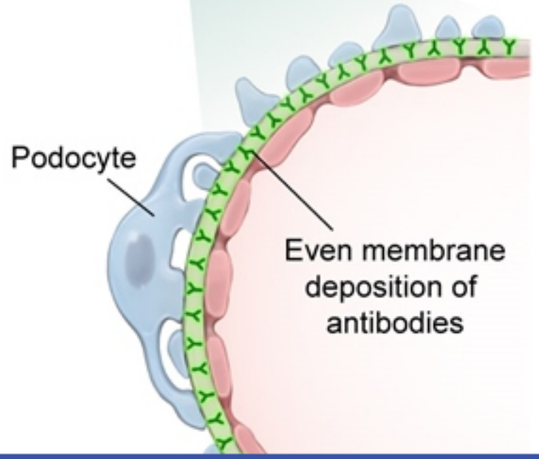

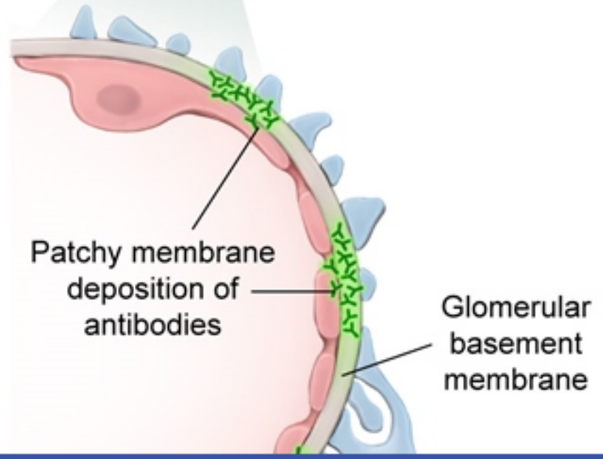

membranous nephropathy)

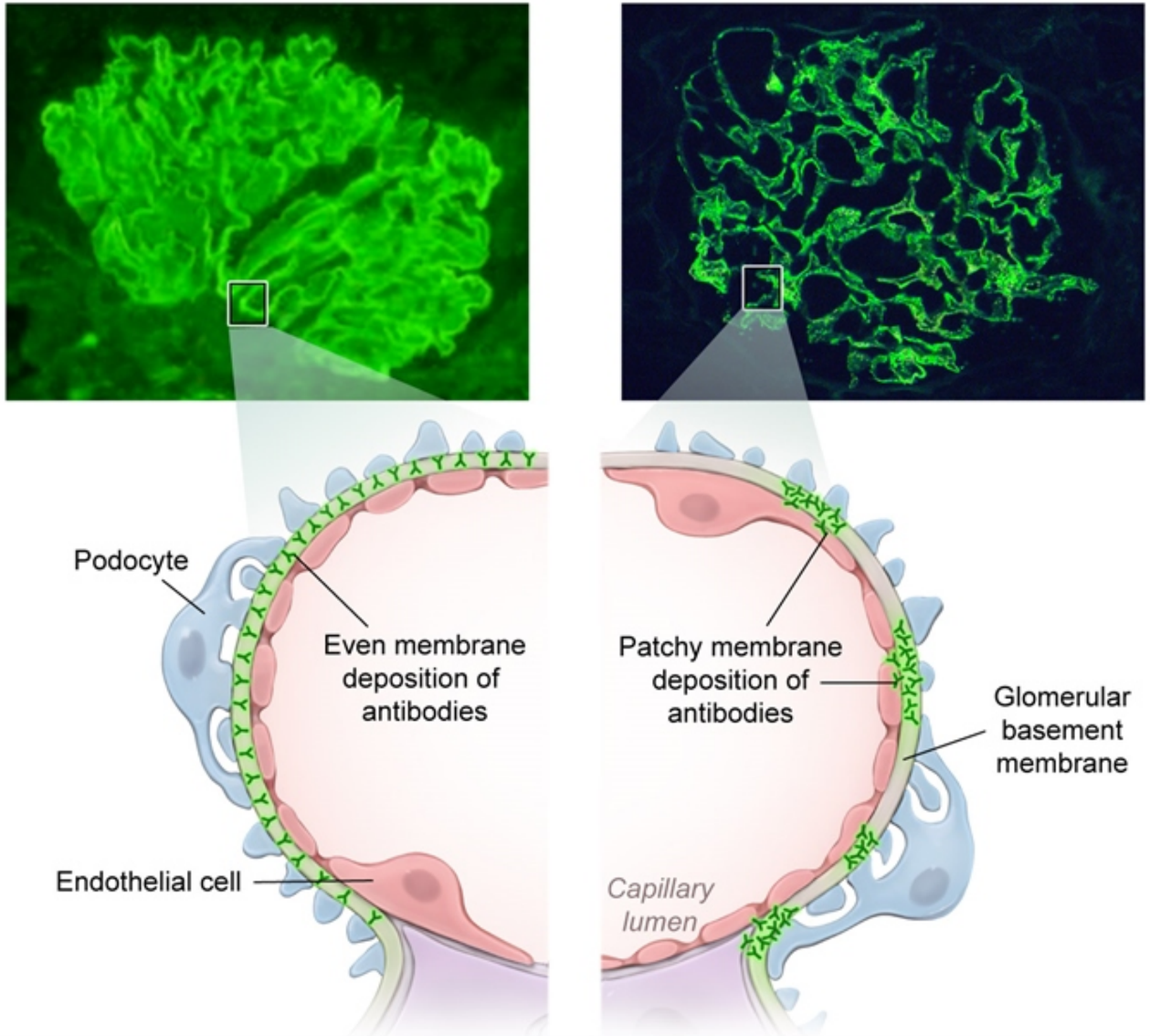

This patient has hypertension, hematuria (with mild pyuria), and moderate proteinuria, suggesting a diagnosis of nephritic syndrome. Immunofluorescence microscopy further demonstrates **linear deposits** of immunoglobulin (typically IgG) and complement along the glomerular basement membrane (GBM), a finding characteristic of **anti-GBM disease** (Goodpasture disease). Anti-GBM antibodies target collagen type IV, a component of the GBM, leading to subsequent complement deposition. This results in a form of **rapidly progressive (crescentic) glomerulonephritis** (RPGN).

RPGN is a syndrome of severe renal injury that results in abrupt-onset renal injury and decreased glomerular filtration (causing weight gain and edema, as seen in this patient). It can occur due to multiple diseases (eg, granulomatosis with polyangiitis, microscopic polyangiitis). The presence of glomerular crescents—composed of proliferating parietal cells, lymphocytes, macrophages, and fibrin—on light microscopy is diagnostic.

Anti-GBM antibodies may cross-react with collagen type IV in the pulmonary alveolar basement membrane and cause pulmonary hemorrhage, which presents as hemoptysis. The combination of renal failure and pulmonary hemorrhage in patients with anti-GBM antibodies is known as Goodpasture syndrome.

(Choice A) Renal amyloidosis causes a nephrotic syndrome (ie, heavy proteinuria, hypoalbuminemia, hyperlipidemia, edema); significant hematuria is unexpected. Immunofluorescence microscopy is nonspecific and may show diffuse mesangial staining (rather than distinct, linear immune deposits on the GBM). On Congo red staining, amyloid deposits appear red-pink under light microscopy and have an apple-green birefringence under polarized light.

(Choice C) In membranous nephropathy, which causes a nephrotic syndrome, immunofluorescence demonstrates granular deposits of IgG and C3 along the GBM. Uniform, diffuse capillary wall thickening is seen on light microscopy.

(Choice D) Nodular glomerulosclerosis (Kimmelstiel-Wilson lesion) and mesangial expansion are seen on light microscopy in diabetic nephropathy, which presents as a nephrotic syndrome. There are no immune deposits on immunofluorescence.

(Choice E) Normal glomeruli are found on light microscopy in minimal change disease, a condition that primarily affects children and presents as a nephrotic syndrome. There are no immune deposits on immunofluorescence.

Educational objective:
Anti-glomerular basement membrane (GBM) antibodies react with collagen type IV, causing rapidly progressive glomerulonephritis with glomerular

component of the GBM, leading to subsequent complement deposition. This results in a form of **rapidly progressive (crescentic)**

Exhibit Display

Crescentic glomerulonephritis

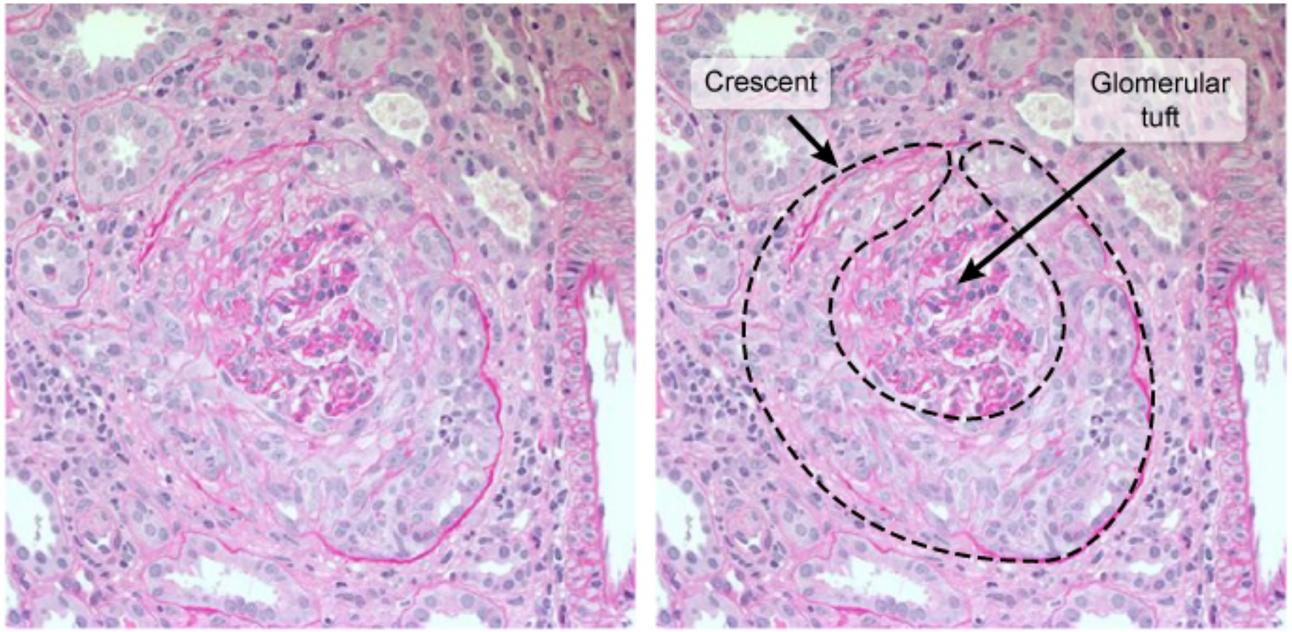

©UWorld

Zoom In | Zoom Out | Reset | Add To New Card | Existing Card

Histology Renal, Urinary Systems & Electrolytes Anti GBM disease

component of the GBM, leading to subsequent complement deposition. This results in a form of **rapidly progressive (crescentic)**

Exhibit Display

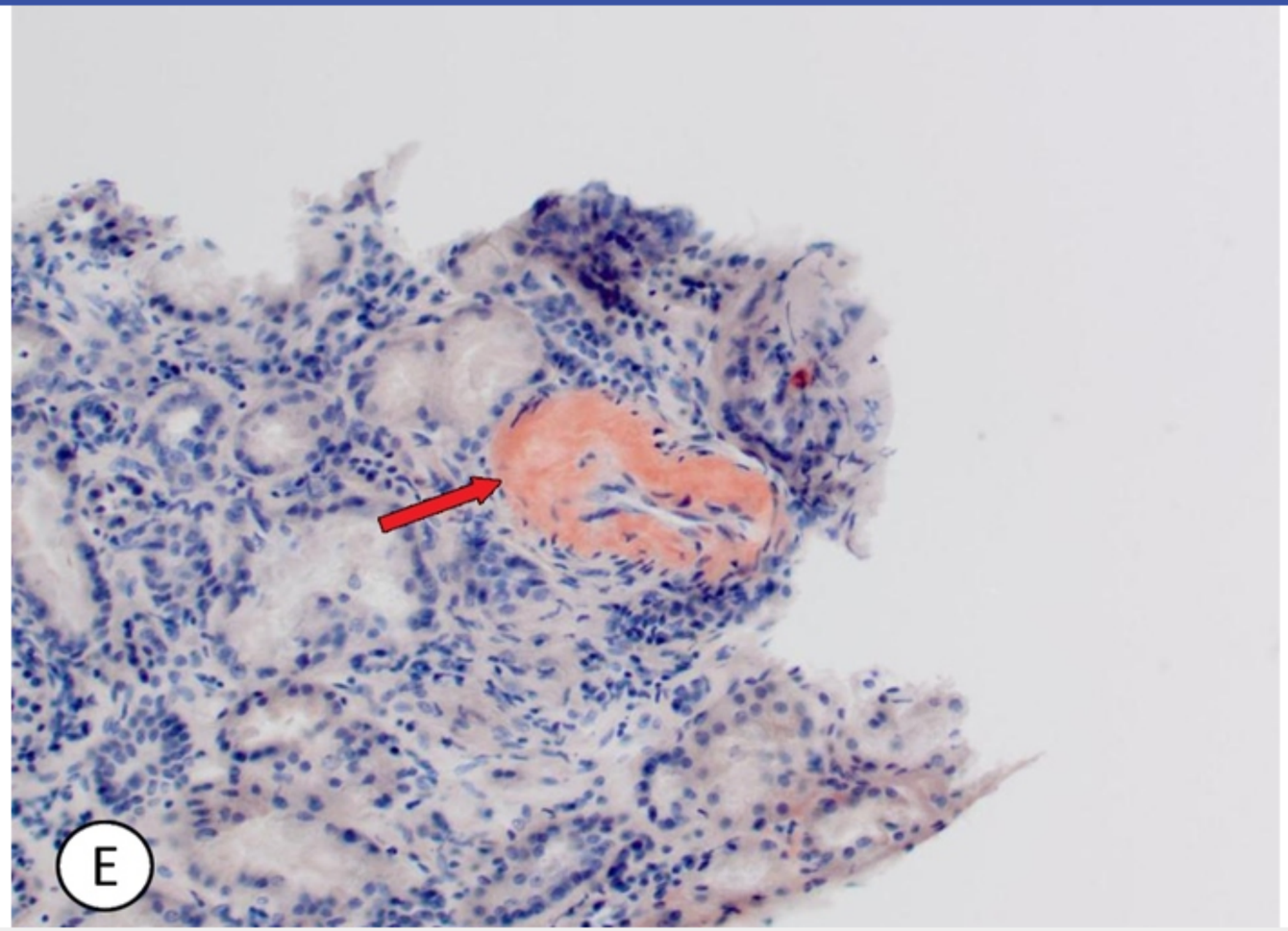

Zoom In | Zoom Out | Reset | Add To New Card | Existing Card

Histology | Renal, Urinary Systems & Electrolytes | Anti GBM disease

component of the GBM, leading to subsequent complement deposition. This results in a form of **rapidly progressive (crescentic)**

Exhibit Display

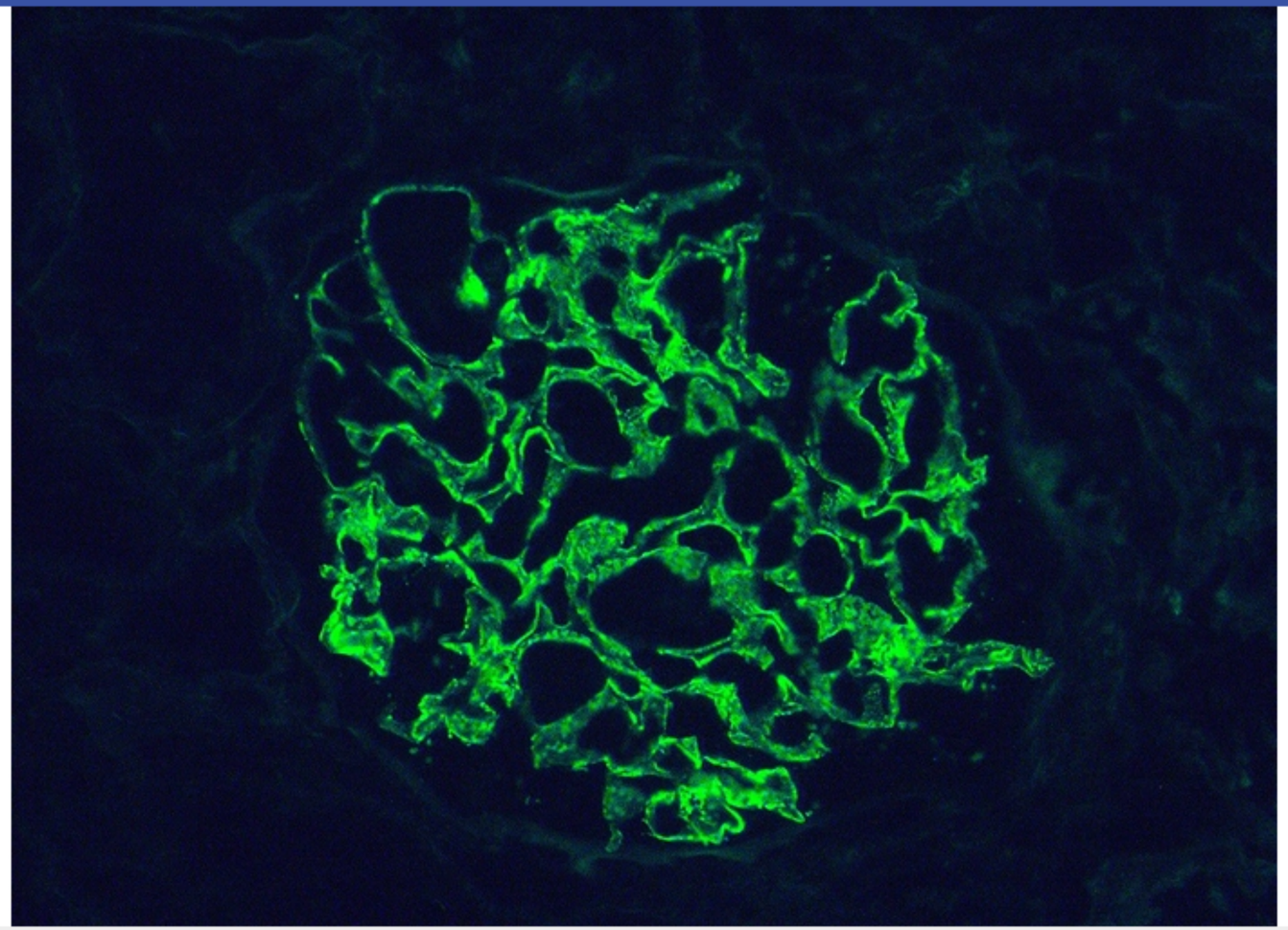

Zoom In | Zoom Out | Reset | Add To New Card | Existing Card

Histology | Renal, Urinary Systems & Electrolytes | Anti GBM disease

component of the GBM, leading to subsequent complement deposition. This results in a form of **rapidly progressive (crescentic)**

Exhibit Display

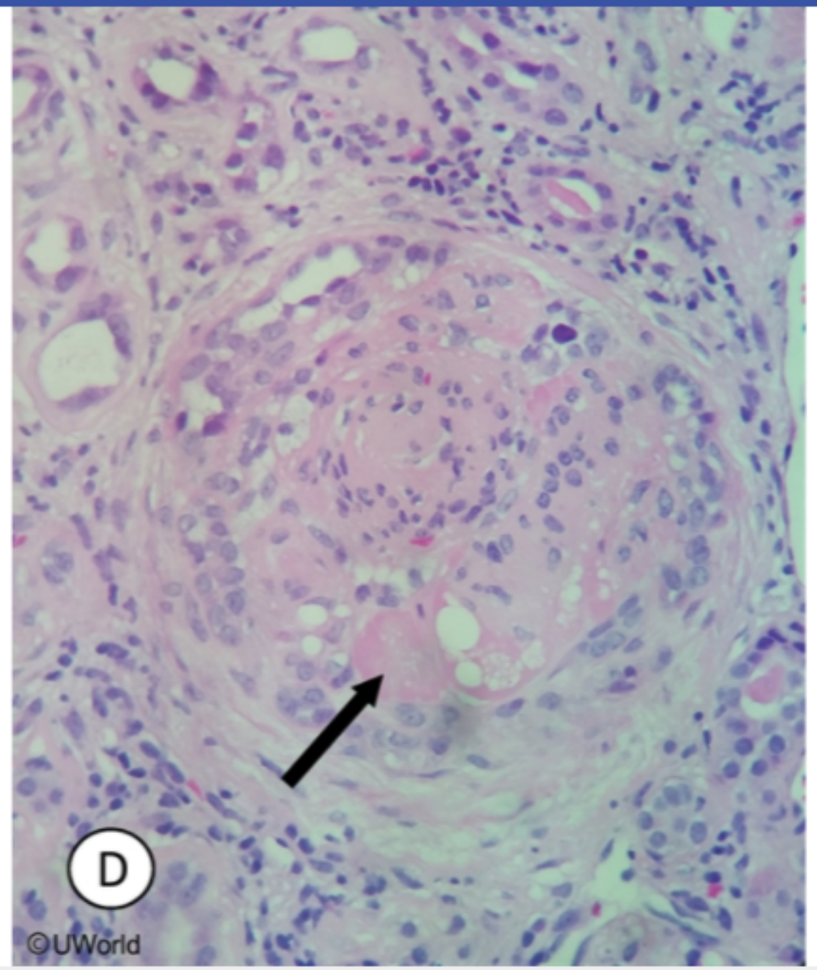

Zoom In | Zoom Out | Reset | Add To New Card | Existing Card

Histology | Renal, Urinary Systems & Electrolytes | Anti GBM disease

A 3-year-old girl is brought to her pediatrician for a well child checkup. She has met all of the appropriate developmental milestones. Her height corresponds to the 60th percentile. Osteoblasts near the growth plates of her long bones secrete matrix material, and when they become trapped in the ossified matrix, they become known as osteocytes. These osteocytes remain connected to each other by:

- A. Tight junctions
- B. Hemidesmosomes
- C. Intermediate junctions
- D. Gap junctions
- E. Desmosomes

Submit

A 3-year-old girl is brought to her pediatrician for a well child checkup. She has met all of the appropriate developmental milestones. Her height corresponds to the 60th percentile. Osteoblasts near the growth plates of her long bones secrete matrix material, and when they become trapped in the ossified matrix, they become known as osteocytes. These osteocytes remain connected to each other by:

- A. Tight junctions (16%)
- B. Hemidesmosomes (5%)
- C. Intermediate junctions (14%)
- ✓ D. Gap junctions (46%)
- E. Desmosomes (16%)

Omitted
Correct answer
D

46%
Answered correctly

02 secs
Time Spent

03/23/2020
Last Updated

Explanation

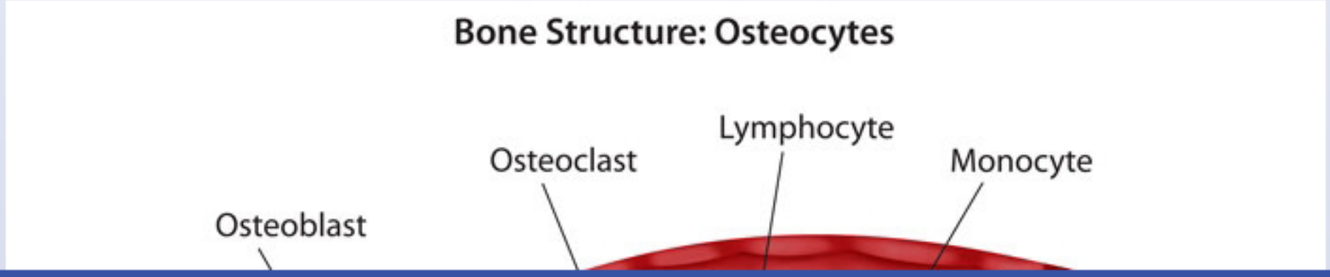

Settings

1
2
3
4
5
6
7
8
9
10
11
12
13
14
15
16
17
18
19
20
21
22
23
24
25
26

Item 13 of 26
Question Id: 1159

Mark

Previous Next Full Screen Tutorial Lab Values Notes Calculator Reverse Color Text Zoom Settings

Bone Structure: Osteocytes

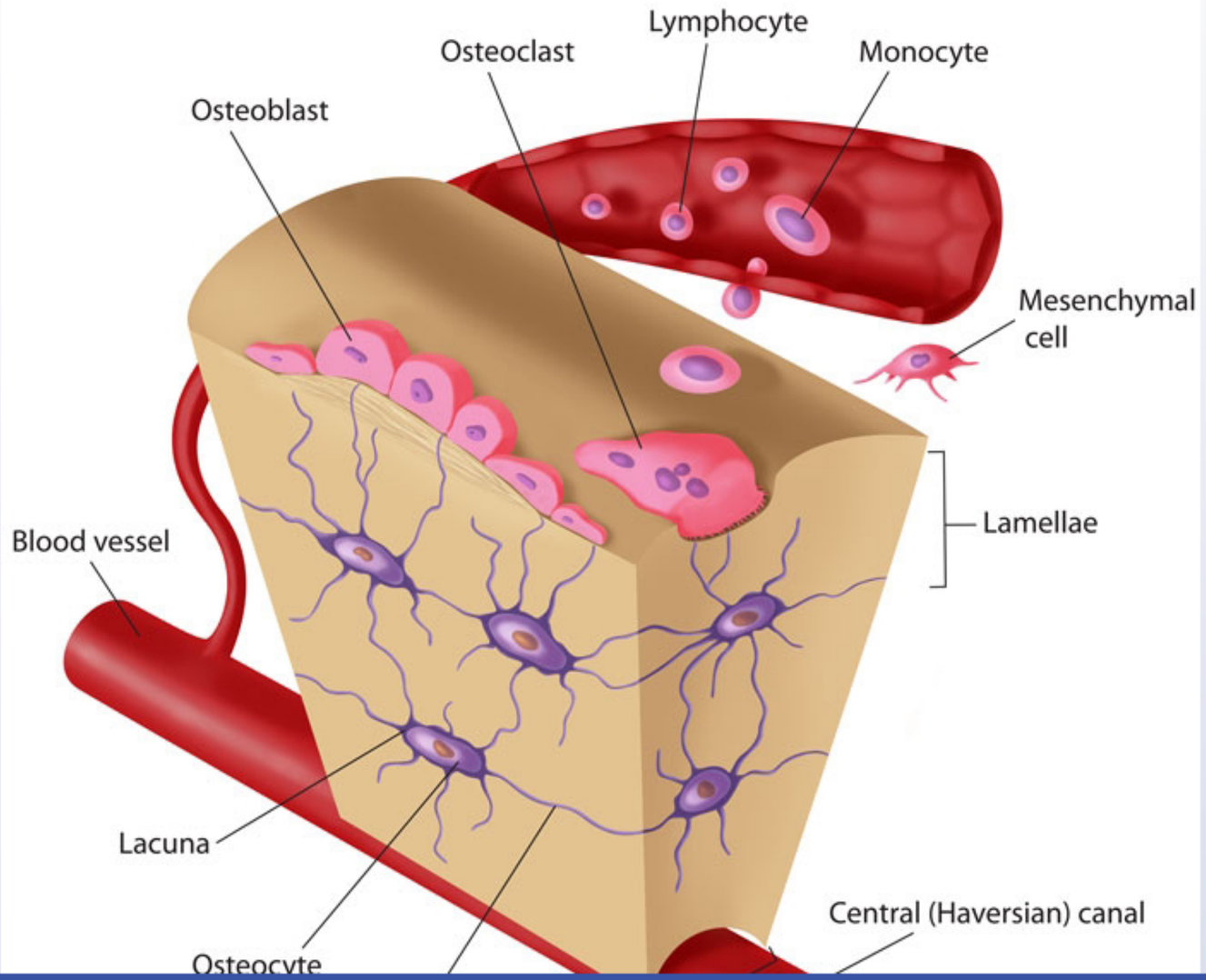

Block Time Remaining: 00:01:34
TUTOR

3 Feedback Suspend End Block

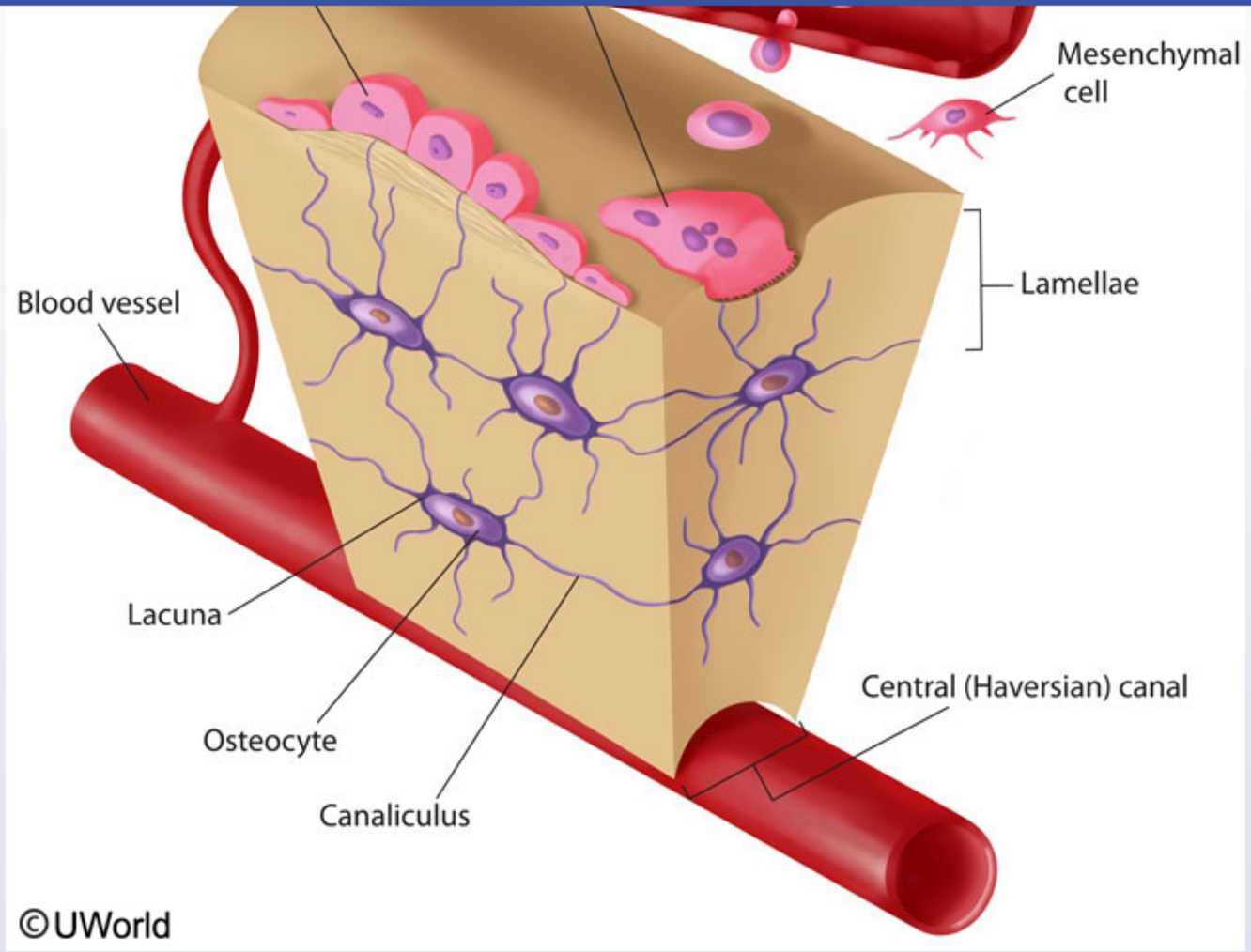

Within a single Haversian system, the central canal is encircled by multiple concentric lamellae of bony matrix that each contains lacunae filled with osteocytes and extracellular bone fluid. Delicate canaliculi radiate from each lacuna to create a reticular network with adjacent lacunae, and the cytoplasmic processes of the osteocytes lie within these canaliculi. These cytoplasmic processes send signals to and exchange nutrients and

Within a single Haversian system, the central canal is encircled by multiple concentric lamellae of bony matrix that each contains lacunae filled with osteocytes and extracellular bone fluid. Delicate canaliculi radiate from each lacuna to create a reticular network with adjacent lacunae, and the cytoplasmic processes of the osteocytes lie within these canaliculi. These cytoplasmic processes send signals to and exchange nutrients and waste products with the osteocytes within neighboring lamellae via gap junctions.

The osteocytes serve to maintain the structure of the mineralized matrix and control the short-term release and deposition of calcium (i.e., calcium homeostasis). The plasma calcium concentration directly dictates the metabolic activity of osteocytes, while parathyroid hormone and calcitonin indirectly influence their metabolic activity. Osteocytes can also sense mechanical stresses and send signals to modulate the activity of surface osteoblasts, thereby helping to regulate bony remodeling.

(Choice A) Tight junctions (zonula occludens) are observed at the apices of glandular cells and consist of two closely adherent cytoplasmic membranes without an intervening space. Tight junctions are the first component of the junctional complex.

(Choice B) Hemidesmosomes are half desmosomes that extend from the basal surfaces of keratinocytes in the stratified squamous epithelium to attach to the basal lamina.

(Choice C) Intermediate junctions (zonula adherens) are a delicate network of cytoplasmic filaments that radiate from the cell membrane to hold adjacent cells together. Intermediate junctions are the second component of the junctional complex.

(Choice E) Desmosomes are small, circular, adherent patches circumferentially placed around cells that comprise the third component of the junctional complex. These patches are particularly common in stratified squamous epithelium and contribute significantly to the structural cohesiveness of tissues subject to mechanical stressors.

Educational objective:
Osteocytes have long intracanalicular processes that extend through the ossified bone matrix. These cytoplasmic processes send signals to and exchange nutrients and waste products with the osteocytes within neighboring lamellae via gap junctions. Osteocytes can sense mechanical stresses and send signals to modulate the activity of surface osteoblasts, thereby helping to regulate bony remodeling.

Histology | Rheumatology/Orthopedics & Sports | Bone remodeling

A 14-month-old girl is brought to the office due to a 2-month history of diarrhea. Her parents report that she has 3-5 loose, nonbloody bowel movements daily with occasional episodes of vomiting. She was breastfed exclusively until age 9 months and has since had a well-varied diet including whole milk, fruits, vegetables, bread, and meats. However, the girl has been less interested in food over the past several weeks. There is no history of travel or contacts with similar symptoms. On physical examination, the patient appears well but has lost 1.1 kg (2.5 lb) in the last 2 months. After laboratory evaluation, duodenal biopsy findings are shown in the exhibit. Which of the following would most likely improve this patient's symptoms?

A. Acid reduction therapy

B. Anti-inflammatory medications

C. Antibiotic therapy

D. Enzyme supplementation

E. Modified dairy diet

F. Modified grain diet

Submit

Settings

1
2
3
4
5
6
7
8
9
10
11
12
13
14
15
16
17
18
19
20
21
22
23
24
25
26

Item 14 of 26
Question Id: 324

Mark | Previous | Next | Full Screen | Tutorial | Lab Values | Notes | Calculator | Reverse Color | Text Zoom | Settings

Exhibit Display

Exhibit 1 Exhibit 2

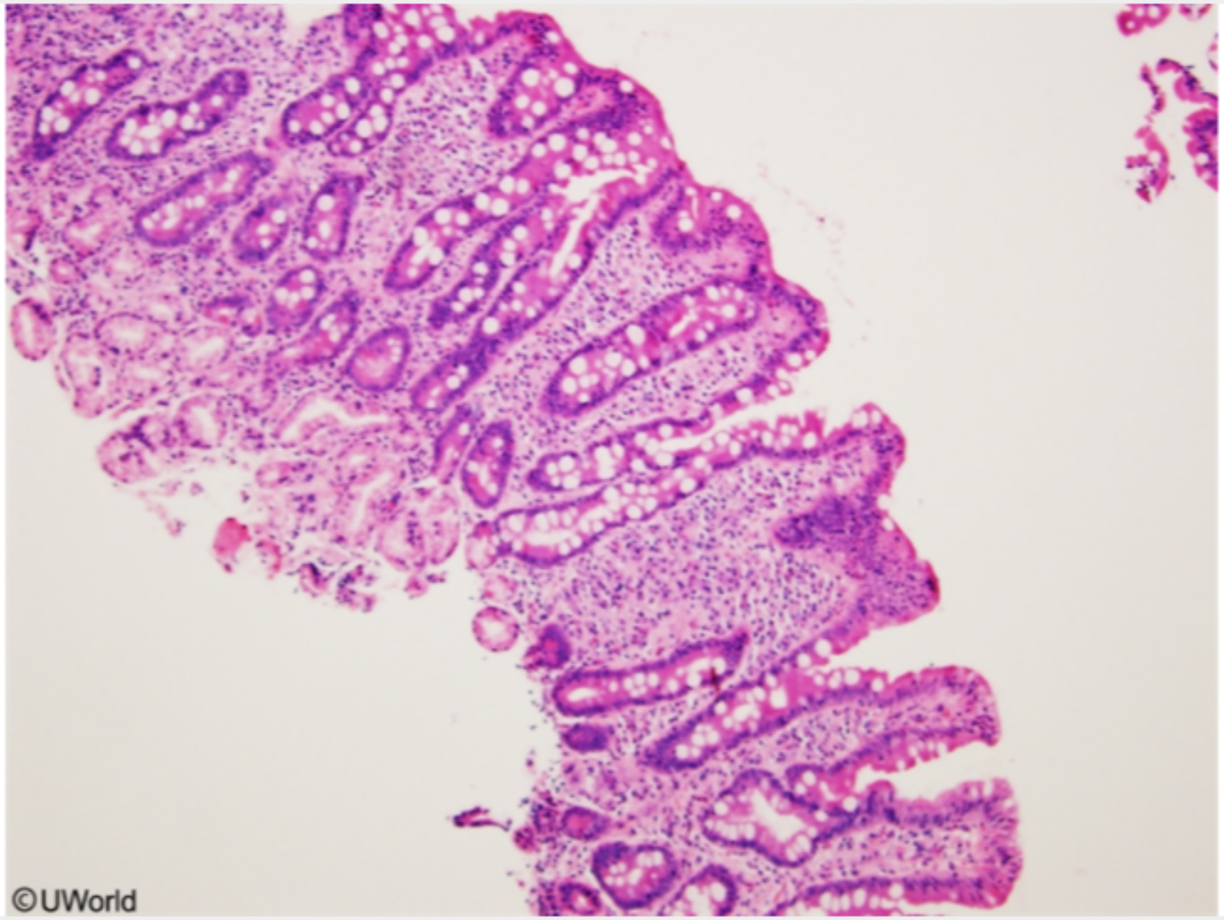

Zoom In | Zoom Out | Reset | Add To New Card | Existing Card

Block Time Remaining: 00:01:38
TUTOR

5 | Feedback | Suspend | End Block

Settings

1
2
3
4
5
6
7
8
9
10
11
12
13
14
15
16
17
18
19
20
21
22
23
24
25
26

Item 14 of 26
Question Id: 324

Mark | Previous | Next | Full Screen | Tutorial | Lab Values | Notes | Calculator | Reverse Color | Text Zoom | Settings

Exhibit Display

Exhibit 1 Exhibit 2

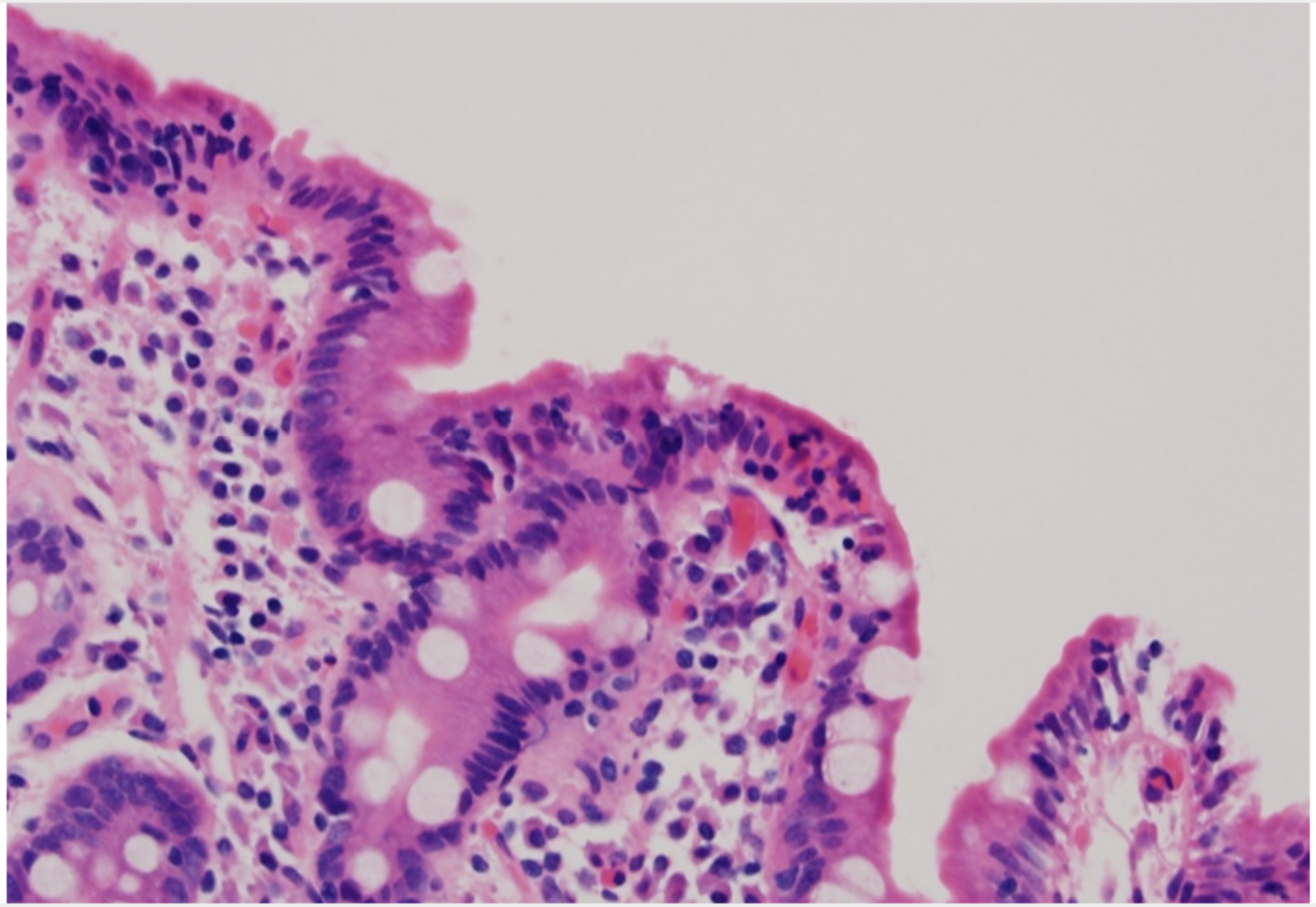

Zoom In | Zoom Out | Reset | Add To New Card | Existing Card

Block Time Remaining: 00:01:41
TUTOR

5 | Feedback | Suspend | End Block

A 14-month-old girl is brought to the office due to a 2-month history of diarrhea. Her parents report that she has 3-5 loose, nonbloody bowel movements daily with occasional episodes of vomiting. She was breastfed exclusively until age 9 months and has since had a well-varied diet including whole milk, fruits, vegetables, bread, and meats. However, the girl has been less interested in food over the past several weeks. There is no history of travel or contacts with similar symptoms. On physical examination, the patient appears well but has lost 1.1 kg (2.5 lb) in the last 2 months. After laboratory evaluation, duodenal biopsy findings are shown in the exhibit. Which of the following would most likely improve this patient's symptoms?

A. Acid reduction therapy (2%)

B. Anti-inflammatory medications (3%)

C. Antibiotic therapy (5%)

D. Enzyme supplementation (6%)

E. Modified dairy diet (8%)

✓ F. Modified grain diet (74%)

Omitted
Correct answer
F

74%
Answered correctly

10 secs
Time Spent

03/16/2020
Last Updated

Explanation



Explanation

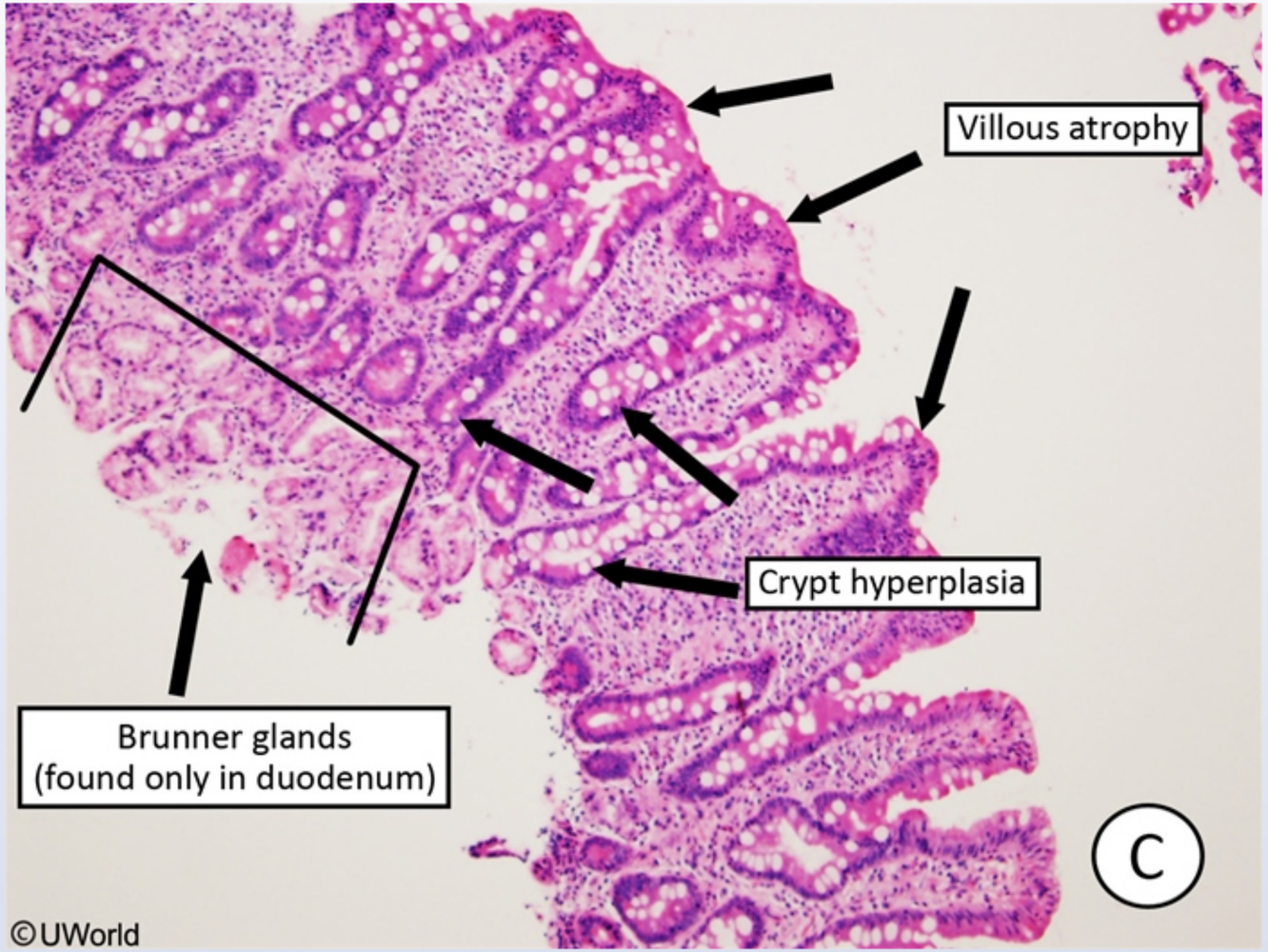

Celiac disease is a chronic malabsorptive disorder caused by a **hypersensitivity to gluten**, a protein found in wheat, barley, and rye. Gliadin, a

Celiac disease is a chronic malabsorptive disorder caused by a **hypersensitivity to gluten**, a protein found in wheat, barley, and rye. Gliadin, a breakdown product of gluten, triggers an immune-mediated reaction causing **villous atrophy, crypt hyperplasia**, and intraepithelial lymphocyte infiltration as seen in the image above. Normal intestinal villi allow for increased small intestinal surface area to begin the process of digestion and nutrient absorption. The atrophy in celiac disease causes impairment of nutrient absorption in the duodenum and proximal jejunum, regions where the concentration of gluten is the highest.

Classic celiac disease presents between age 6-24 months after the introduction of gluten into the diet and with symptoms of malabsorption (eg, diarrhea, steatorrhea, flatulence, nutrient deficiencies, weight loss). Other manifestations include delayed puberty and short stature in children and anemia in adults. Screening is with serology testing for elevated IgA anti-endomysial and anti-tissue transglutaminase antibodies; diagnosis is confirmed by endoscopic biopsy. With strict adherence to a **gluten-free diet**, symptom resolution occurs within weeks and is followed by normalization of histology and antibody levels.

(Choice A) Mild gastroesophageal reflux is physiologic in healthy infants, but it can lead to irritability, poor feeding, and inadequate weight gain when severe. The diagnosis is often made clinically and can be treated with conservative changes (eg, smaller feedings) and acid suppression (eg, proton pump inhibitor). Refractory cases may require biopsy, which shows esophageal inflammation.

(Choice B) Anti-inflammatory medications (eg, glucocorticoids, aminosalicylates) are the mainstay of treatment for inflammatory bowel disease (ulcerative colitis [UC] and Crohn disease [CD]). Symptoms include abdominal pain, bloody diarrhea, and weight loss. Colonoscopy may show diffuse colonic inflammation in UC and focal areas of small intestinal and colonic inflammation in CD.

(Choice C) Tropical sprue can occur with extended travel to the tropics and presents with chronic diarrhea, abdominal pain, and flatulence along with similar histologic findings to celiac disease (eg, villous atrophy). The etiology is likely infectious, and the disease is treated with antibiotics. This patient has no history of travel.

(Choices D and E) Lactase supplementation or limited lactose intake is recommended for patients with lactose intolerance, which classically presents in older children and adults with bloating, flatulence, abdominal discomfort, and diarrhea. Although biopsy is not indicated for diagnosis, histology would show normal small intestinal architecture with decreased lactase activity.

Educational objective:

Settings

1
2
3
4
5
6
7
8
9
10
11
12
13
14
15
16
17
18
19
20
21
22
23
24
25
26

Item 14 of 26
Question Id: 324

Mark | Previous | Next | Full Screen | Tutorial | Lab Values | Notes | Calculator | Reverse Color | Text Zoom | Settings

Exhibit Display

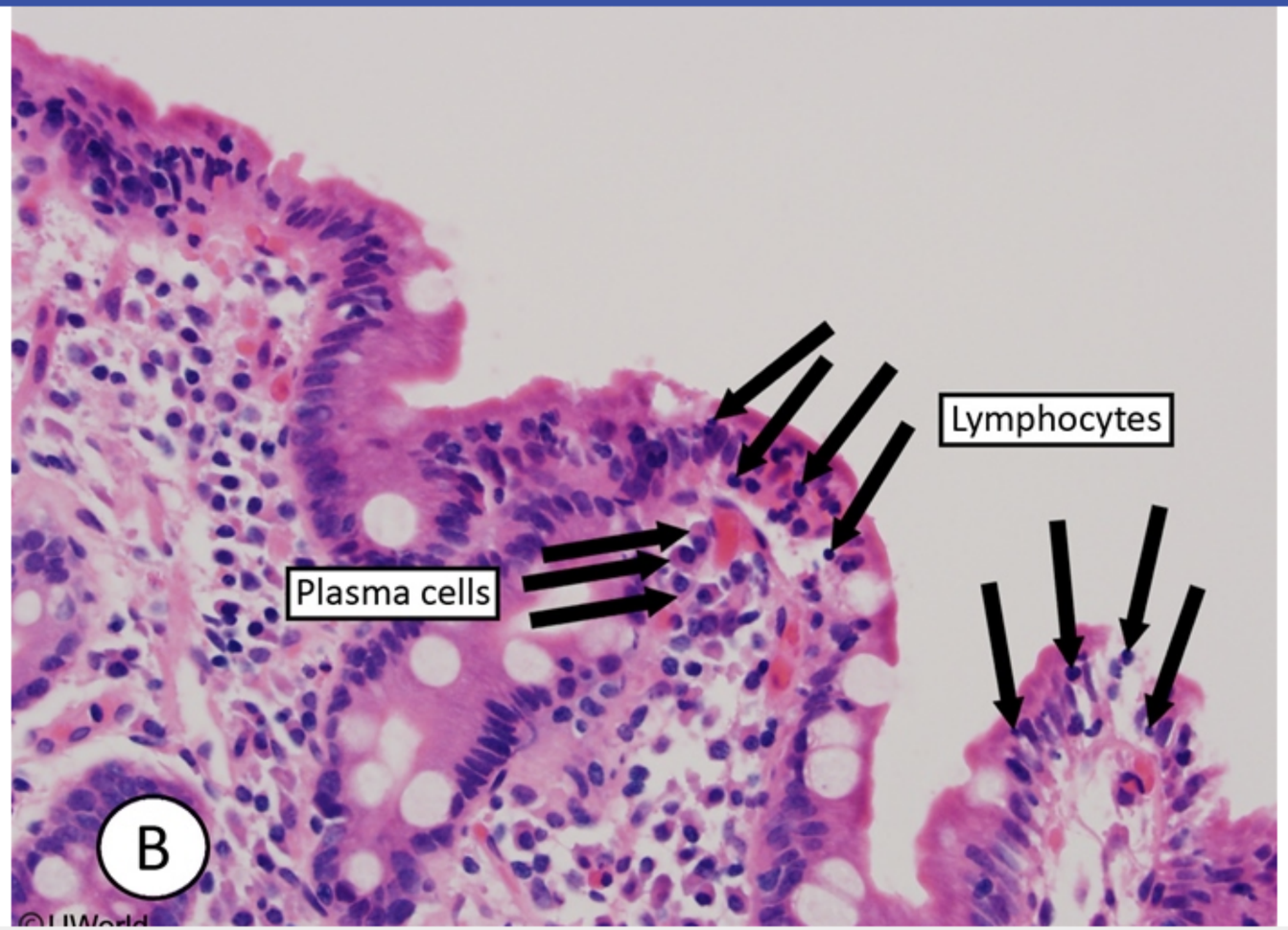

Zoom In | Zoom Out | Reset | Add To New Card | Existing Card

Educational objective:

Block Time Remaining: 00:01:44
TUTOR

5 | Feedback | Suspend | End Block

Settings

1 2 3 4 5 6 7 8 9 10 11 12 13 14 15 16 17 18 19 20 21 22 23 24 25 26

Item 14 of 26
Question Id: 324

Mark | Previous | Next | Full Screen | Tutorial | Lab Values | Notes | Calculator | Reverse Color | Text Zoom | Settings

©UWorld

Exhibit Display

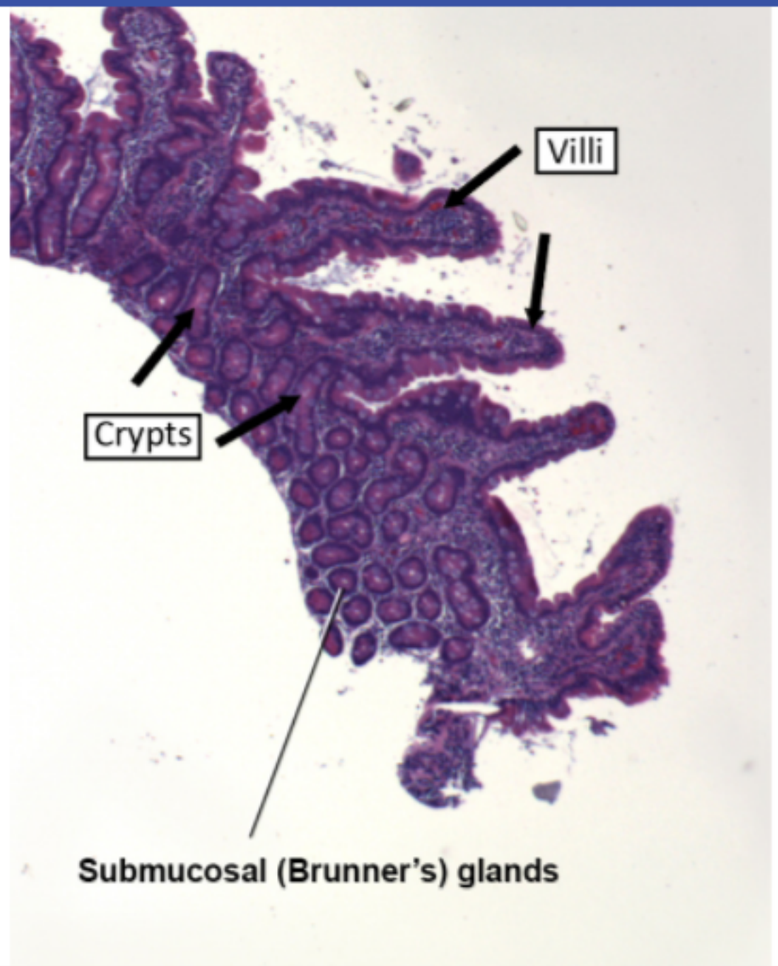

Zoom In | Zoom Out | Reset | Add To New Card | Existing Card

Educational objective:

Block Time Remaining: 00:01:44
TUTOR

5 | Feedback | Suspend | End Block

(Choice A) Mild gastroesophageal reflux is physiologic in healthy infants, but it can lead to irritability, poor feeding, and inadequate weight gain when severe. The diagnosis is often made clinically and can be treated with conservative changes (eg, smaller feedings) and acid suppression (eg, proton pump inhibitor). Refractory cases may require biopsy, which shows esophageal inflammation.

(Choice B) Anti-inflammatory medications (eg, glucocorticoids, aminosalicylates) are the mainstay of treatment for inflammatory bowel disease (ulcerative colitis [UC] and Crohn disease [CD]). Symptoms include abdominal pain, bloody diarrhea, and weight loss. Colonoscopy may show diffuse colonic inflammation in UC and focal areas of small intestinal and colonic inflammation in CD.

(Choice C) Tropical sprue can occur with extended travel to the tropics and presents with chronic diarrhea, abdominal pain, and flatulence along with similar histologic findings to celiac disease (eg, villous atrophy). The etiology is likely infectious, and the disease is treated with antibiotics. This patient has no history of travel.

(Choices D and E) Lactase supplementation or limited lactose intake is recommended for patients with lactose intolerance, which classically presents in older children and adults with bloating, flatulence, abdominal discomfort, and diarrhea. Although biopsy is not indicated for diagnosis, histology would show normal small intestinal architecture with decreased lactase activity.

Educational objective:
Celiac disease (gluten-sensitive enteropathy) classically presents between age 6-24 months with abdominal pain, diarrhea, vomiting, and weight loss. Duodenal biopsy reveals crypt hyperplasia, villous atrophy, and intraepithelial lymphocyte infiltration. Treatment with a gluten-free diet resolves symptoms and normalizes serology and histology.

References

- Celiac disease and the gluten-free diet: consequences and recommendations for improvement.
- Treatment of celiac disease: from gluten-free to novel therapies.
- Pathology of celiac disease: a brief review.

Histology	Gastrointestinal & Nutrition	Celiac disease
Subject	System	Topic

A 64-year-old man is brought to the emergency department due to worsening shortness of breath. The patient is able to speak in short sentences only and becomes hypoxemic with minimal exertion. His medical history includes hypertension and dyslipidemia. He smoked a pack of cigarettes a day for 40 years and worked for 25 years as a nickel miner. His father died of chronic respiratory failure. While in the emergency department, he rapidly develops respiratory failure and is intubated. Despite appropriate treatment, he dies several days later in the intensive care unit. Autopsy is performed, and examination of the bronchi reveals thickened bronchial walls, inflammatory infiltrates, mucous gland enlargement, and patchy squamous metaplasia of the bronchial mucosa. Which of the following factors was likely the greatest contributor to this patient's pathological findings?

- A. Allergic
- B. Behavioral
- C. Genetic
- D. Infectious
- E. Neoplastic
- F. Occupational

Submit

A 64-year-old man is brought to the emergency department due to worsening shortness of breath. The patient is able to speak in short sentences only and becomes hypoxemic with minimal exertion. His medical history includes hypertension and dyslipidemia. He smoked a pack of cigarettes a day for 40 years and worked for 25 years as a nickel miner. His father died of chronic respiratory failure. While in the emergency department, he rapidly develops respiratory failure and is intubated. Despite appropriate treatment, he dies several days later in the intensive care unit. Autopsy is performed, and examination of the bronchi reveals thickened bronchial walls, inflammatory infiltrates, mucous gland enlargement, and patchy squamous metaplasia of the bronchial mucosa. Which of the following factors was likely the greatest contributor to this patient's pathological findings?

- A. Allergic (1%)
- ✓ B. Behavioral (65%)
- C. Genetic (2%)
- D. Infectious (1%)
- E. Neoplastic (4%)
- F. Occupational (25%)

Omitted
Correct answer
B

65%
Answered correctly

02 secs
Time Spent

02/14/2020
Last Updated

Explanation

This patient with respiratory failure, hypoxemia, and thickened bronchial walls with inflammatory infiltrates and mucous gland enlargement likely

Explanation

This patient with respiratory failure, hypoxemia, and thickened bronchial walls with inflammatory infiltrates and mucous gland enlargement likely had **chronic bronchitis**. Chronic bronchitis is characterized by chronic, productive cough with airflow limitation and is part of the spectrum of chronic obstructive pulmonary disease. It is most commonly caused by **tobacco smoking**. Chronic irritation by other inhaled environmental substances, such as air pollutants and grain, cotton, or silica dusts, can also contribute to its development. Biopsy typically shows **thickened bronchial walls** with predominantly **lymphocytic infiltrates**, mucous gland enlargement with increased numbers of goblet cells (**increasing mucus production**), and patchy **squamous metaplasia** of the bronchial mucosa.

(Choice A) Patients with allergic asthma can develop pathologic remodeling of the bronchial wall, which includes thickening of the bronchial epithelium, basement membrane, and bronchial smooth muscle as well as edema, inflammatory infiltrates, and submucosal mucous gland enlargement. However, the infiltrates consist predominantly of eosinophils and mast cells. In addition, although asthma is a risk factor for chronic bronchitis, smoking is a much more common cause.

(Choice C) Genetic factors are not known to strongly predispose to chronic bronchitis. Genetic mutation causing alpha-1 antitrypsin deficiency can lead to panacinar emphysema; however, chronic bronchitis is not a significant component of the disease.

(Choice D) Repeated bronchial/bronchiolar bacterial and viral infections can contribute to the development of chronic bronchitis, although less significantly than can smoking. Tobacco smoke predisposes to infection by impairing ciliary clearance and directly damaging the respiratory epithelium.

(Choices E and F) Nickel is a carcinogen, and occupational exposure is associated with nasal and lung cancers. However, neoplastic transformation itself does not contribute to the development of chronic bronchitis. Although this patient's history of nickel mining is also suggestive of silica dust exposure, smoking is the most important risk factor for chronic bronchitis.

Educational objective:
Thickened bronchial walls, lymphocytic infiltration, mucous gland enlargement, and patchy squamous metaplasia of the bronchial mucosa are features of chronic bronchitis. Tobacco smoking is the leading cause of chronic bronchitis.

References

- Pathology of chronic obstructive pulmonary disease.

This patient with respiratory failure, hypoxemia, and thickened bronchial walls with inflammatory infiltrates and mucous gland enlargement likely had **chronic bronchitis**. Chronic bronchitis is characterized by chronic, productive cough with airflow limitation and is part of the spectrum of chronic obstructive pulmonary disease. It is most commonly caused by **tobacco smoking**. Chronic irritation by other inhaled environmental substances, such as air pollutants and grain, cotton, or silica dusts, can also contribute to its development. Biopsy typically shows **thickened bronchial walls** with predominantly **lymphocytic infiltrates**, mucous gland enlargement with increased numbers of goblet cells (**increasing mucus production**), and patchy **squamous metaplasia** of the bronchial mucosa.

(Choice A) Patients with allergic asthma can develop pathologic remodeling of the bronchial wall, which includes thickening of the bronchial epithelium, basement membrane, and bronchial smooth muscle as well as edema, inflammatory infiltrates, and submucosal mucous gland enlargement. However, the infiltrates consist predominantly of eosinophils and mast cells. In addition, although asthma is a risk factor for chronic bronchitis, smoking is a much more common cause.

(Choice C) Genetic factors are not known to strongly predispose to chronic bronchitis. Genetic mutation causing alpha-1 antitrypsin deficiency can lead to panacinar emphysema; however, chronic bronchitis is not a significant component of the disease.

(Choice D) Repeated bronchial/bronchiolar bacterial and viral infections can contribute to the development of chronic bronchitis, although less significantly than can smoking. Tobacco smoke predisposes to infection by impairing ciliary clearance and directly damaging the respiratory epithelium.

(Choices E and F) Nickel is a carcinogen, and occupational exposure is associated with nasal and lung cancers. However, neoplastic transformation itself does not contribute to the development of chronic bronchitis. Although this patient's history of nickel mining is also suggestive of silica dust exposure, smoking is the most important risk factor for chronic bronchitis.

Educational objective:
Thickened bronchial walls, lymphocytic infiltration, mucous gland enlargement, and patchy squamous metaplasia of the bronchial mucosa are features of chronic bronchitis. Tobacco smoking is the leading cause of chronic bronchitis.

References

- Pathology of chronic obstructive pulmonary disease.
- New concepts in the pathobiology of chronic obstructive pulmonary disease.

Settings

1
2
3
4
5
6
7
8
9
10
11
12
13
14
15
16
17
18
19
20
21
22
23
24
25
26

Item 16 of 26
Question Id: 588

Mark | Previous | Next | Full Screen | Tutorial | Lab Values | Notes | Calculator | Reverse Color | Text Zoom | Settings

A 6mm punch biopsy of normal appearing epidermis reveals stellar cells that contain intracytoplasmic granules having the shape of a tennis racquet. These cells demonstrate some myeloid surface markers and can interact closely with T lymphocytes. The cells described above are best referred to as which of the following?

A. Kupffer cells
B. Langerhans cells
C. Merkel cells
D. Melanocytes
E. Macrophages
F. Epithelioid cells

Submit

Block Time Remaining: 00:01:46
TUTOR

2 | Feedback | Suspend | End Block

A 6mm punch biopsy of normal appearing epidermis reveals stellar cells that contain intracytoplasmic granules having the shape of a tennis racquet. These cells demonstrate some myeloid surface markers and can interact closely with T lymphocytes. The cells described above are best referred to as which of the following?

- A. Kupffer cells (4%)
- ✓ B. Langerhans cells (81%)
- C. Merkel cells (3%)
- D. Melanocytes (2%)
- E. Macrophages (4%)
- F. Epithelioid cells (2%)

Omitted
Correct answer
B

81%
Answered correctly

01 sec
Time Spent

04/06/2020
Last Updated

Explanation

Langerhans cells (not to be confused with Langhans giant cells, a type of multinucleated cell formed from macrophages) are the form of dendritic cell most commonly found in the skin and mucous membranes. Dendritic cells are professional **antigen presenting** cells that interact closely with T lymphocytes. Dendritic are the most effective form of antigen presenting cell because they constitutively express MHC Class II and the co-stimulatory B7 cell surface molecules. They also take up antigen by constant endocytosis and pinocytosis from their environment.

Langerhans cells are derived from the myeloid cell line and express **myeloid** cell surface markers. They contain characteristic "**racquet-shaped**"

Langerhans cells (not to be confused with Langhans giant cells, a type of multinucleated cell formed from macrophages) are the form of dendritic cell most commonly found in the skin and mucous membranes. Dendritic cells are professional **antigen presenting** cells that interact closely with T lymphocytes. Dendritic are the most effective form of antigen presenting cell because they constitutively express MHC Class II and the co-stimulatory B7 cell surface molecules. They also take up antigen by constant endocytosis and pinocytosis from their environment.

Langerhans cells are derived from the myeloid cell line and express **myeloid** cell surface markers. They contain characteristic "**racquet-shaped**" **intracytoplasmic granules** (Birbeck granules) that are only visible on electron microscopy.

(Choice A) Kupffer cells are macrophage-derived cells present in the liver that compose part of the reticuloendothelial system. Kupffer cells lie within the hepatic sinusoids and, like any other macrophage, serve a phagocytic role in the liver.

(Choice C) Merkel cells are neuroendocrine cells of the basal layer of the epidermis, often found in association with nerve projections, that play a role in perception of touch. They are associated with a rare but highly malignant form of skin cancer known as Merkel cell carcinoma.

(Choice D) Melanocytes are pigment producing cells of the epidermis that arise from the neural crest cells and migrate to the basal layer of the epidermis during embryogenesis. They possess dendritic processes that intercalate between the remaining cells of the epidermis and facilitate the delivery of pigment-laden melanosomes from the melanocyte to the keratinocytes.

(Choices E and F) Macrophages can be found in the skin, possess myeloid cell surface markers, and when stimulated, are able to produce dendrite-like extensions of their cytoplasm. Macrophages can also differentiate into multinucleated (Langhans) giant cells and epithelioid cells in the setting of granulomatous inflammation. However, monocytes and their derivatives do not produce Birbeck granules.

Educational Objective:
Langerhans cells are dendritic cells found in the skin that act as professional antigen presenting cells. These cells are derived from the myeloid cell line and they possess characteristic racquet-shaped intracytoplasmic granules known as Birbeck granules.

Histology	Dermatology	Histiocytosis
Subject	System	Topic

Copyright © UWorld. All rights reserved.

Physicians involved in regenerative medicine research conduct a series of animal experiments to determine pulmonary tissue regeneration capacity. During one of the experiments, lung alveoli are exposed to NO_2 and massive necrosis of the epithelial lining ensues. Histologic examination of the injured tissues a month later shows partial recovery of the alveolar epithelial lining. This regenerated tissue is most likely derived from which of the following cell types?

- A. Alveolar macrophages
- B. Ciliated epithelium
- C. Club cells
- D. Goblet cells
- E. Type I pneumocytes
- F. Type II pneumocytes

Submit

Physicians involved in regenerative medicine research conduct a series of animal experiments to determine pulmonary tissue regeneration capacity. During one of the experiments, lung alveoli are exposed to NO_2 and massive necrosis of the epithelial lining ensues. Histologic examination of the injured tissues a month later shows partial recovery of the alveolar epithelial lining. This regenerated tissue is most likely derived from which of the following cell types?

- A. Alveolar macrophages (1%)
- B. Ciliated epithelium (1%)
- C. Club cells (3%)
- D. Goblet cells (0%)
- E. Type I pneumocytes (18%)
- ✓ F. Type II pneumocytes (74%)

Omitted
Correct answer
F

74%
Answered correctly

02 secs
Time Spent

02/22/2020
Last Updated

Explanation

Settings

1
2
3
4
5
6
7
8
9
10
11
12
13
14
15
16
17
18
19
20
21
22
23
24
25
26

Item 17 of 26
Question Id: 478

Mark | Previous | Next | Full Screen | Tutorial | Lab Values | Notes | Calculator | Reverse Color | Text Zoom | Settings

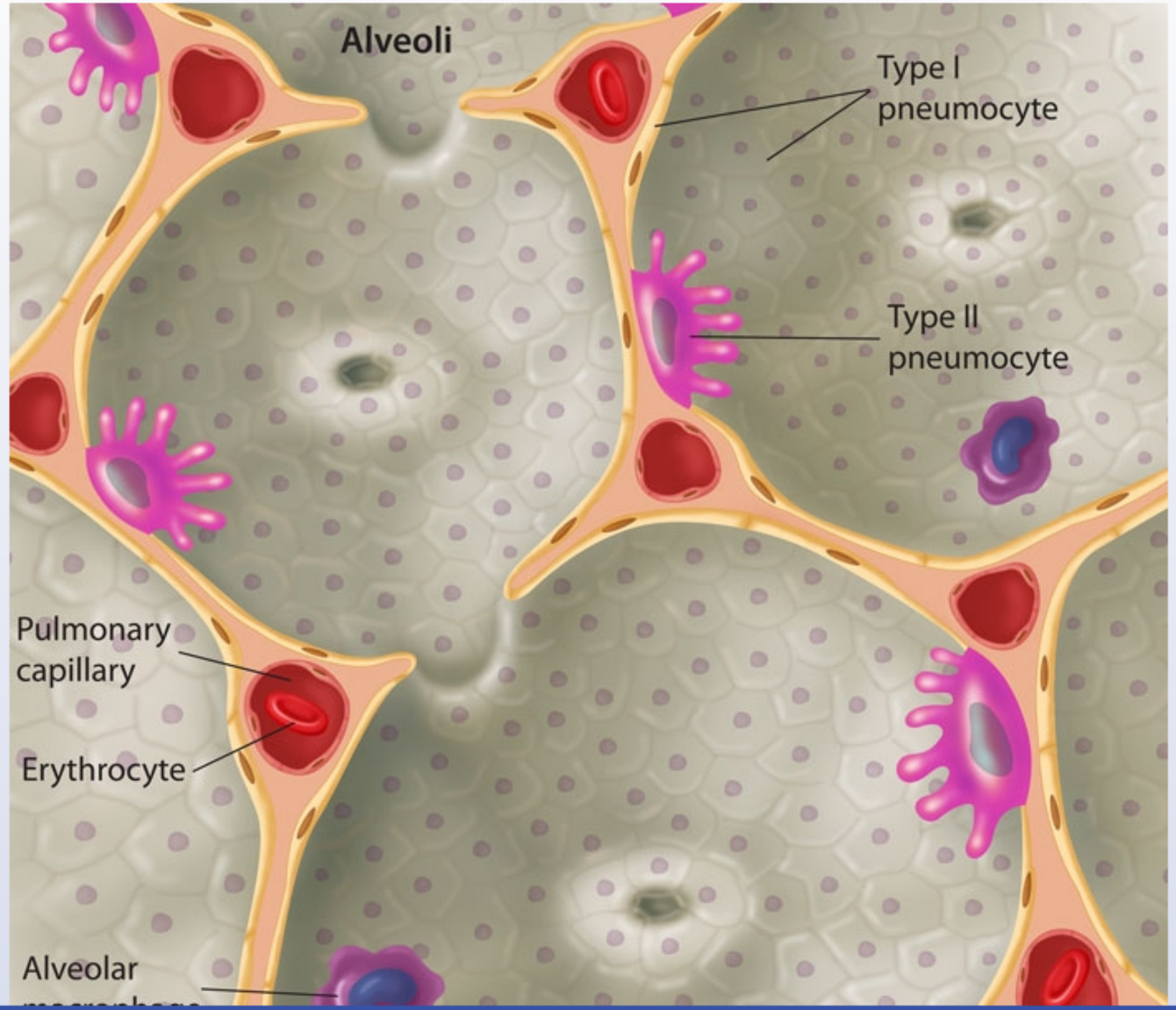

Block Time Remaining: 00:01:49
TUTOR

Feedback | Suspend | End Block

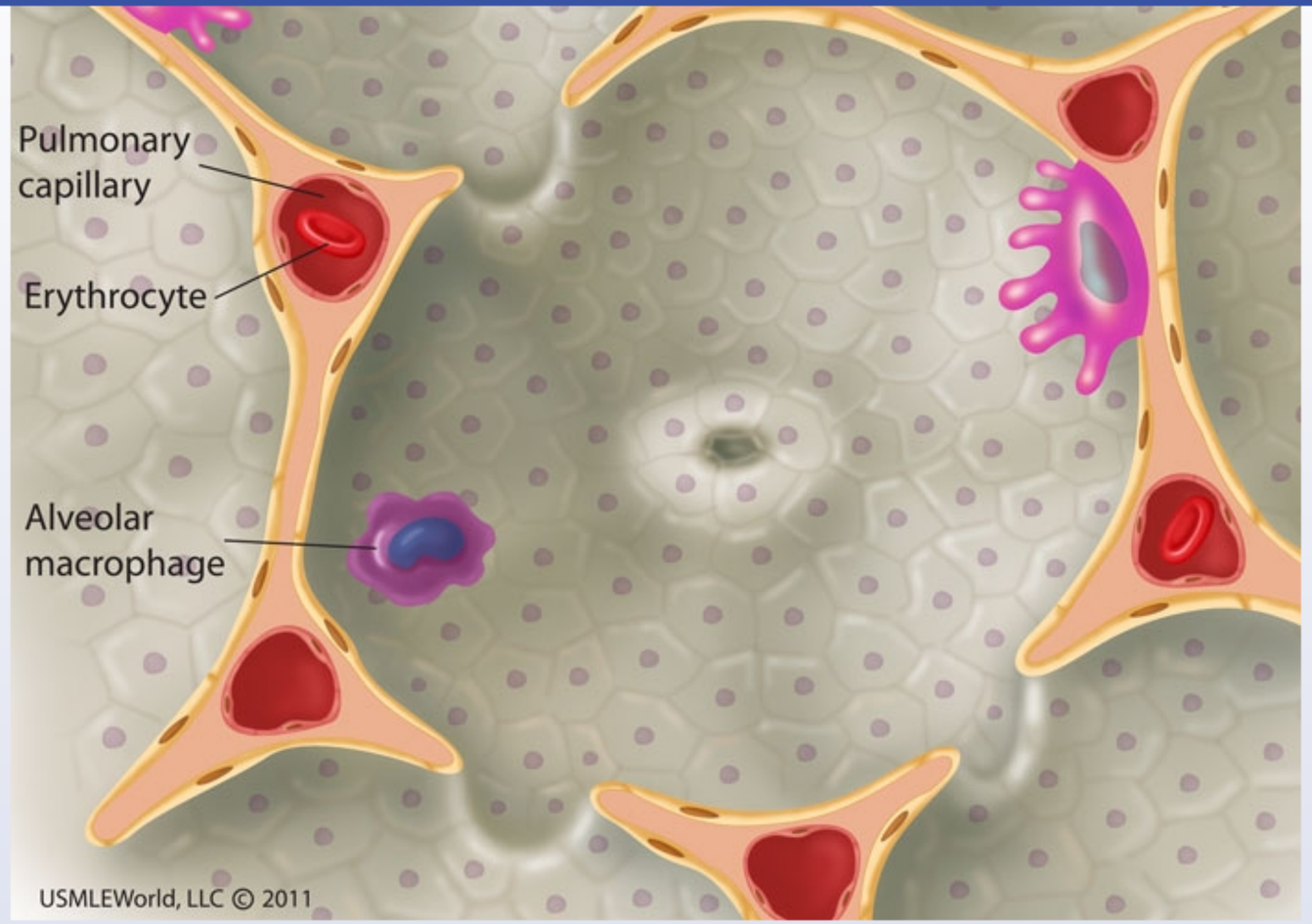

Ninety-five percent of the alveolar surface is covered by flat type I pneumocytes. The remaining 5% is covered by interspersed cuboidal **type II pneumocytes** that make up more than half of the total number of alveolar cells. Type II pneumocytes are the source of **pulmonary surfactant** and have the ability to **proliferate** in response to injury. They also act as progenitor cells for type I pneumocytes, which cannot regenerate on their own **(Choice E)**.

(Choice A) Alveolar macrophages are a self-maintaining population derived from fetal monocytes during lung development. They are the

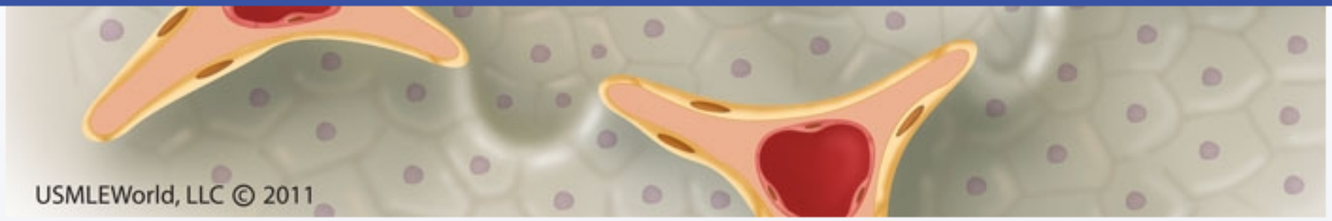

Ninety-five percent of the alveolar surface is covered by flat type I pneumocytes. The remaining 5% is covered by interspersed cuboidal **type II pneumocytes** that make up more than half of the total number of alveolar cells. Type II pneumocytes are the source of **pulmonary surfactant** and have the ability to **proliferate** in response to injury. They also act as progenitor cells for type I pneumocytes, which cannot regenerate on their own **(Choice E)**.

(Choice A) Alveolar macrophages are a self-maintaining population derived from fetal monocytes during lung development. They are the principal cells involved in clearing inhaled foreign particles from the terminal respiratory units.

(Choice B) The pseudostratified, ciliated, columnar epithelium of the tracheobronchial tree gradually tapers to become a simple ciliated cuboidal epithelium at the level of the terminal bronchioles. Ciliated cells are absent from the lining of alveolar ducts and alveolar sacs.

(Choice C) Club cells are nonciliated, secretory cells found predominantly in the terminal portions of the bronchioles. These cells can act as a regenerative source of ciliated cells in the bronchioles.

(Choice D) Goblet cells are found in the respiratory epithelium of the bronchi and larger bronchioles; they are absent from the alveolar mucosa. Goblet cells are considered terminally-differentiated, mucin-producing cells.

Educational objective:
Type II pneumocytes have 2 important functions: regeneration of the alveolar lining following injury and surfactant production.

Histology	Pulmonary & Critical Care	Respiratory mucosa
Subject	System	Topic

Copyright © UWorld. All rights reserved.

Settings

1
2
3
4
5
6
7
8
9
10
11
12
13
14
15
16
17
18
19
20
21
22
23
24
25
26

Item 18 of 26
Question Id: 124

Mark | Previous | Next | Full Screen | Tutorial | Lab Values | Notes | Calculator | Reverse Color | Text Zoom | Settings

A 65-year-old woman comes to the emergency department with progressive fatigue and lower-extremity paresthesias. Medical history is otherwise insignificant and the patient takes no medications. Laboratory studies show a mean corpuscular volume of 112 fL. Upper gastrointestinal endoscopy shows atrophic mucosa in the gastric body and fundus and a normal-appearing antrum. Destruction of which of the following gastric layers is most likely responsible for this patient's symptoms?

A. A
B. B
C. C
D. D
E. E

Submit

Block Time Remaining: 00:01:49
TUTOR

4 | Feedback | Suspend | End Block

A 65-year-old woman comes to the emergency department with progressive fatigue and lower-extremity paresthesias. Medical history is otherwise insignificant and the patient takes no medications. Laboratory studies show a mean corpuscular volume of 112 fL. Upper gastrointestinal endoscopy shows atrophic mucosa in the gastric body and fundus and a normal-appearing antrum. Destruction of which of the following gastric layers is most likely responsible for this patient's symptoms?

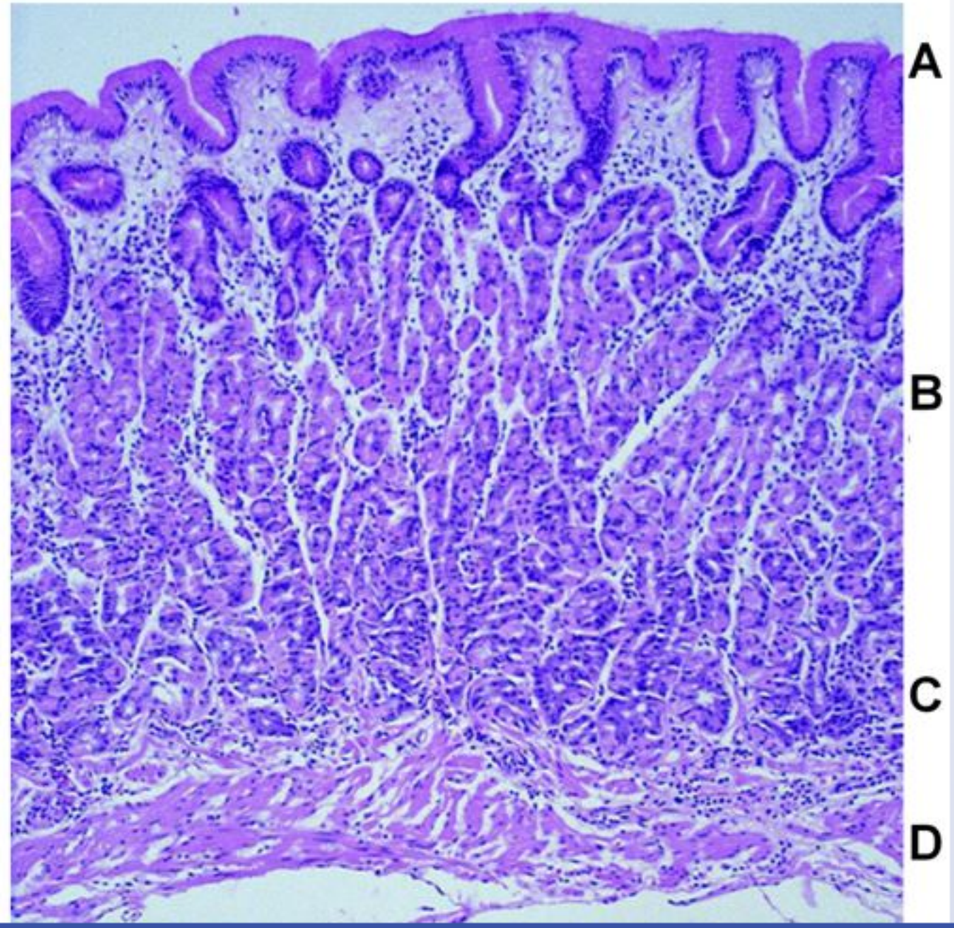

Settings

1
2
3
4
5
6
7
8
9
10
11
12
13
14
15
16
17
18
19
20
21
22
23
24
25
26

Item 18 of 26
Question Id: 124

Mark

Previous Next Full Screen Tutorial Lab Values Notes Calculator Reverse Color Text Zoom Settings

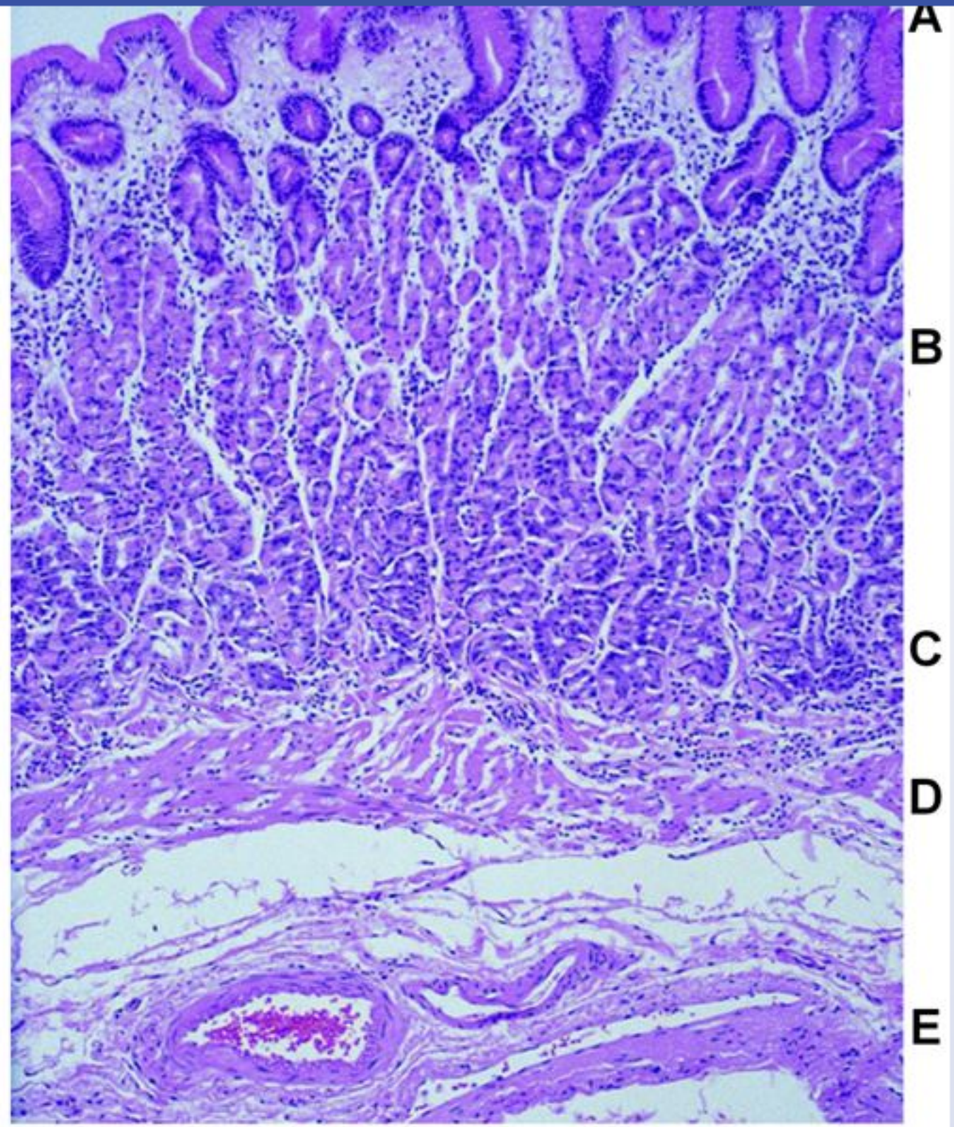

Displayed with permission from Springer Healthcare Ltd. © Copyright 1996 by Current Medicine

Block Time Remaining: 00:01:55
TUTOR

4 Feedback Suspend End Block

Settings

1
2
3
4
5
6
7
8
9
10
11
12
13
14
15
16
17
18
19
20
21
22
23
24
25
26

Item 18 of 26
Question Id: 124

Mark | Previous | Next | Full Screen | Tutorial | Lab Values | Notes | Calculator | Reverse Color | Text Zoom | Settings

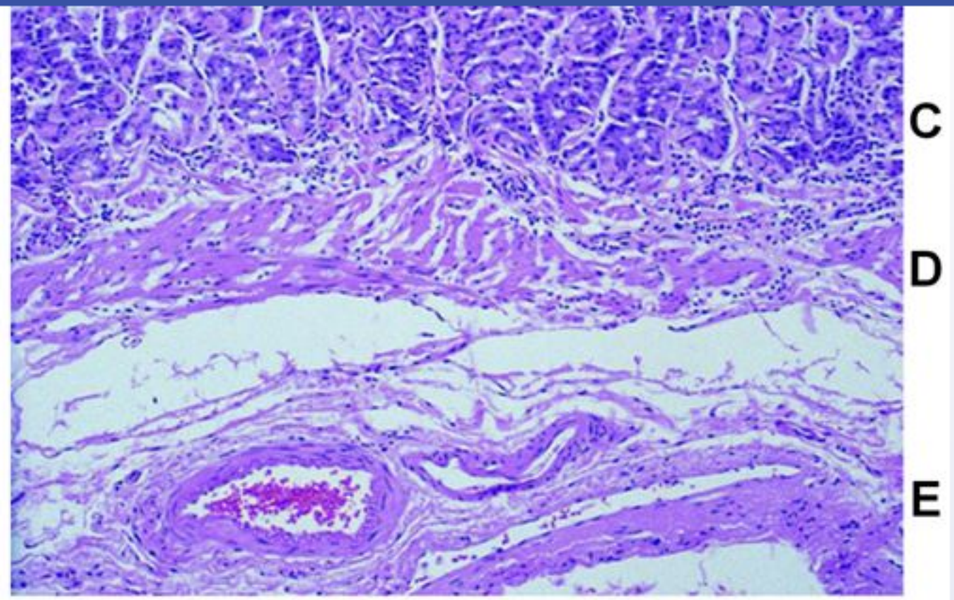

Displayed with permission from Springer Healthcare Ltd. © Copyright 1996 by Current Medicine

A. A
B. B
C. C
D. D
E. E

Submit

Block Time Remaining: 00:01:56
TUTOR

4 | Feedback | Suspend | End Block

Settings

1 2 3 4 5 6 7 8 9 10 11 12 13 14 15 16 17 18 19 20 21 22 23 24 25 26

Item 18 of 26
Question Id: 124

Mark | Previous | Next | Full Screen | Tutorial | Lab Values | Notes | Calculator | Reverse Color | Text Zoom | Settings

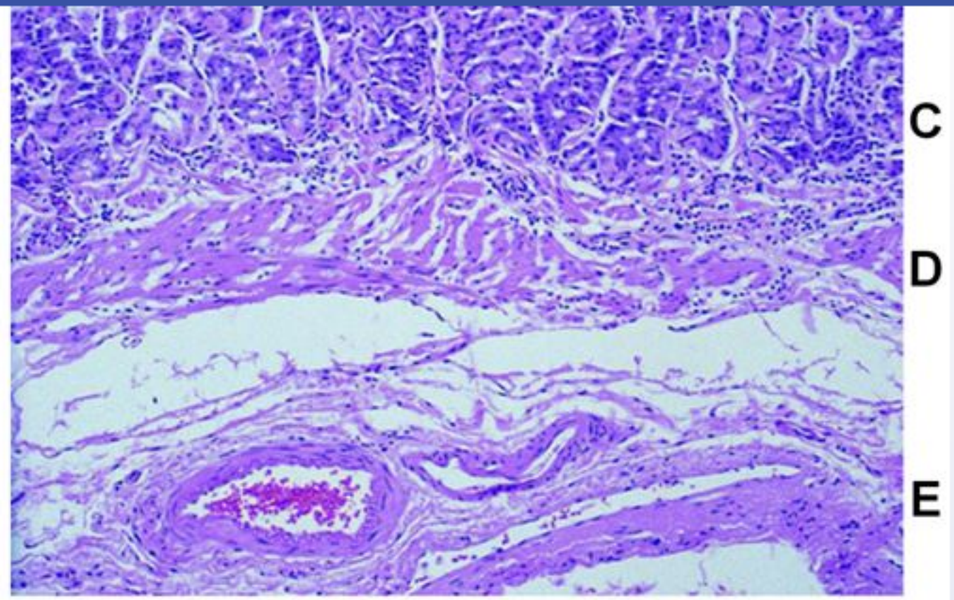

Displayed with permission from Springer Healthcare Ltd. © Copyright 1996 by Current Medicine

A. A (30%)
✓ B. B (52%)
C. C (13%)
D. D (1%)
E. E (1%)

Omitted
Correct answer

52%
Answered correctly

09 secs
Time Spent

05/14/2020
Last Updated

Block Time Remaining: 00:01:58
TUTOR

4 | Feedback | Suspend | End Block

Explanation

Normal gastric histology

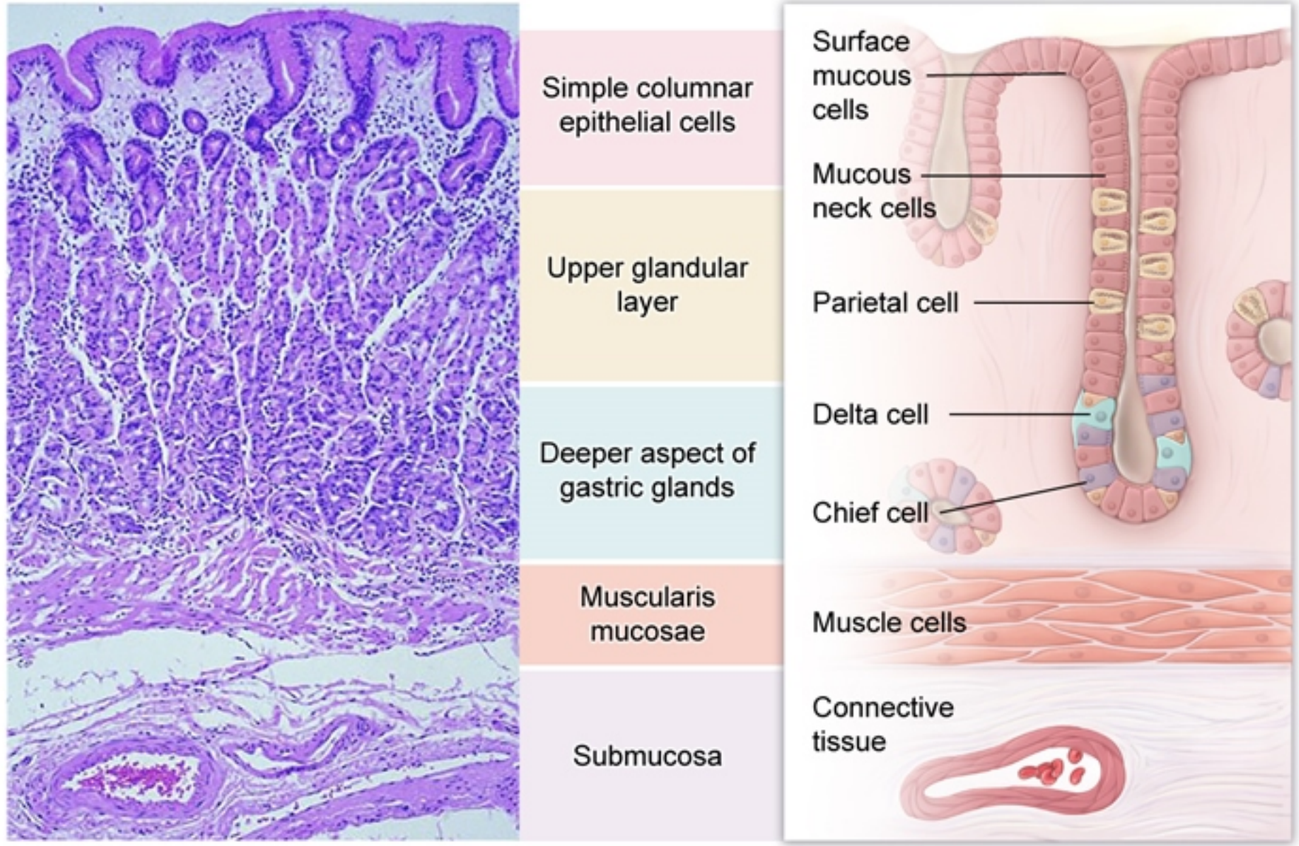

©UWorld

The combination of lower-extremity paresthesias, macrocytic red blood cells (RBCs), and gastric body and fundal atrophy is highly suggestive of **pernicious anemia** (PA). PA is an autoimmune disorder caused by the cell-mediated **destruction of parietal cells**, oxyntic (pale pink) cells found predominantly in the **upper glandular layer** of the gastric body and fundus. Over time, progressive parietal cell destruction leads to chronic atrophic gastritis (ie, autoimmune gastritis), characterized histologically by a CD4-predominate inflammatory infiltrate, oxyntic gland atrophy, and intestinal metaplasia (ie, replacement of normal epithelia with goblet cells).

Parietal cells are responsible for the secretion of hydrochloric acid and intrinsic factor, a glycoprotein that is involved in the absorption of B_{12} (cobalamin, an essential nutrient). After a critical number of parietal cells are destroyed and hepatic stores of cobalamin are depleted, patients **develop B_{12} deficiency**. This results in a **megaloblastic anemia**, characterized by macro-ovalocytes (elevated mean corpuscular volume, oval-shaped RBCs) and hypersegmented neutrophils. Patients also develop neurologic dysfunction due to demyelination of the dorsal and lateral spinal tracts, resulting in **paresthesias and ataxia**.

(Choice A) This region contains simple columnar epithelial cells that secrete mucus to protect the gastric lining from acid.

(Choice C) In contrast to the parietal cell-rich superficial gastric glands, the deeper region of the gastric glands has a preponderance of small, basophilic, granular chief cells that synthesize and secrete pepsinogen. Pyloric glands contain enteroendocrine cells with apical nuclei and light cytoplasm that produce gastrin and somatostatin.

(Choice D) This region contains the muscularis mucosae, which separates the lamina propria from the submucosa.

(Choice E) This region contains the submucosa, which consists of well-vascularized connective tissue.

Educational objective:
Pernicious anemia is an autoimmune disorder caused by the cell-mediated destruction of parietal cells in the superficial upper glandular layer of the gastric body and fundus. Parietal cells are responsible for the secretion of hydrochloric acid and intrinsic factor, a glycoprotein involved in the absorption of B_{12}. Deficiency leads to megaloblastic anemia and neurologic dysfunction.

Histology	Gastrointestinal & Nutrition	Vitamin b12 deficiency
Subject	System	Topic

Explanation

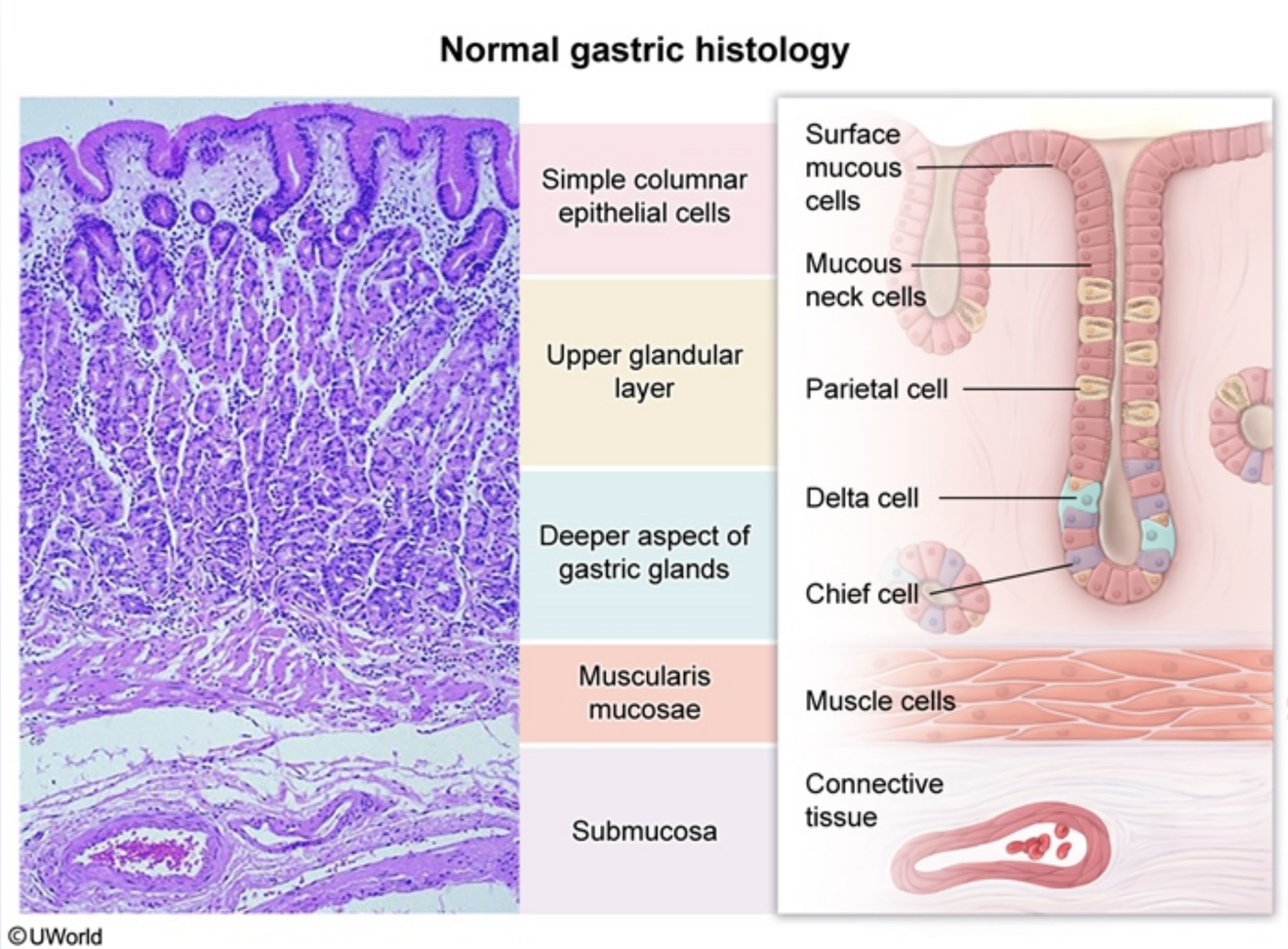

The combination of lower extremity paresthesias, macrocytic red blood cells (RBCs), and gastric body and fundal atrophy is highly suggestive of

Deeper aspect of

Exhibit Display

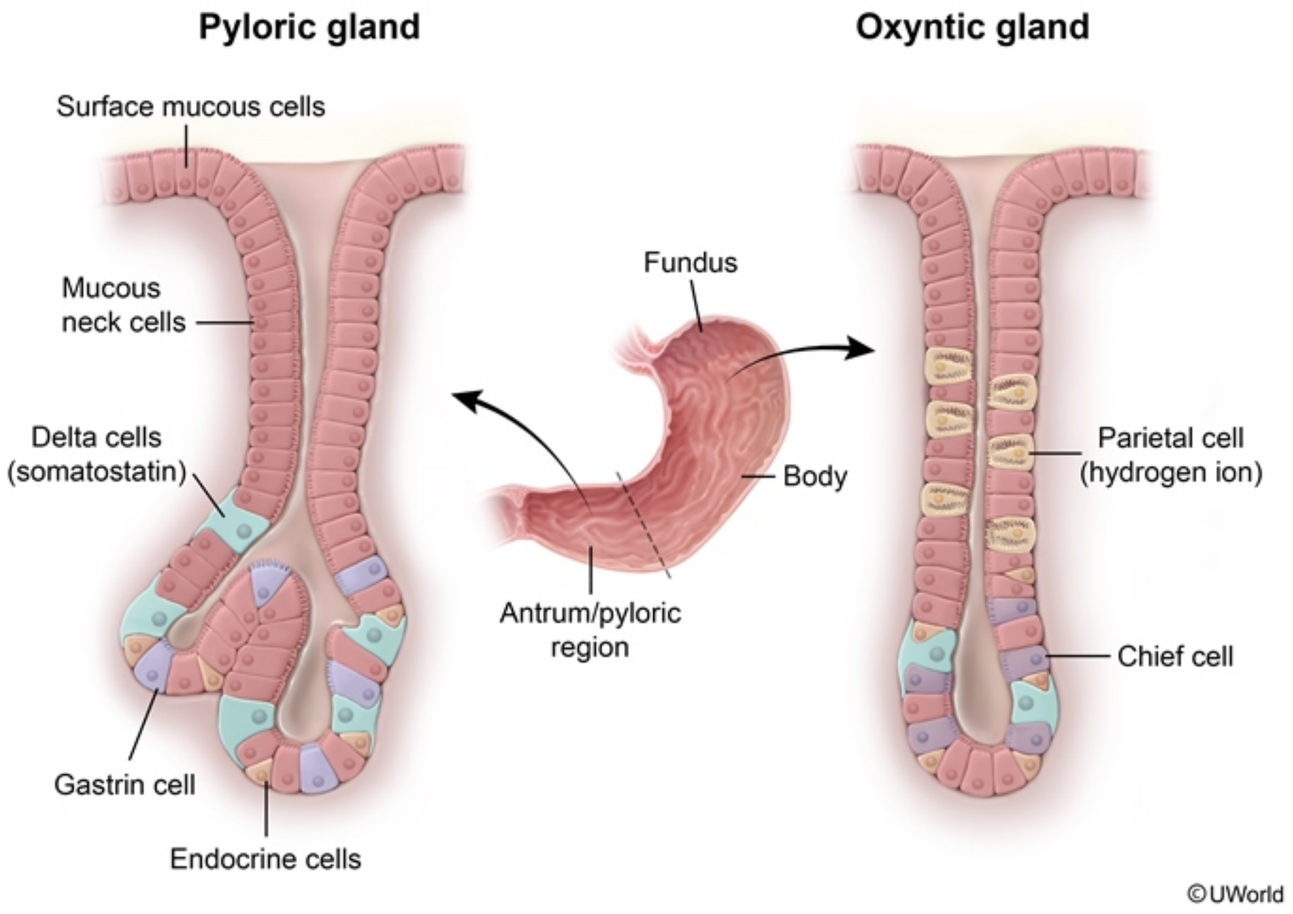

Zoom In | Zoom Out | Reset | Add To New Card | Existing Card

A 20-year-old woman comes to the office due to blisters around her mouth associated with a mild burning sensation. She reports that she has been having frequent recurrence of these lesions, which resolve spontaneously within a few days. She has no medical problems and does not take any medications. Physical examination findings are shown in the image below.

It is determined that the causative organism of this patient's condition remains in a latent state in the neuronal cell bodies of sensory ganglia.

It is determined that the causative organism of this patient's condition remains in a latent state in the neuronal cell bodies of sensory ganglia. Upon reactivation, the virus is transported through the nerve axon to the skin. Which of the following proteins is most likely involved in the transport process leading to disease recurrence?

- A. Dynein
- B. Kinesin
- C. Lamin
- D. Selectin
- E. Spectrin
- F. Vimentin

Submit

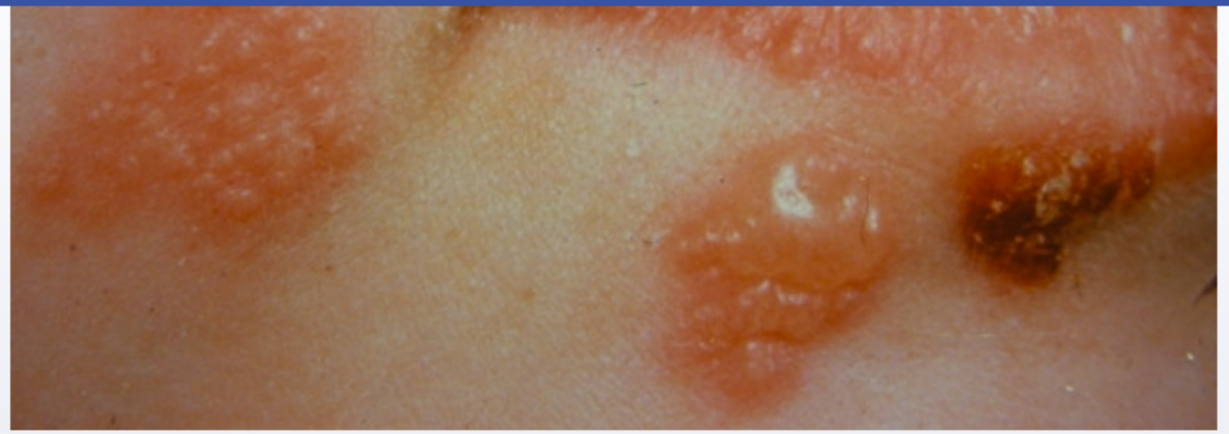

It is determined that the causative organism of this patient's condition remains in a latent state in the neuronal cell bodies of sensory ganglia. Upon reactivation, the virus is transported through the nerve axon to the skin. Which of the following proteins is most likely involved in the transport process leading to disease recurrence?

- A. Dynein (26%)
- ✓ B. Kinesin (65%)
- C. Lamin (1%)
- D. Selectin (1%)
- E. Spectrin (1%)
- F. Vimentin (3%)

Omitted
Correct answer

65%
Answered correctly

06 secs
Time Spent

05/27/2020
Last Updated

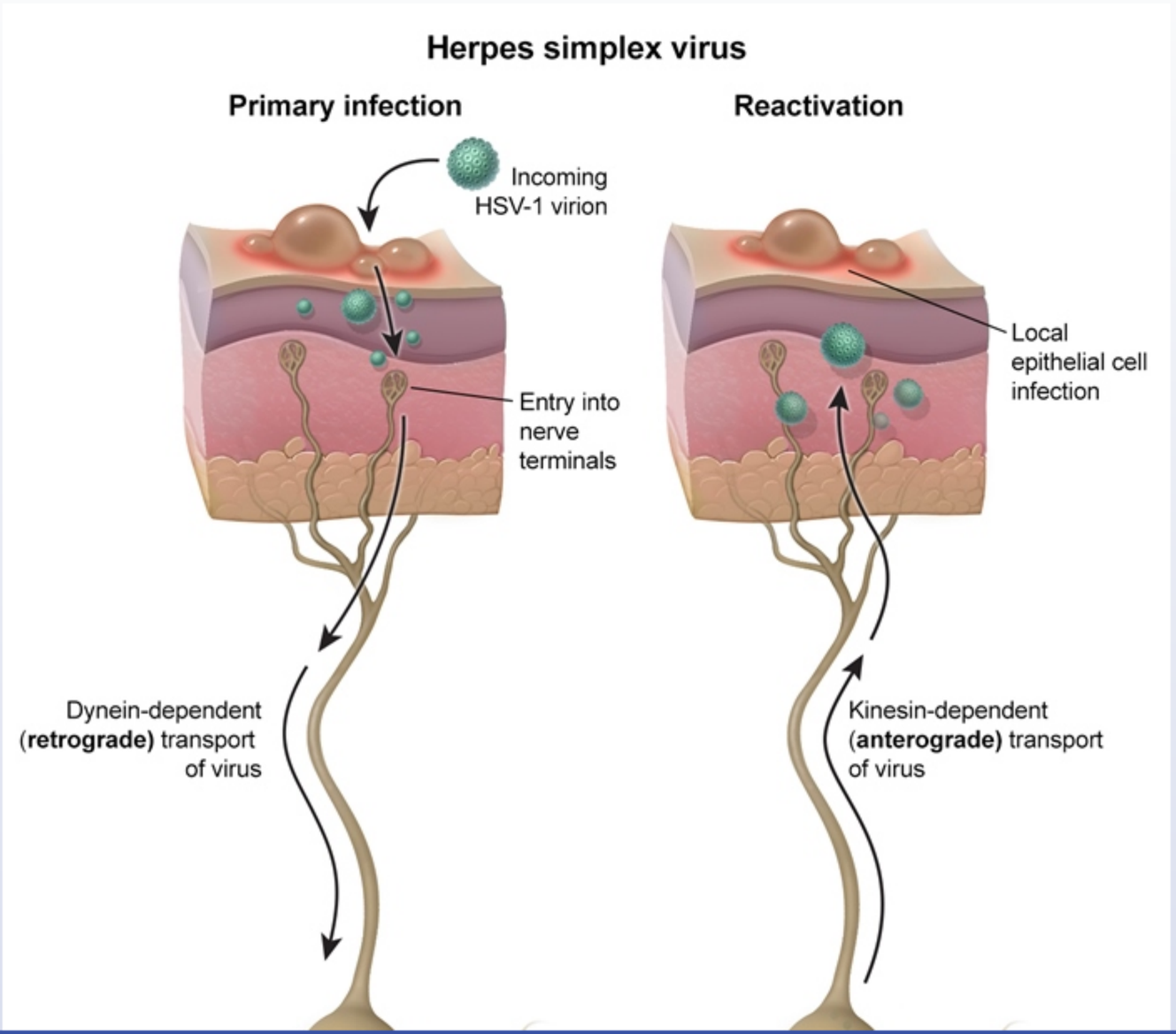
Herpes simplex virus
Primary infection
Reactivation
Incoming HSV-1 virion
Entry into nerve terminals
Local epithelial cell infection
Dynein-dependent (retrograde) transport of virus
Kinesin-dependent (anterograde) transport of virus

Settings

1
2
3
4
5
6
7
8
9
10
11
12
13
14
15
16
17
18
19
20
21
22
23
24
25
26

Item 19 of 26
Question Id: 1922

Mark | Previous | Next | Full Screen | Tutorial | Lab Values | Notes | Calculator | Reverse Color | Text Zoom | Settings

Exhibit Display

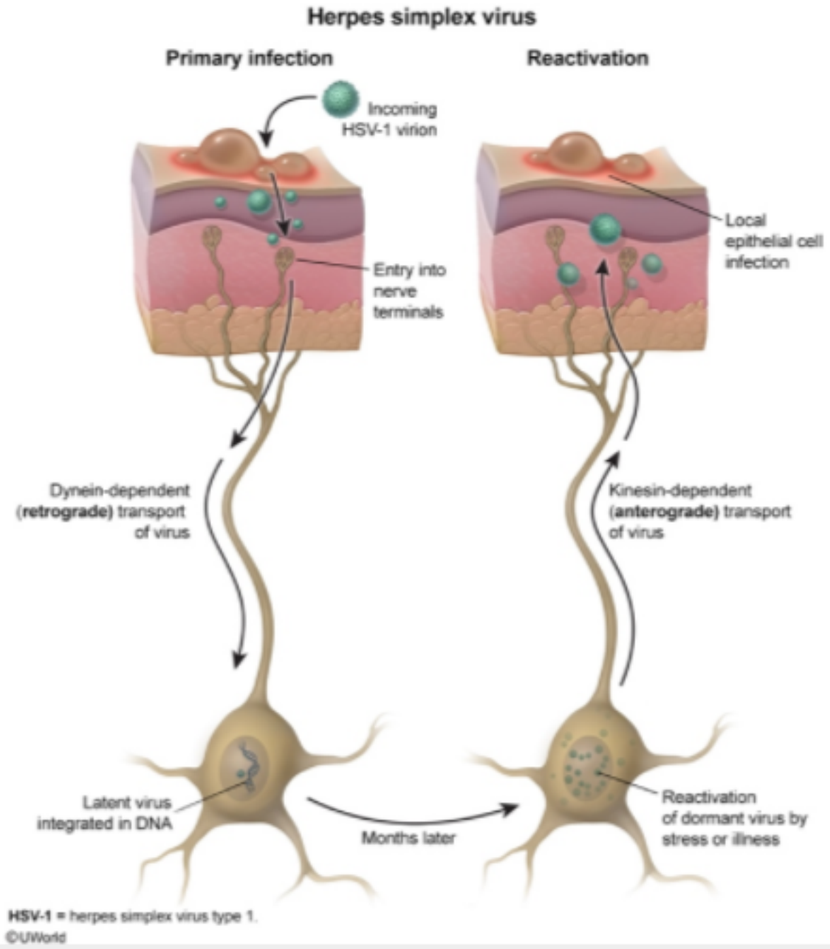

Zoom In | Zoom Out | Reset | Add To New Card | Existing Card

Block Time Remaining: 00:02:04
TUTOR

4 | Feedback | Suspend | End Block

©UWorld

This patient is suffering from recurrent bouts of **herpes labialis** ("cold sores"), which is most commonly caused by ***herpes simplex virus 1 (HSV-1)***. Primary infection occurs following contact with an affected individual's saliva. Although it is often asymptomatic, infection can result in painful blister formation on the oral mucosa and surrounding skin of the mouth and lips. After resolution of the initial infection, the virus enters a latent phase where viral particles lay dormant in neural sensory ganglia (most commonly the trigeminal).

Reactivation of the virus occurs during times of stress or illness, resulting in recurrence of the characteristic perioral vesicular lesions. During reactivation, HSV particles rely on **anterograde axonal transport** to reach the skin and oral mucosa. Anterograde axonal transport is mediated by **kinesin**, a motor protein that moves intracellular cargo (eg, organelles, viral particles) away from the nucleus, down the axon, and toward the nerve terminal. Kinesin-mediated movement is powered by ATP hydrolysis and guided by microtubule filaments, which function as an intracellular "track" system.

(Choice A) Dynein is a microtubular motor protein that participates in retrograde axonal transport (ie, moving organelles toward the nucleus). Dynein is important in establishing the latent phase following primary HSV infection by transporting viral particles to the neural sensory ganglia. However, it is not responsible for disease recurrence.

(Choice C) Lamins are proteins that help form the fibrillar network that lines the inside of the nuclear envelope. In addition to providing structural support, they also help to organize the genome and regulate gene transcription.

(Choice D) Selectins are a group of cell adhesion molecules that are expressed on endothelial cells during the inflammatory response. They function to bind leukocytes, allowing them to exit blood vessels at the site of inflammation.

(Choice E) Spectrin is a cytoskeletal protein located intracellularly along the plasma membrane. It is responsible for maintaining the distinct shape of red blood cells. Protein defects may result in hereditary elliptocytosis and spherocytosis.

(Choice F) Vimentin is a type of intermediate filament expressed in mesenchymal cells. It is responsible for securing organelles inside the cytosol and provides resistance to mechanical stress.

Educational objective:
Kinesin is a microtubule-associated motor protein that functions in the anterograde transport of materials and organelles within cells. Reactivation of latent herpes simplex virus requires anterograde transport of viral particles from neuronal cell bodies in the sensory ganglia to the skin and oral

reactivation, HSV particles rely on **anterograde axonal transport** to reach the skin and oral mucosa. Anterograde axonal transport is mediated by **kinesin**, a motor protein that moves intracellular cargo (eg, organelles, viral particles) away from the nucleus, down the axon, and toward the nerve terminal. Kinesin-mediated movement is powered by ATP hydrolysis and guided by microtubule filaments, which function as an intracellular "track" system.

(Choice A) Dynein is a microtubular motor protein that participates in retrograde axonal transport (ie, moving organelles toward the nucleus). Dynein is important in establishing the latent phase following primary HSV infection by transporting viral particles to the neural sensory ganglia. However, it is not responsible for disease recurrence.

(Choice C) Lamins are proteins that help form the fibrillar network that lines the inside of the nuclear envelope. In addition to providing structural support, they also help to organize the genome and regulate gene transcription.

(Choice D) Selectins are a group of cell adhesion molecules that are expressed on endothelial cells during the inflammatory response. They function to bind leukocytes, allowing them to exit blood vessels at the site of inflammation.

(Choice E) Spectrin is a cytoskeletal protein located intracellularly along the plasma membrane. It is responsible for maintaining the distinct shape of red blood cells. Protein defects may result in hereditary elliptocytosis and spherocytosis.

(Choice F) Vimentin is a type of intermediate filament expressed in mesenchymal cells. It is responsible for securing organelles inside the cytosol and provides resistance to mechanical stress.

Educational objective:
Kinesin is a microtubule-associated motor protein that functions in the anterograde transport of materials and organelles within cells. Reactivation of latent herpes simplex virus requires anterograde transport of viral particles from neuronal cell bodies in the sensory ganglia to the skin and oral mucosa.

Histology	Nervous System	Neuronal physiology
Subject	System	Topic

Copyright © UWorld. All rights reserved.

reactivation, HSV particles rely on **anterograde axonal transport** to reach the skin and oral mucosa. Anterograde axonal transport is mediated

Exhibit Display

Spherocytosis

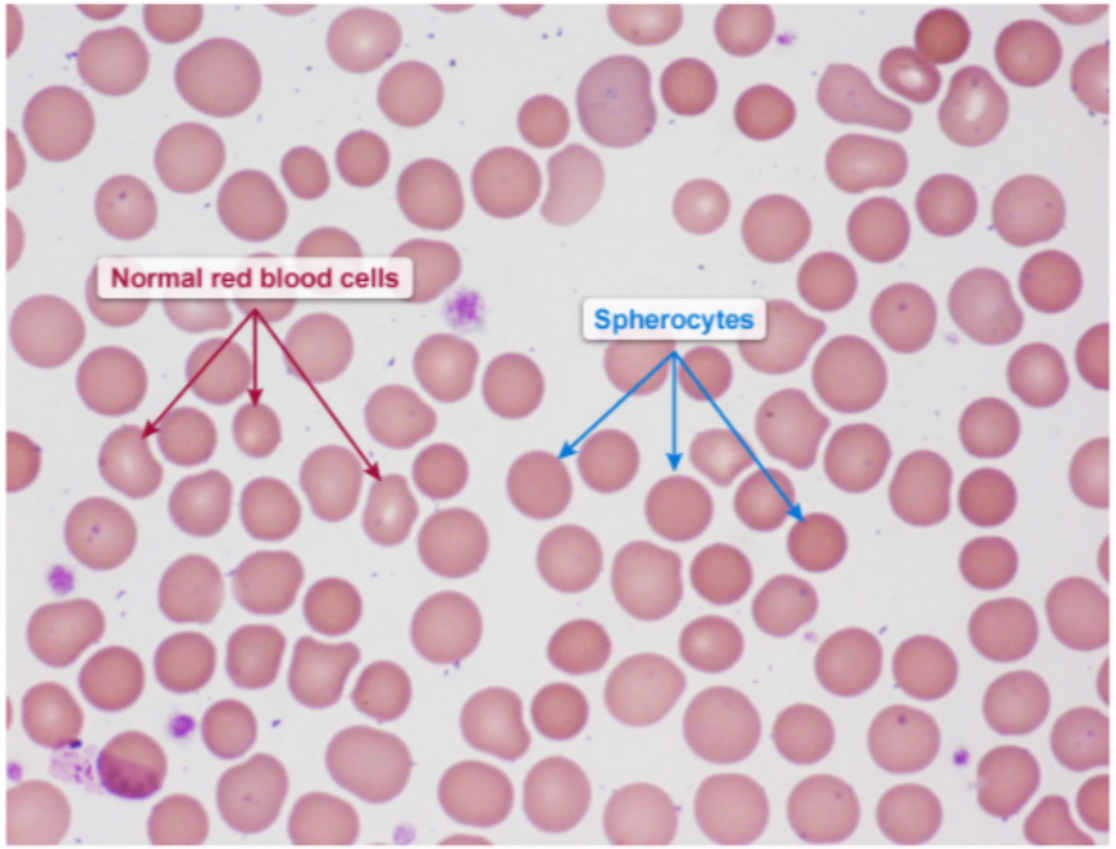

©UWorld

Zoom In Zoom Out Reset Add To New Card | Existing Card

A 67-year-old man was found dead for unknown reasons. He has a long history of hypertension and suffered a myocardial infarction 1 year ago. The family requested that an autopsy be performed. Gross examination of his heart shows scarring and enlargement of the left ventricle. A histological section of his left ventricle is shown below.

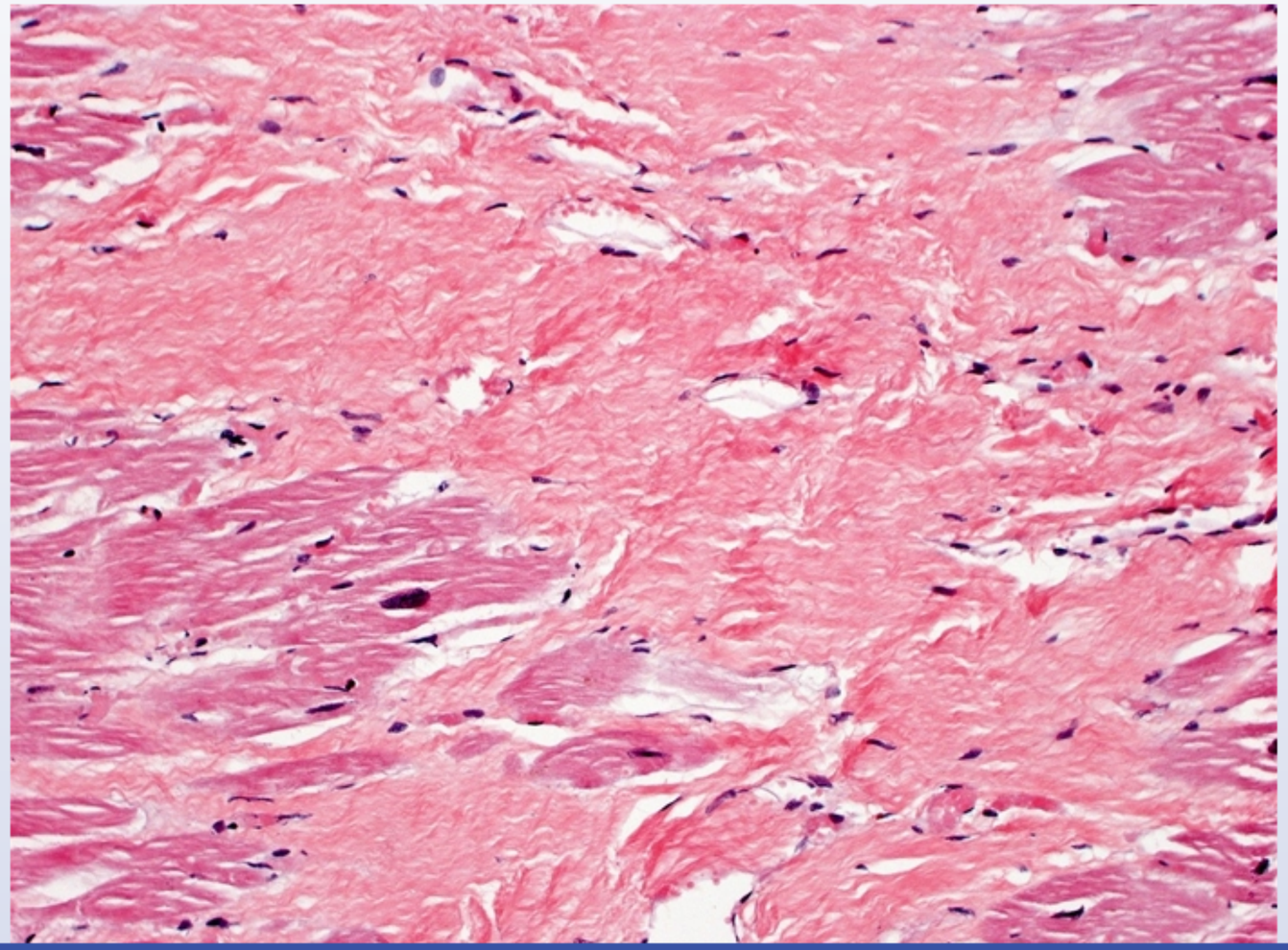

Histological section of his left ventricle is shown below.

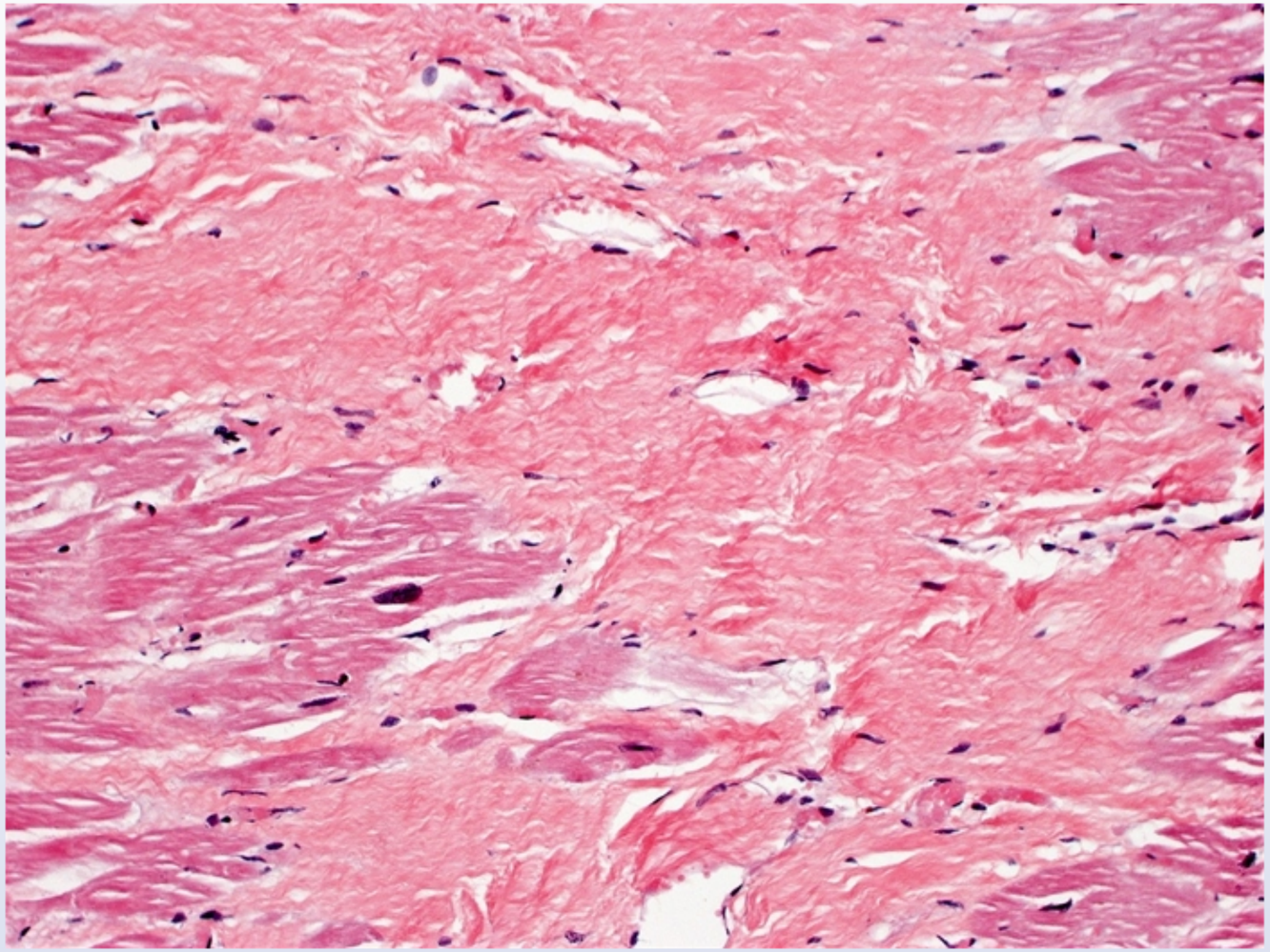

The type of collagen seen in the image is most similar to collagen found in which of the following tissues?

A. Basement membrane

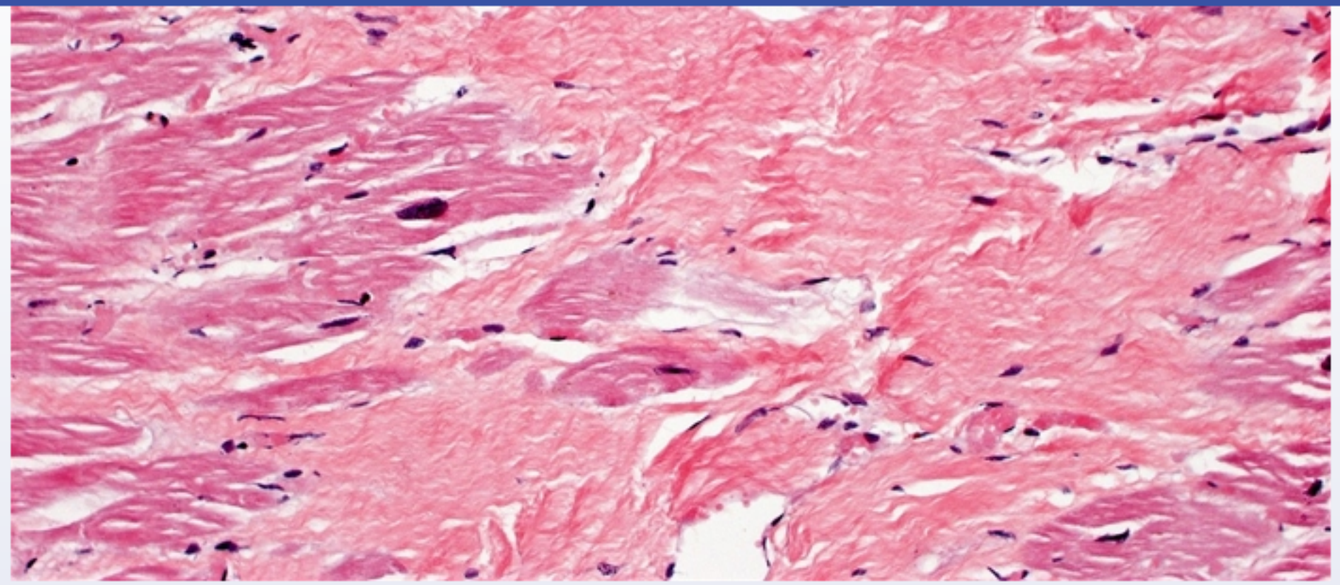

The type of collagen seen in the image is most similar to collagen found in which of the following tissues?

- A. Basement membrane
- B. Granulation tissue
- C. Hyaline cartilage
- D. Nucleus pulposus
- E. Tendon

Submit

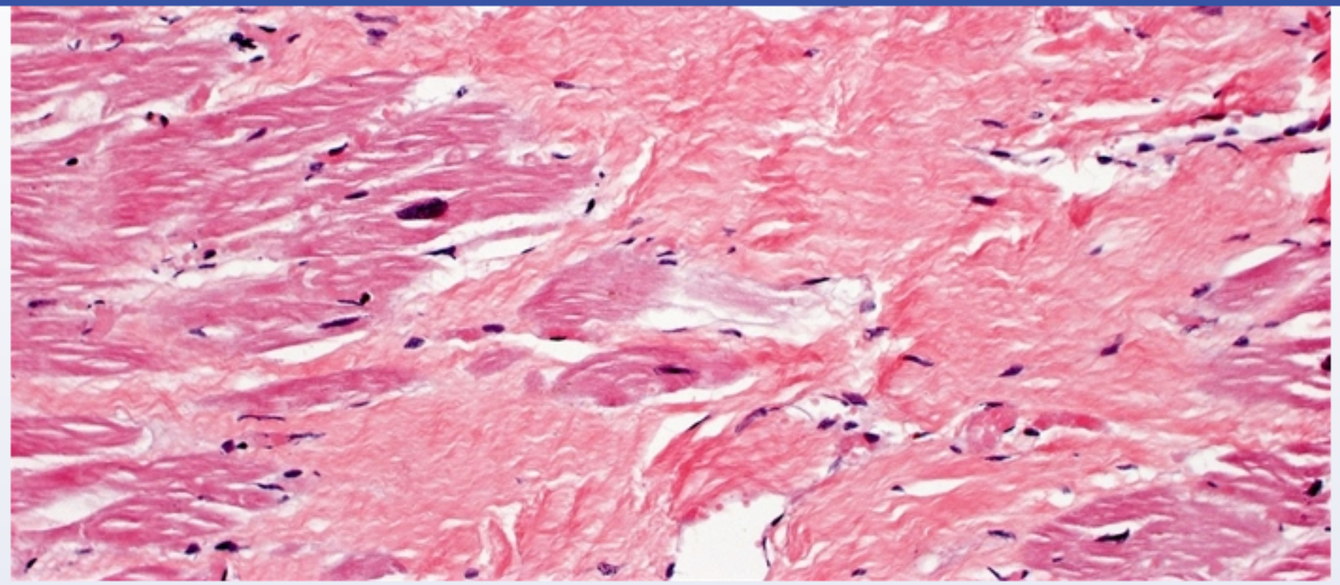

The type of collagen seen in the image is most similar to collagen found in which of the following tissues?

- A. Basement membrane (5%)
- B. Granulation tissue (36%)
- C. Hyaline cartilage (14%)
- D. Nucleus pulposus (2%)
- ✓ E. Tendon (40%)

Omitted
Correct answer

40%
Answered correctly

07 secs
Time Spent

02/24/2020
Last Updated

Collagen subtypes

Type	Locations	Associated diseases
I	Dermis, bone, tendons, ligaments, dentin, cornea, blood vessels & scar tissue	Osteogenesis imperfecta
II	Cartilage, vitreous humor & nucleus pulposus	
III	Skin, lungs, intestines, blood vessels, bone marrow, lymphatics & granulation tissue	Ehlers-Danlos syndrome (types 3 & 4)
IV	Basement membranes	Alport syndrome

©UWorld

Evolution of a myocardial infarction occurs in several stages. The final stage of the healing process begins 2 weeks after infarction and involves increased type I collagen deposition. Fibrosis continues until about 2 months after infarction, resulting in a dense collagenous scar composed primarily of type I collagen.

Type I collagen is the most abundant type and is widely distributed throughout the human body. It is found in most interstitial connective tissues where it provides strength and support for cellular tissues and organs. It is also the major organic component in bones and significantly contributes to overall bone strength. Defects in type I collagen can occur in osteogenesis imperfecta, an autosomal dominant disorder that presents with easily fracturable bones.

(Choices A, C, & D) Cartilage and nucleus pulposus contain type II collagen, whereas basement membranes contain type IV collagen.

(Choice B) Granulation tissue is composed primarily of type III collagen. It is seen approximately 7 days following an acute myocardial infarction

III	Skin, lungs, intestines, blood vessels, bone marrow, lymphatics & granulation tissue	Ehlers-Danlos syndrome (types 3 & 4)
IV	Basement membranes	Alport syndrome

©UWorld

Evolution of a myocardial infarction occurs in several stages. The final stage of the healing process begins 2 weeks after infarction and involves increased type I collagen deposition. Fibrosis continues until about 2 months after infarction, resulting in a dense collagenous scar composed primarily of type I collagen.

Type I collagen is the most abundant type and is widely distributed throughout the human body. It is found in most interstitial connective tissues where it provides strength and support for cellular tissues and organs. It is also the major organic component in bones and significantly contributes to overall bone strength. Defects in type I collagen can occur in osteogenesis imperfecta, an autosomal dominant disorder that presents with easily fracturable bones.

(Choices A, C, & D) Cartilage and nucleus pulposus contain type II collagen, whereas basement membranes contain type IV collagen.

(Choice B) Granulation tissue is composed primarily of type III collagen. It is seen approximately 7 days following an acute myocardial infarction but is eventually replaced by type 1 collagen as the infarct matures. Type III collagen is involved in the structural maintenance of extensible connective tissues and is often found alongside type 1 collagen. It also forms the reticular fibers present in organs such as the spleen, lymph nodes, and bone marrow.

Educational objective:
Type I collagen is the most prevalent collagen in the human body and is the primary collagen in mature scars.

Histology	Cardiovascular System	Myocardial infarction
Subject	System	Topic

Copyright © UWorld. All rights reserved.

III	Skin, lungs, intestines, blood vessels, bone marrow, lymphatics & granulation tissue	Ehlers-Danlos syndrome (types 3 & 4)

©UW

Evolution of a myocardial
increased type I collagen
primarily of type I collagen

Type I collagen is the mos
where it provides strength
contributes to overall bone
presents with easily fractu

(Choices A, C, & D) Cart

(Choice B) Granulation ti
but is eventually replaced
connective tissues and is
nodes, and bone marrow.

Educational objective:
Type I collagen is the mos

Histology — Subject
Cardiova — System

Exhibit Display

Time after myocardial infarction	Predominant light microscopic changes
0-4 hours	• No visible change
4-12 hours	• Wavy fibers with narrow, elongated myocytes
12-24 hours	• Myocyte hypereosinophilia with pyknotic (shrunken) nuclei
1-3 days	• Coagulation necrosis (loss of nuclei & striations) • Prominent neutrophilic infiltrate
3-7 days	• Disintegration of dead neutrophils & myofibers • Macrophage infiltration at border areas
7-10 days	• Robust phagocytosis of dead cells by macrophages • Beginning formation of granulation tissue at margins
10-14 days	• Well-developed granulation tissue with neovascularization
2 weeks-2 months	• Progressive collagen deposition & scar formation

Add To New Card | Existing Card

Copyright © UWorld. All rights reserved.

III	Skin, lungs, intestines, blood vessels, bone marrow, lymphatics & granulation tissue	Ehlers-Danlos syndrome (types 3 & 4)

©UW

Evolution of a myocardial
increased type I collagen
primarily of type I collagen

Type I collagen is the mos
where it provides strength
contributes to overall bone
presents with easily fractu

(Choices A, C, & D) Cart

(Choice B) Granulation ti
but is eventually replaced
connective tissues and is
nodes, and bone marrow.

Educational objective:
Type I collagen is the mos

Histology — Subject
Cardiova — System

Exhibit Display

Time after myocardial infarction	Predominant light microscopic changes
0-4 hours	• No visible change
4-12 hours	• Wavy fibers with narrow, elongated myocytes
12-24 hours	• Myocyte hypereosinophilia with pyknotic (shrunken) nuclei
1-3 days	• Coagulation necrosis (loss of nuclei & striations) • Prominent neutrophilic infiltrate
3-7 days	• Disintegration of dead neutrophils & myofibers • Macrophage infiltration at border areas
7-10 days	• Robust phagocytosis of dead cells by macrophages • Beginning formation of granulation tissue at margins
10-14 days	• Well-developed granulation tissue with neovascularization
2 weeks-2 months	• Progressive collagen deposition & scar formation

Add To New Card | Existing Card

Copyright © UWorld. All rights reserved.

Settings

1
2
3
4
5
6
7
8
9
10
11
12
13
14
15
16
17
18
19
20
21
22
23
24
25
26

Item 20 of 26
Question Id: 8711

Mark | Previous | Next | Full Screen | Tutorial | Lab Values | Notes | Calculator | Reverse Color | Text Zoom | Settings

III	Skin, lungs, intestines, blood vessels, bone	Ehlers-Danlos syndrome

Exhibit Display

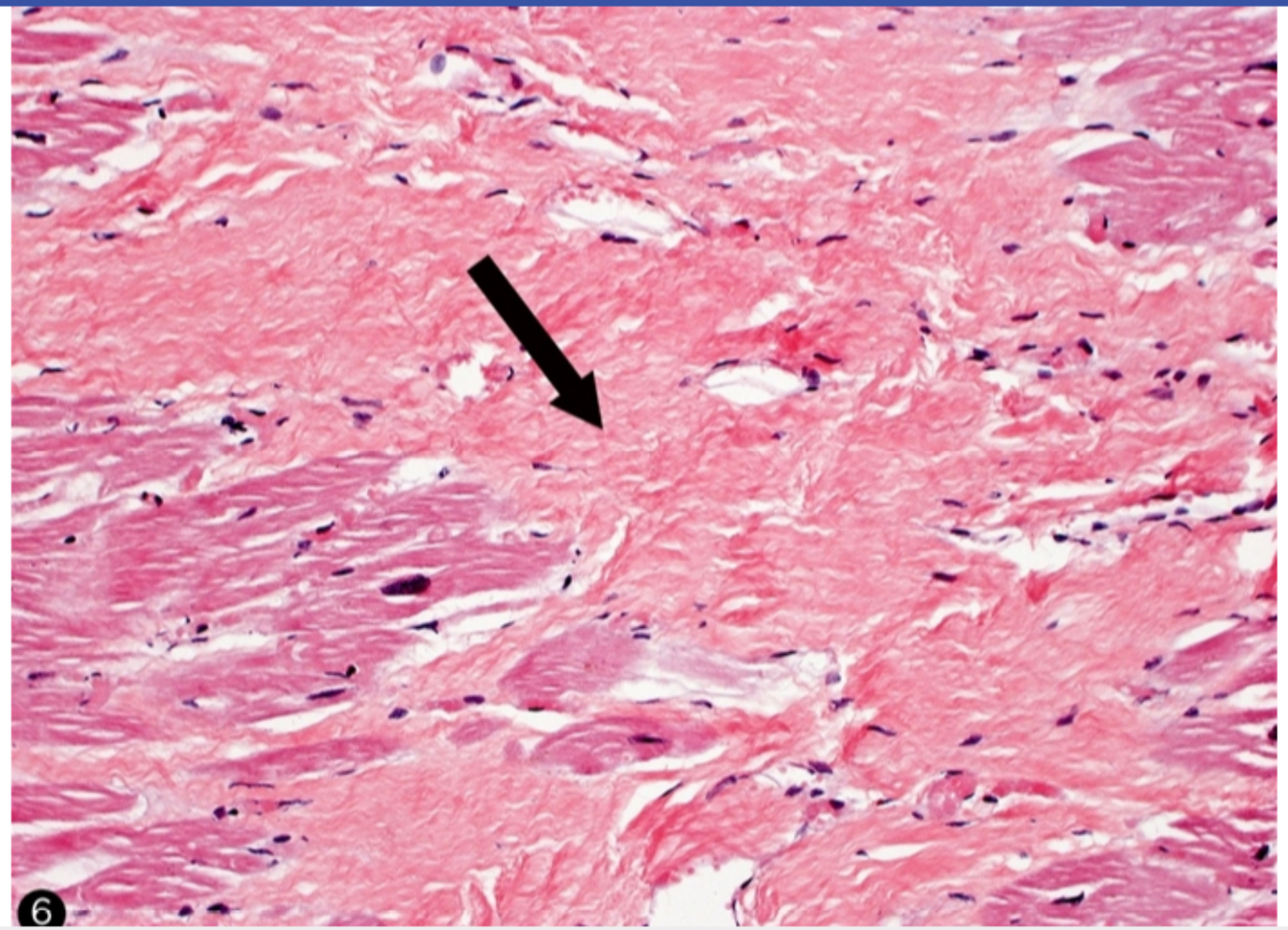

Zoom In | Zoom Out | Reset | Add To New Card | Existing Card

Block Time Remaining: 00:02:11
TUTOR

5 | Feedback | Suspend | End Block

Researchers analyzing eukaryotic genome structure and function perform an experiment to extract DNA from exocrine pancreatic cells. During the purification process, they isolate small circular DNA molecules that resemble a bacterial chromosome. Further analysis shows that these molecules code for proteins, transfer RNA, and ribosomal RNA. From which of the following cellular structures did these DNA molecules most likely originate?

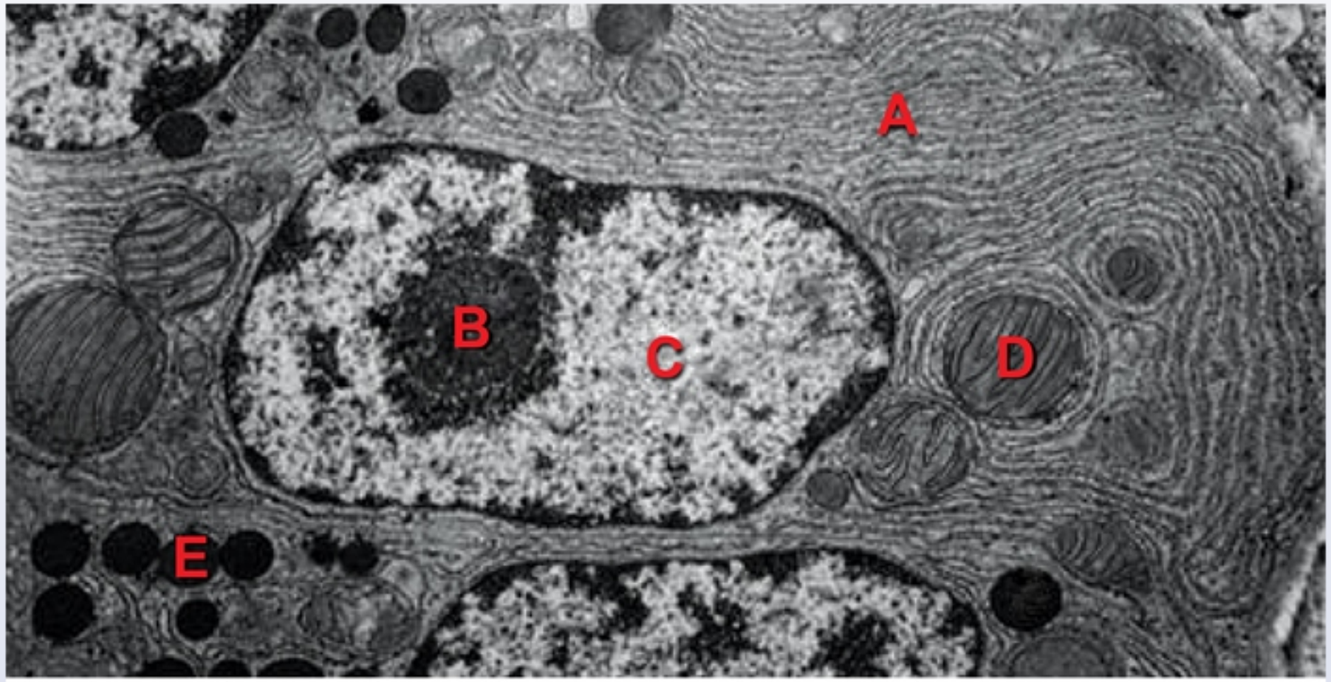

©UWorld

A. A

B. B

C. C

Settings

1
2
3
4
5
6
7
8
9
10
11
12
13
14
15
16
17
18
19
20
21
22
23
24
25
26

Item 21 of 26
Question Id: 1473

Mark | Previous | Next | Full Screen | Tutorial | Lab Values | Notes | Calculator | Reverse Color | Text Zoom | Settings

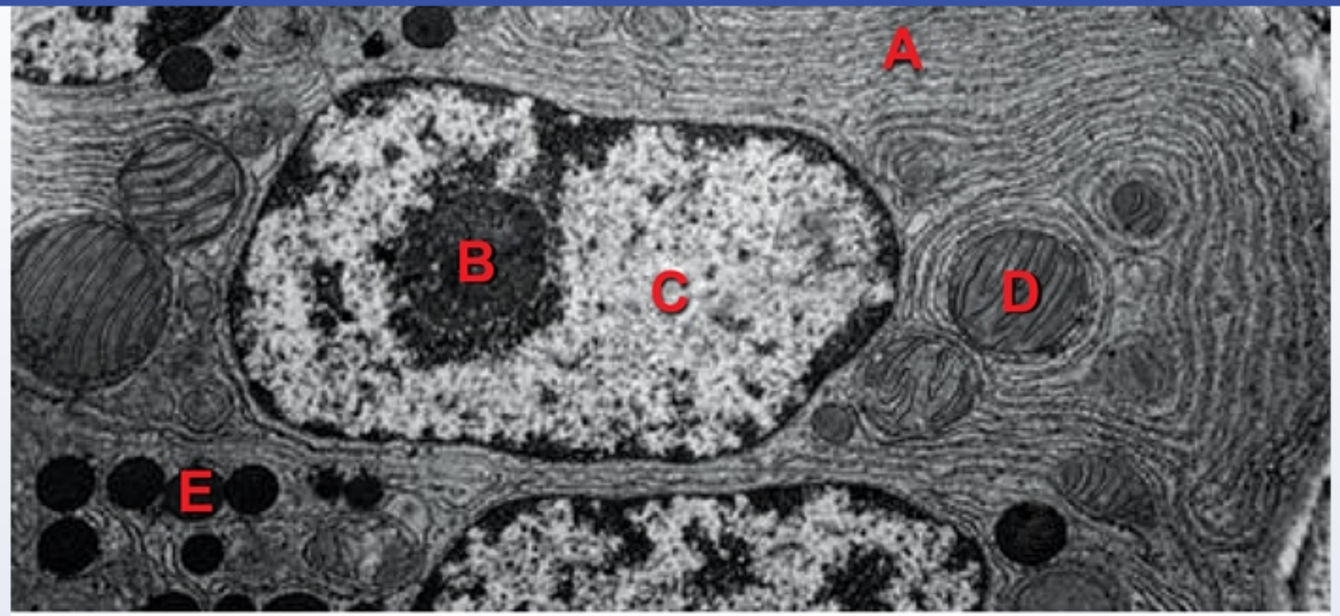

©UWorld

A. A

B. B

C. C

D. D

E. E

Submit

Block Time Remaining: 00:02:14
TUTOR

2 | Feedback | Suspend | End Block

Settings

1 2 3 4 5 6 7 8 9 10 11 12 13 14 15 16 17 18 19 20 21 22 23 24 25 26

Item 21 of 26
Question Id: 1473

Mark | Previous | Next | Full Screen | Tutorial | Lab Values | Notes | Calculator | Reverse Color | Text Zoom | Settings

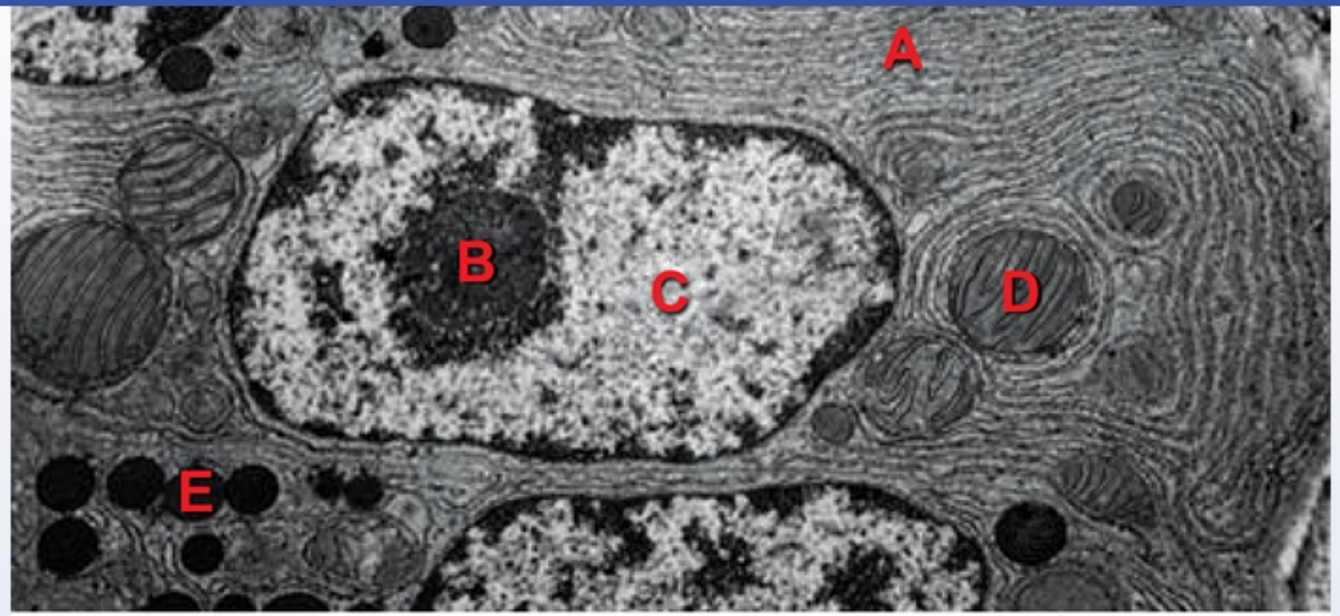

©UWorld

A. A (4%)
B. B (28%)
C. C (12%)
✓ D. D (52%)
E. E (2%)

Omitted
Correct answer

52%
Answered correctly

05 secs
Time Spent

04/09/2020
Last Updated

Block Time Remaining: 00:02:16
TUTOR

2 | Feedback | Suspend | End Block

Explanation

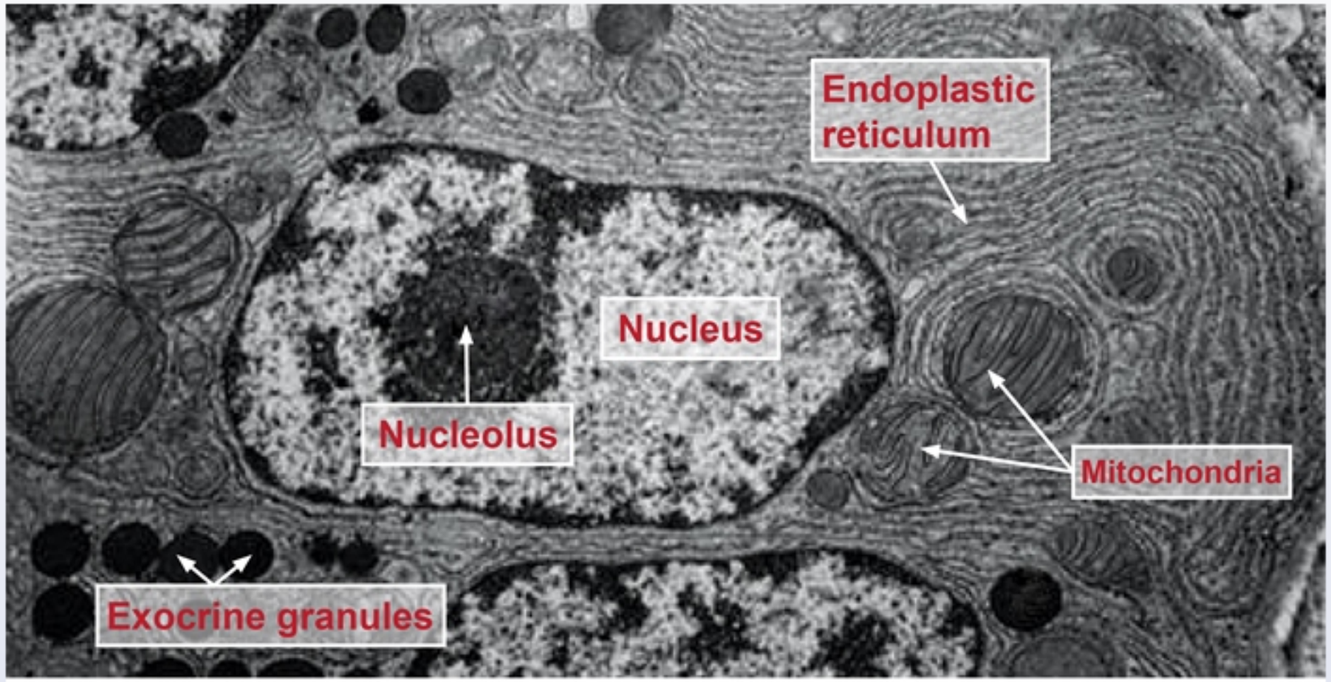

©UWorld

Nuclear chromosomes contain most of the DNA found in human cells. However, mitochondria also contain their own DNA called **mitochondrial DNA** (mtDNA). This DNA exists as a **small circular chromosome** with a slightly different genetic code than that of nuclear DNA, consistent with the endosymbiotic theory that mitochondria originated as prokaryotic cells that were later engulfed by ancient eukaryotes.

Over time, most of the genes coding for mitochondrial proteins have migrated to nuclear DNA. However, mtDNA still codes for about 14 proteins (some involved in oxidative metabolic pathways) and the ribosomal and transfer RNA needed for mitochondrial protein synthesis. Each mitochondrion contains 1-10 copies of **maternally derived** mtDNA. As a result, diseases arising from mutations in mtDNA are transmitted from the mother to all of her offspring.

Mitochondria can be identified on electron microscopy by their characteristic **double membrane and wavy cristae**.

©UWorld

Nuclear chromosomes contain most of the DNA found in human cells. However, mitochondria also contain their own DNA called **mitochondrial DNA** (mtDNA). This DNA exists as a **small circular chromosome** with a slightly different genetic code than that of nuclear DNA, consistent with the endosymbiotic theory that mitochondria originated as prokaryotic cells that were later engulfed by ancient eukaryotes.

Over time, most of the genes coding for mitochondrial proteins have migrated to nuclear DNA. However, mtDNA still codes for about 14 proteins (some involved in oxidative metabolic pathways) and the ribosomal and transfer RNA needed for mitochondrial protein synthesis. Each mitochondrion contains 1-10 copies of **maternally derived** mtDNA. As a result, diseases arising from mutations in mtDNA are transmitted from the mother to all of her offspring.

Mitochondria can be identified on electron microscopy by their characteristic **double membrane and wavy cristae**.

(Choice A) The rough endoplastic reticulum has a stippled appearance secondary to the presence of numerous ribosomes bound to its membranes. These ribosomes are involved in the synthesis of integral membrane proteins and proteins destined for export or packaging into granules or organelles.

(Choice B) The dark region identified within the nucleus is the nucleolus, the site of synthesis and assembly of eukaryotic ribosomal components. There is no lipid membrane separating the nucleolus from the rest of the nucleus.

(Choice C) The lighter "electron-lucent" regions within the nucleus signify euchromatin (unpackaged DNA actively being transcribed).

(Choice E) This electron-dense membrane-bound spherical structure represents an exocrine granule containing enzymes and other proteins packaged for secretion.

Educational objective:
Mitochondrial DNA (mtDNA) is the most common non-nuclear DNA found in eukaryotic cells. It resembles prokaryotic DNA and is maternally derived. Mutations involving mtDNA or nuclear DNA that codes for mitochondrial proteins can cause a variety of mitochondrial disorders, including Leigh syndrome and MELAS.

Histology	General Principles	Mitochondrial disorders
Subject	System	Topic

Settings

1
2
3
4
5
6
7
8
9
10
11
12
13
14
15
16
17
18
19
20
21
22
23
24
25
26

Item 22 of 26
Question Id: 480

Mark | Previous | Next | Full Screen | Tutorial | Lab Values | Notes | Calculator | Reverse Color | Text Zoom | Settings

Fourth-year medical students are recruited for a research study assessing their ability to interpret biopsy samples obtained during routine clinical practice. As part of the study, they are given samples of normal respiratory mucosa and asked to identify the cell types present after staining with hematoxylin and eosin. The students observe that the respiratory epithelium changes in composition as the airways continue distally from the trachea to the alveolar ducts. Which of the following features is last to disappear?

A. Cartilage
B. Cilia
C. Goblet cells
D. Mucous glands
E. Serous glands

Submit

Block Time Remaining: 00:02:17
TUTOR

3 | Feedback | Suspend | End Block

Fourth-year medical students are recruited for a research study assessing their ability to interpret biopsy samples obtained during routine clinical practice. As part of the study, they are given samples of normal respiratory mucosa and asked to identify the cell types present after staining with hematoxylin and eosin. The students observe that the respiratory epithelium changes in composition as the airways continue distally from the trachea to the alveolar ducts. Which of the following features is last to disappear?

- A. Cartilage (7%)
- ✓ B. Cilia (51%)
- C. Goblet cells (19%)
- D. Mucous glands (11%)
- E. Serous glands (10%)

Omitted
Correct answer
B

51%
Answered correctly

02 secs
Time Spent

03/04/2020
Last Updated

Explanation

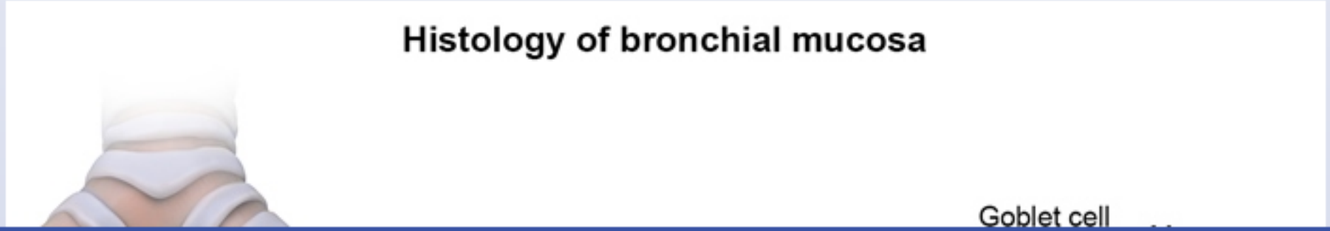

Settings

1
2
3
4
5
6
7
8
9
10
11
12
13
14
15
16
17
18
19
20
21
22
23
24
25
26

Item 22 of 26
Question Id: 480

Mark | Previous | Next | Full Screen | Tutorial | Lab Values | Notes | Calculator | Reverse Color | Text Zoom | Settings

Histology of bronchial mucosa

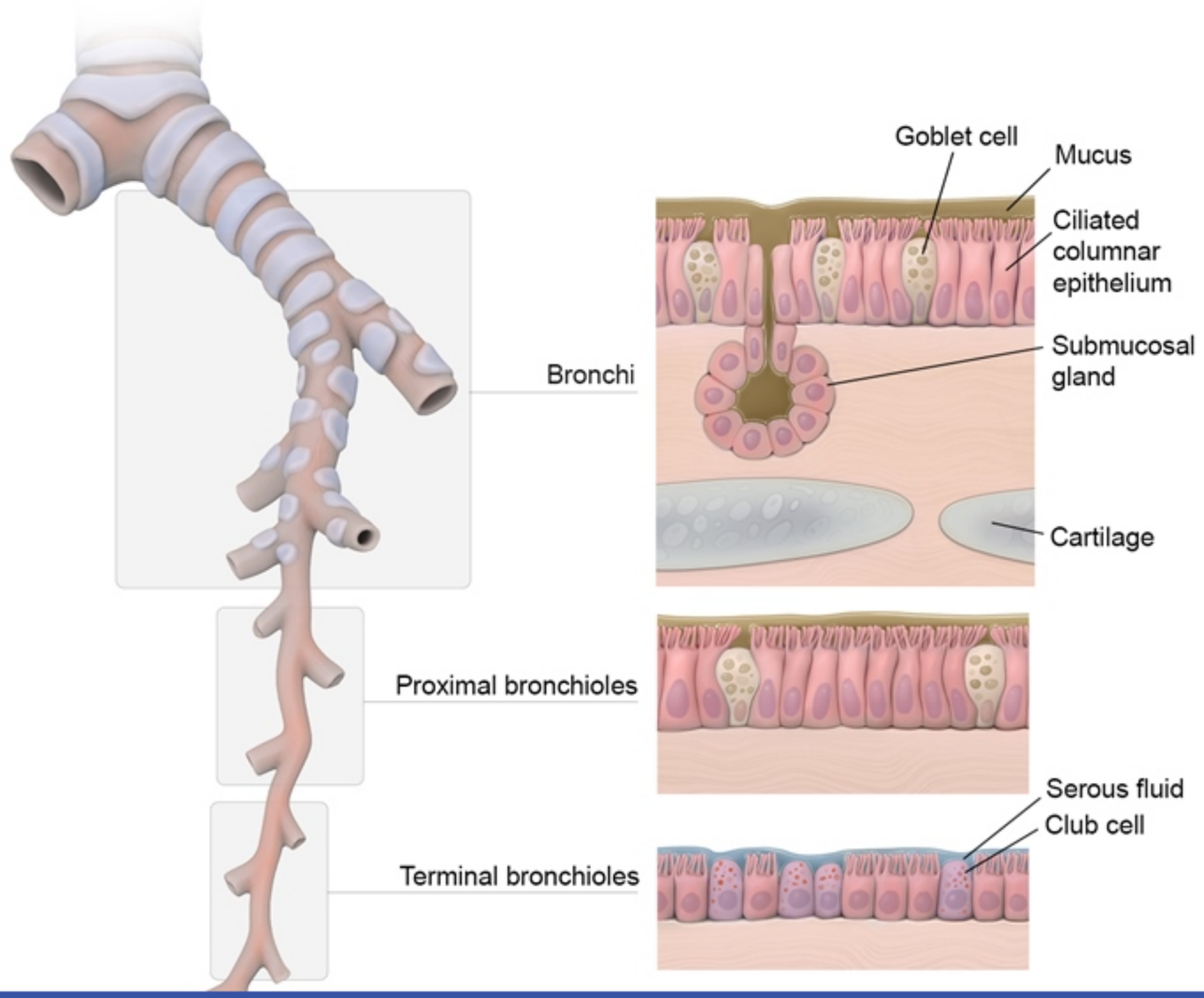

Block Time Remaining: 00:02:18
TUTOR

3 | Feedback | Suspend | End Block

Settings

1
2
3
4
5
6
7
8
9
10
11
12
13
14
15
16
17
18
19
20
21
22
23
24
25
26

Item 22 of 26
Question Id: 480

Mark | Previous | Next | Full Screen | Tutorial | Lab Values | Notes | Calculator | Reverse Color | Text Zoom | Settings

Histology of bronchial mucosa

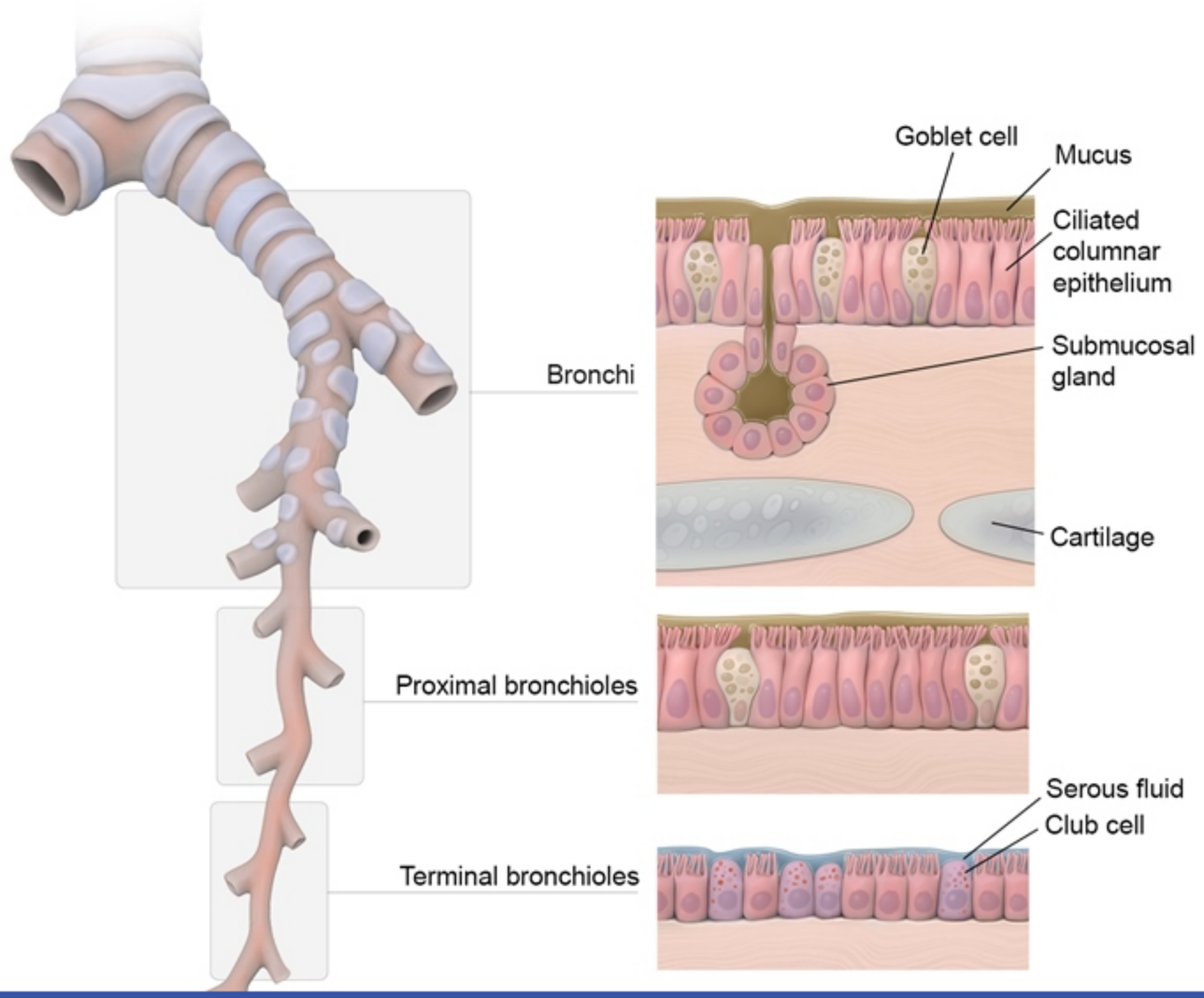

Block Time Remaining: 00:02:18
TUTOR

3 | Feedback | Suspend | End Block

Settings

1
2
3
4
5
6
7
8
9
10
11
12
13
14
15
16
17
18
19
20
21
22
23
24
25
26

Item 22 of 26
Question Id: 480

Mark | Previous | Next | Full Screen | Tutorial | Lab Values | Notes | Calculator | Reverse Color | Text Zoom | Settings

Exhibit Display

Histology of bronchial mucosa

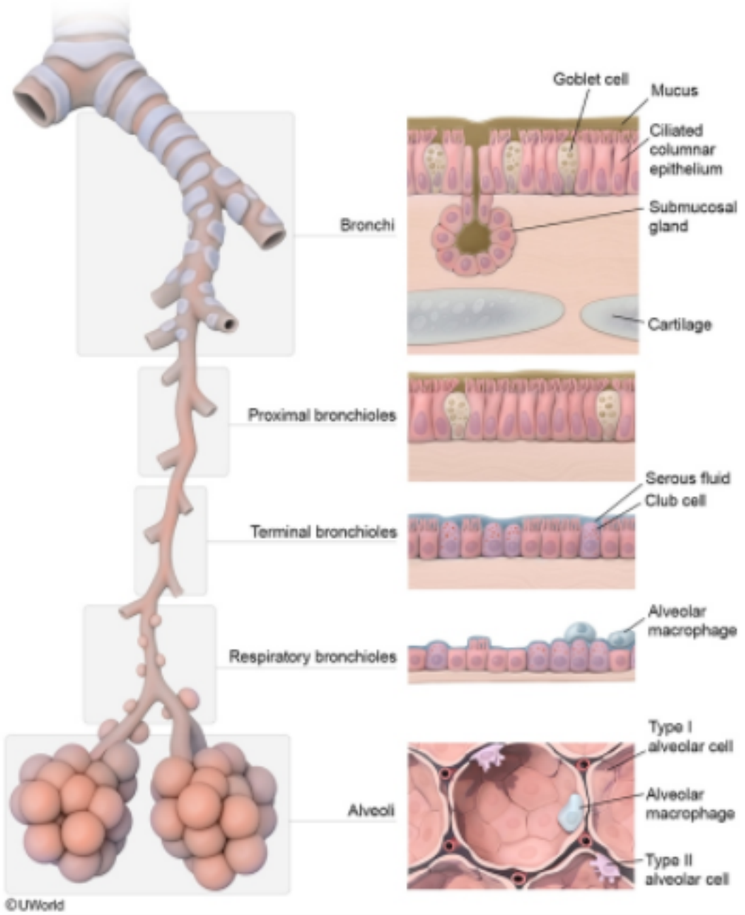

Zoom In | Zoom Out | Reset | Add To New Card | Existing Card

Block Time Remaining: 00:02:18
TUTOR

3 | Feedback | Suspend | End Block

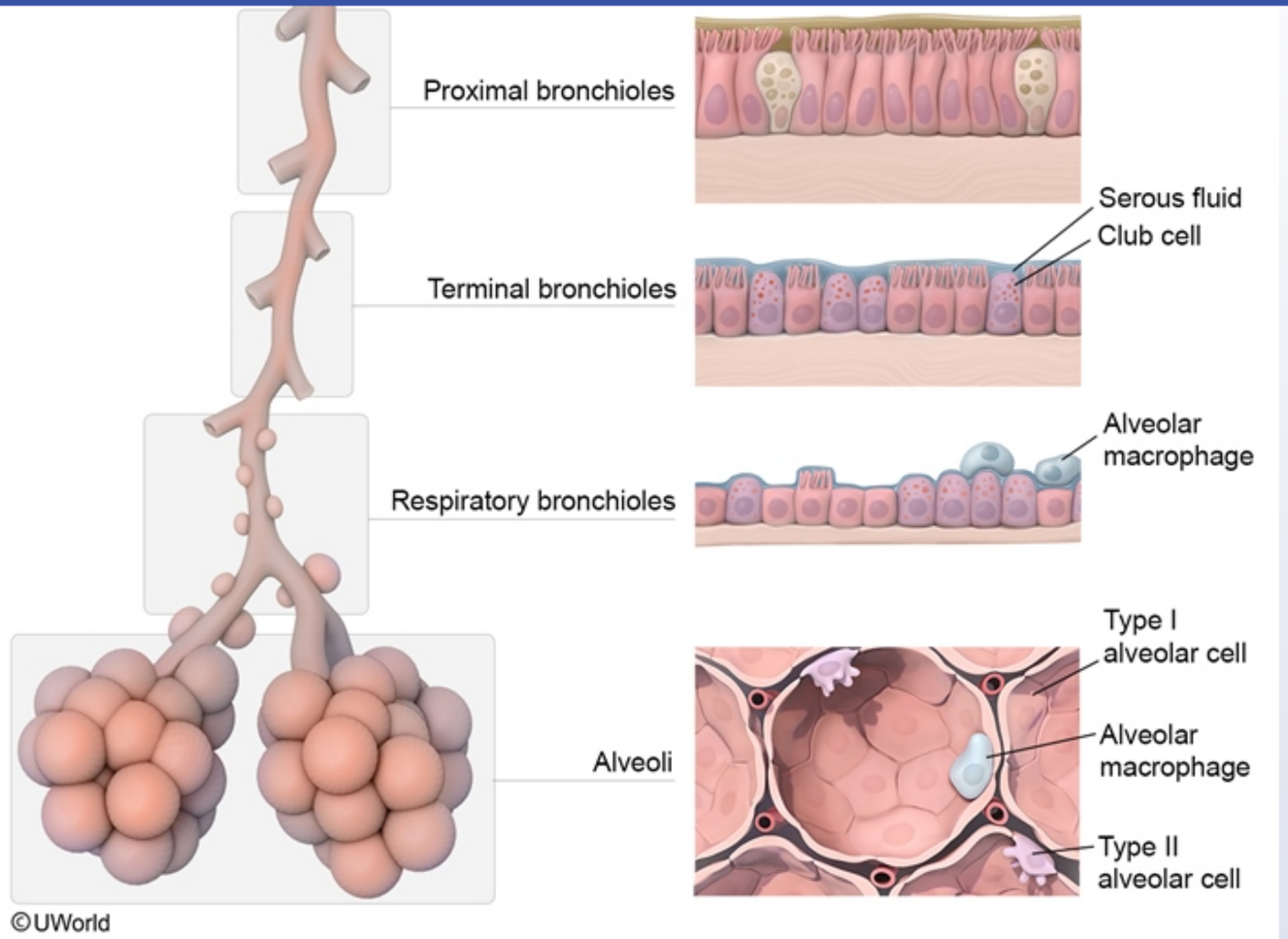

Ciliated mucosal epithelium lines the pulmonary airways from the trachea to the respiratory bronchioles. The airway epithelium gradually changes from pseudostratified ciliated columnar to ciliated simple cuboidal by the level of the terminal bronchioles. **Ciliated cells** continue to be present through the proximal portions of the **respiratory bronchioles**, but are not present in the alveolar ducts or in the alveoli themselves. This arrangement is important because cilia function to propel mucus toward the pharynx. The presence of cilia beyond the most distal mucus-

©UWorld

Ciliated mucosal epithelium lines the pulmonary airways from the trachea to the respiratory bronchioles. The airway epithelium gradually changes from pseudostratified ciliated columnar to ciliated simple cuboidal by the level of the terminal bronchioles. **Ciliated cells** continue to be present through the proximal portions of the **respiratory bronchioles**, but are not present in the alveolar ducts or in the alveoli themselves. This arrangement is important because cilia function to propel mucus toward the pharynx. The presence of cilia beyond the most distal mucus-producing cells (goblet cells end before the terminal bronchioles) prevents bronchiolar mucus accumulation and airflow obstruction.

(Choice A) The rings of hyaline cartilage that encircle the trachea are replaced by cartilaginous plates in the bronchi. These rings and plates help keep the larger airways open and end at the termination of the smallest bronchi (they are not found in bronchioles).

(Choice C) Goblet cells are mucus-secreting cells that are present from the trachea down to the larger bronchioles. They are not found within the terminal bronchioles, which are lined by club cells.

(Choices D and E) The submucosal mucous glands and serous glands are found from the trachea to the distal-most bronchi and produce mucinous components that help trap inhaled particles. They are not present within the bronchioles.

Educational objective:
Bronchi have a ciliated pseudostratified columnar epithelium with mucin-secreting goblet cells and submucosal mucoserous glands. The airway epithelium gradually changes to ciliated simple cuboidal by the level of the terminal bronchioles. Bronchioles lack glands and cartilage, and the number of goblet cells decreases distally, ending before the terminal bronchioles. Ciliated epithelium persists up to the respiratory bronchioles.

Histology	Pulmonary & Critical Care	Respiratory mucosa
Subject	System	Topic

Copyright © UWorld. All rights reserved.

A 9-year-old girl is brought to the office due to 2 days of face and eye puffiness. The patient was treated for a rash on her leg with an antibiotic about 3 weeks ago. Temperature is 37.2 C (99 F) and blood pressure is 150/90 mm Hg. On physical examination, there is generalized edema but no rash. Urinalysis reveals proteinuria and hematuria. An electron microscopy image representative of this patient's disease process is shown below:

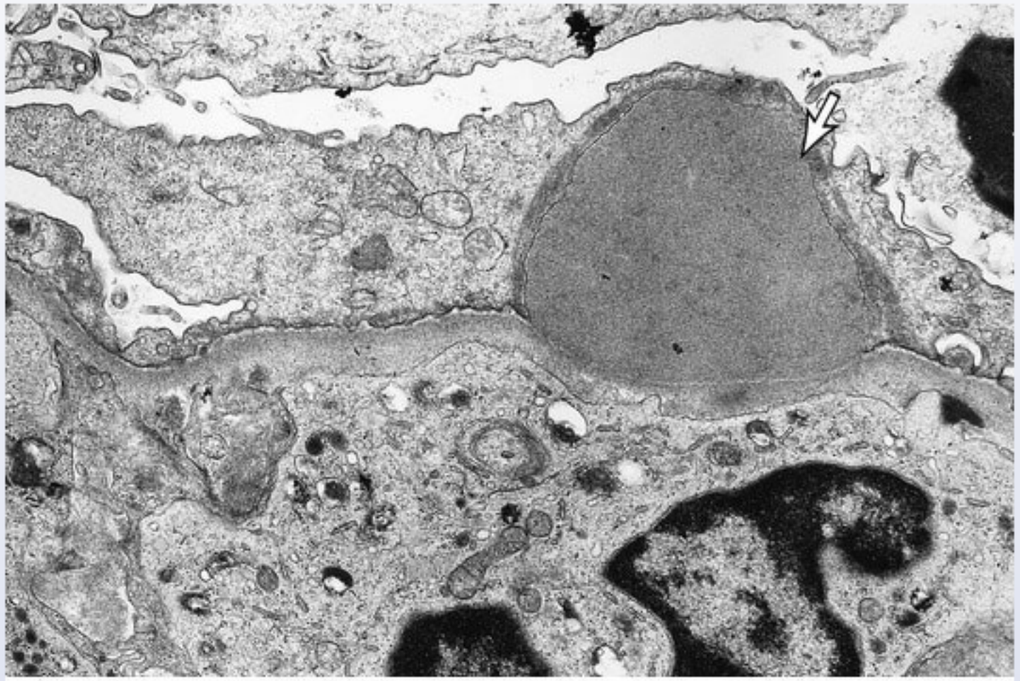

Displayed with permission from Springer Healthcare Ltd. © Copyright 1999 by Current Medicine

The area marked by the white arrow most likely represents which of the following?

A. Albumin leakage

B. Eosinophil enzymes

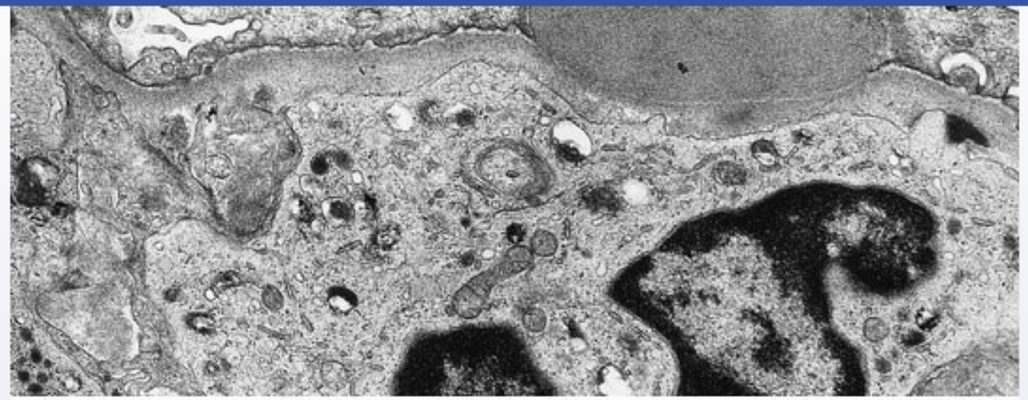

Displayed with permission from Springer Healthcare Ltd. © Copyright 1999 by Current Medicine

The area marked by the white arrow most likely represents which of the following?

- A. Albumin leakage
- B. Eosinophil enzymes
- C. Fibrin deposition
- D. Hyaline accumulation
- E. Immune complex deposits
- F. Lipid droplet
- G. Neutrophil enzymes

Submit

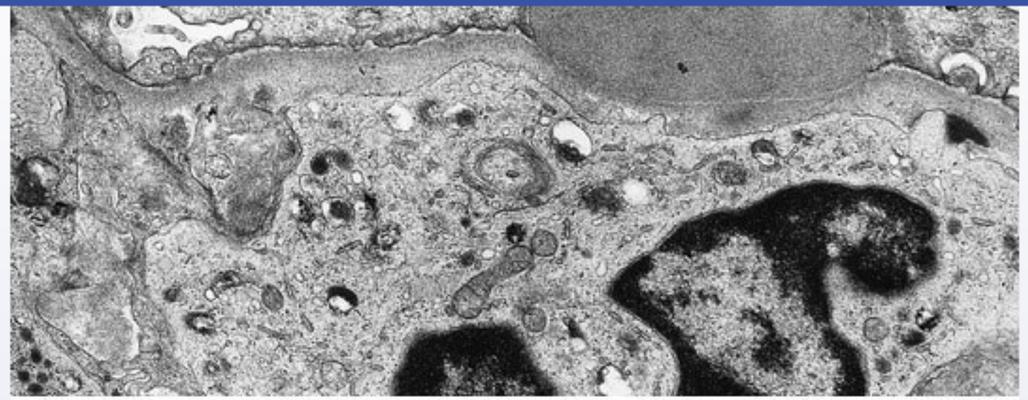

Displayed with permission from Springer Healthcare Ltd. © Copyright 1999 by Current Medicine

The area marked by the white arrow most likely represents which of the following?

- A. Albumin leakage (5%)
- B. Eosinophil enzymes (1%)
- C. Fibrin deposition (2%)
- D. Hyaline accumulation (2%)
- ✓ E. Immune complex deposits (84%)
- F. Lipid droplet (2%)
- G. Neutrophil enzymes (0%)

Omitted
Correct answer

84%
Answered correctly

06 secs
Time Spent

02/08/2020
Last Updated

Acute poststreptococcal glomerulonephritis	

Clinical features	• Can be asymptomatic
	• If symptomatic:
	  ◦ Gross hematuria (tea- or cola-colored urine)
	  ◦ Edema (periorbital, generalized)
	  ◦ Hypertension

Laboratory findings	• Urinalysis: + protein, + blood, ± red blood cell casts
	• Serum:
	  ◦ ↓ C3 & possible ↓ C4
	  ◦ ↑ Serum creatinine
	  ◦ ↑ Anti-DNase B & ↑ AHase
	  ◦ ↑ ASO & ↑ anti-NAD (from preceding pharyngitis)

AHase = antihyaluronidase; **anti-DNase B** = antideoxyribonuclease-B; **ASO** = antistreptolysin O.

This pediatric patient with hypertension, hematuria, proteinuria, and edema has a nephritic syndrome. The onset 3 weeks after a bacterial skin infection suggests **poststreptococcal glomerulonephritis** (PSGN), an immune complex–mediated disease that occurs 2-4 weeks after exposure to group A beta-hemolytic *Streptococcus* (eg, impetigo, pharyngeal infection). Acute kidney injury is common and leads to fluid and salt retention, often resulting in edema and hypertension.

The **immune complexes** in PSGN are deposited along the glomerular basement membrane (GBM) and are visible on electron microscopy as large, **dome-shaped**, **subepithelial**, electron-dense **deposits** ("humps"). These can be further visualized on immunofluorescence as **granular** deposits of IgG, IgM, and C3 along the GBM and glomerular mesangium ("**lumpy-bumpy**" appearance). On light microscopy, the glomeruli are enlarged and hypercellular due to leukocyte infiltration.

(Choice A) Proteins such as albumin may be lost in the urine due to increased permeability of the glomerular capillary wall in PSGN. However, albumin does not deposit within the glomerulus or renal tubules.

This pediatric patient with hypertension, hematuria, proteinuria, and edema has a nephritic syndrome. The onset 3 weeks after a bacterial skin infection suggests **poststreptococcal glomerulonephritis** (PSGN), an immune complex–mediated disease that occurs 2-4 weeks after exposure to group A beta-hemolytic *Streptococcus* (eg, impetigo, pharyngeal infection). Acute kidney injury is common and leads to fluid and salt retention, often resulting in edema and hypertension.

The **immune complexes** in PSGN are deposited along the glomerular basement membrane (GBM) and are visible on electron microscopy as large, **dome-shaped**, **subepithelial**, electron-dense **deposits** ("humps"). These can be further visualized on immunofluorescence as **granular** deposits of IgG, IgM, and C3 along the GBM and glomerular mesangium ("**lumpy-bumpy**" appearance). On light microscopy, the glomeruli are enlarged and hypercellular due to leukocyte infiltration.

(Choice A) Proteins such as albumin may be lost in the urine due to increased permeability of the glomerular capillary wall in PSGN. However, albumin does not deposit within the glomerulus or renal tubules.

(Choice B) Many antibiotics (eg, penicillins, cephalosporins) can cause acute interstitial nephritis (AIN), which manifests as peritubular T-lymphocyte, monocyte, and eosinophilic infiltration. However edema, significant hematuria, and proteinuria are uncommon, and AIN usually resolves when the offending agent is discontinued.

(Choice C) Prominent fibrin deposition is characteristic of rapidly progressive (crescentic) glomerulonephritis.

(Choice D) Hyaline, acellular deposits composed of plasma proteins, can be seen in Kimmelstiel-Wilson nodules of diabetic nephropathy.

(Choice F) Lipid droplets in renal tubules may be seen in conditions causing nephrotic syndrome, which leads to heavy proteinuria and edema; however, hypertension and hematuria are unexpected. In addition, lipid droplets do not deposit on the basement membrane.

(Choice G) Neutrophils and monocytes infiltrate the glomerular mesangium in PSGN, contributing to the hypercellular appearance on light microscopy. Enzymes released from these cells would not typically form extracellular aggregates.

Educational objective:
Poststreptococcal glomerulonephritis is an immune complex–mediated disease that occurs 2-4 weeks after group A beta-hemolytic *Streptococcus* infection. Immune complexes composed of IgG, IgM, and C3 are deposited along the glomerular basement membrane and are visible on electron microscopy as large, dome-shaped, subepithelial, electron-dense deposits.

A 62-year-old man comes to the office for the evaluation of jaundice. Medical history is significant for uncontrolled type 2 diabetes mellitus and morbid obesity. He does not use tobacco, alcohol, or illicit drugs. There is no family history of liver disease. Vital signs are within normal limits. BMI is 47 kg/m^2. Mild scleral icterus is present. Heart and lung sounds are normal. The abdomen is nontender and nondistended. Trace bilateral lower extremity edema is present. Laboratory studies reveal elevated transaminases. A liver biopsy is obtained, and trichrome staining shows the following:

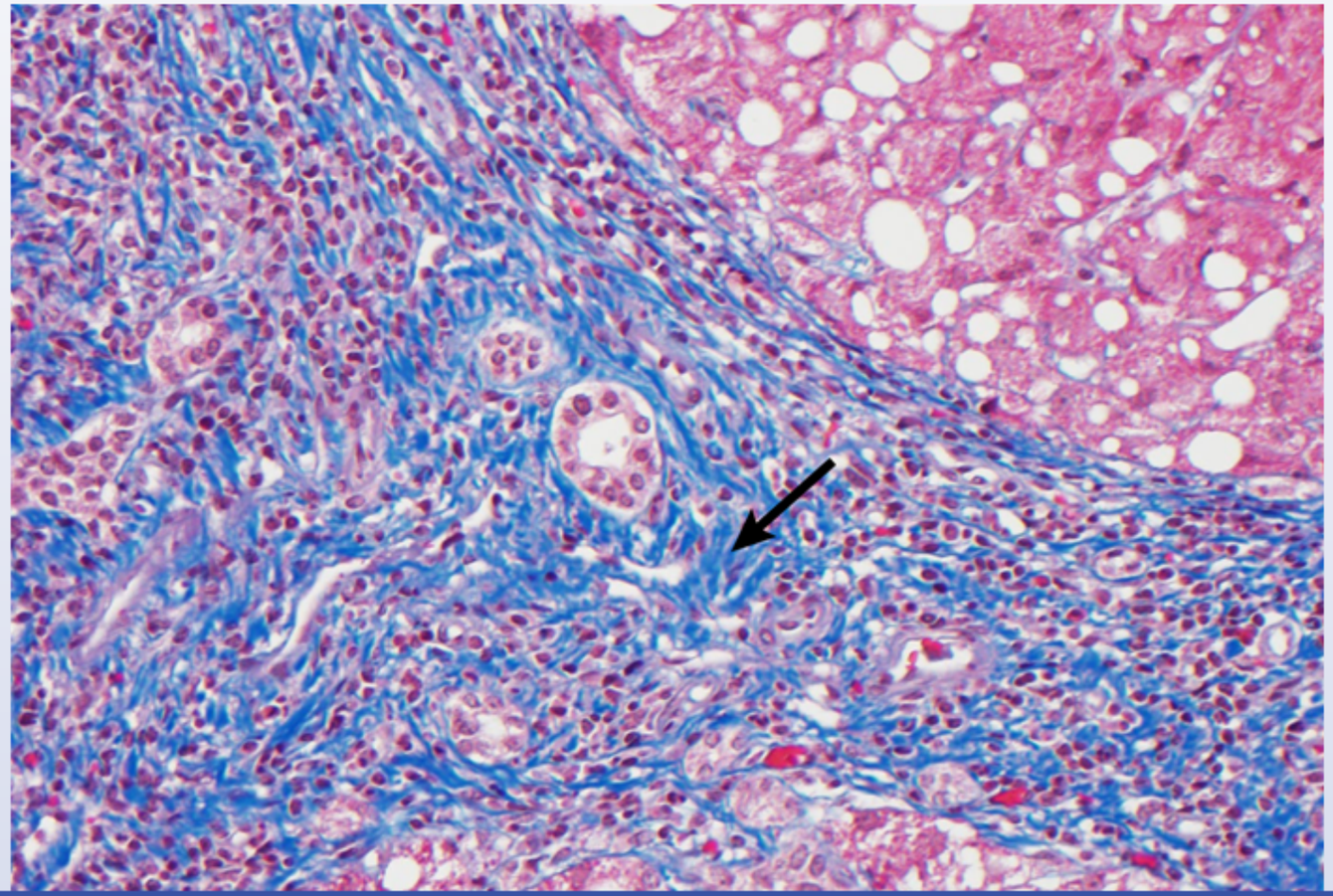

following:

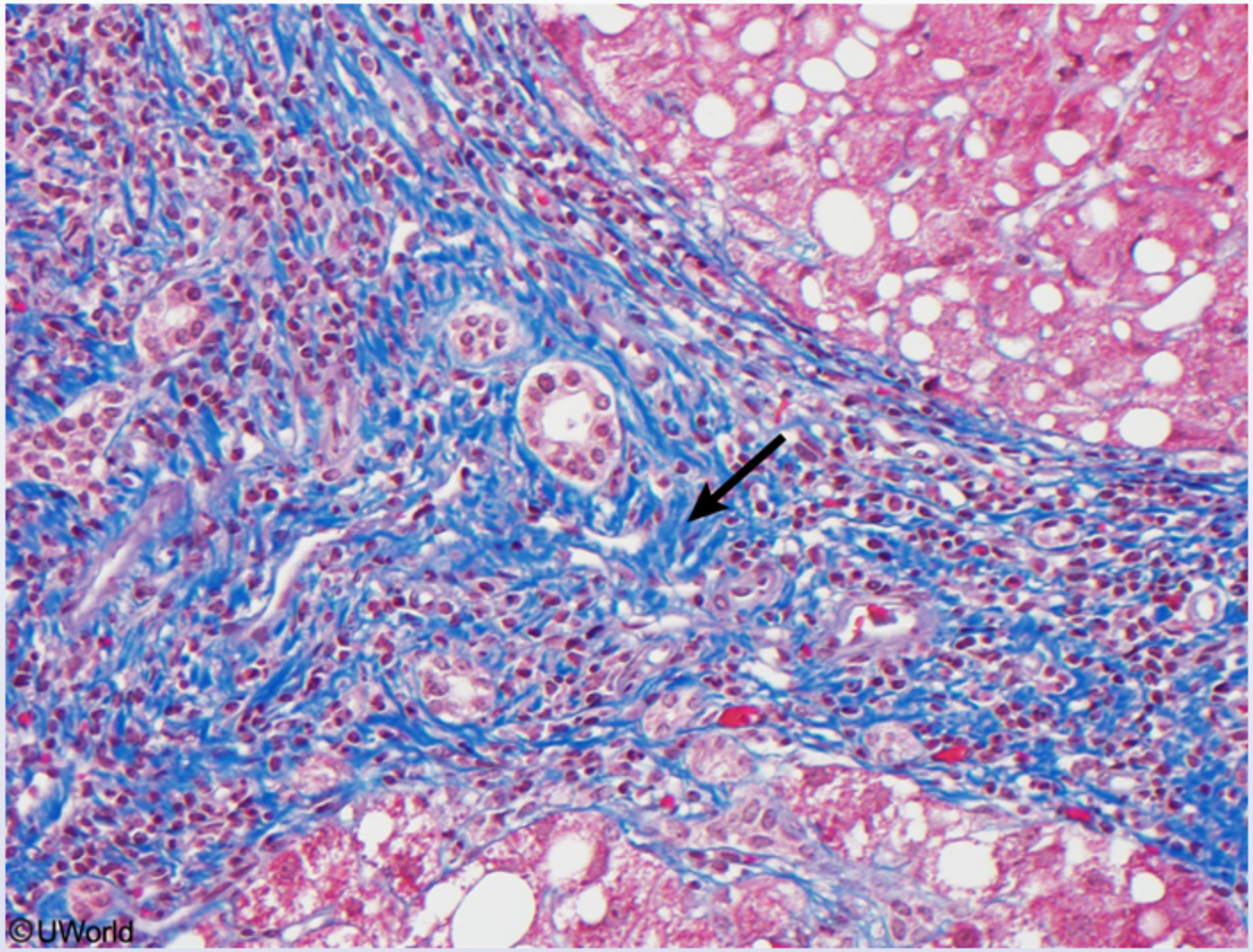

Which of the following cells is directly responsible for the histologic finding indicated by the arrow?

A. Cholangiocytes

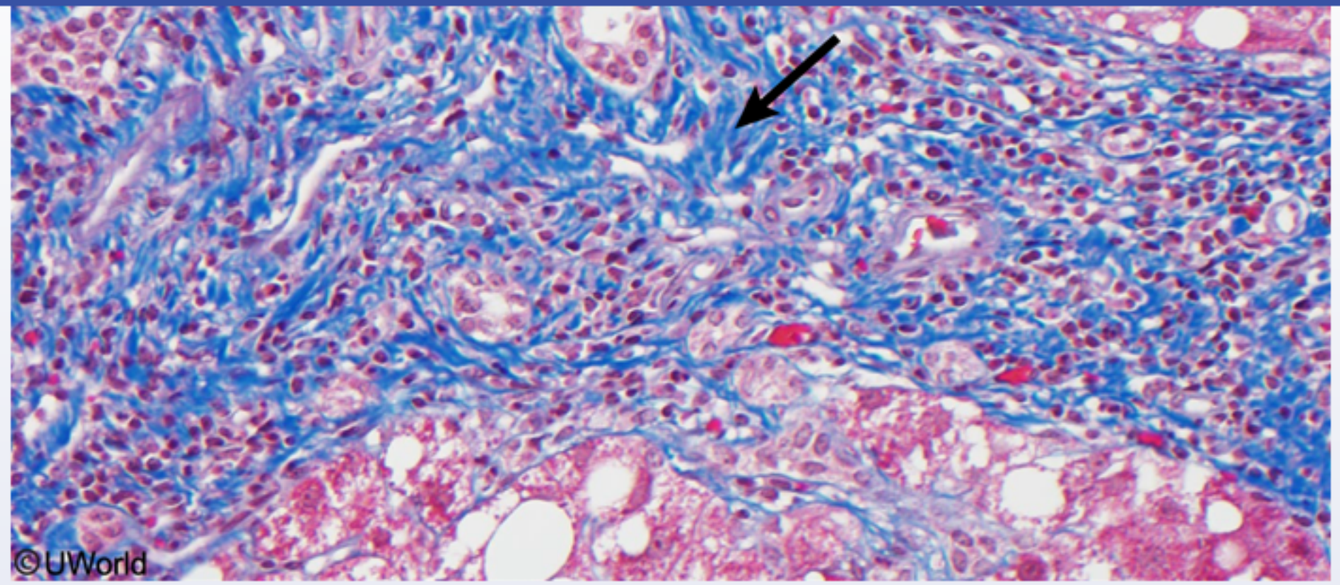

Which of the following cells is directly responsible for the histologic finding indicated by the arrow?

- A. Cholangiocytes
- B. Hepatocytes
- C. Kupffer cells
- D. Sinusoidal endothelial cells
- E. Stellate (Ito) cells

Submit

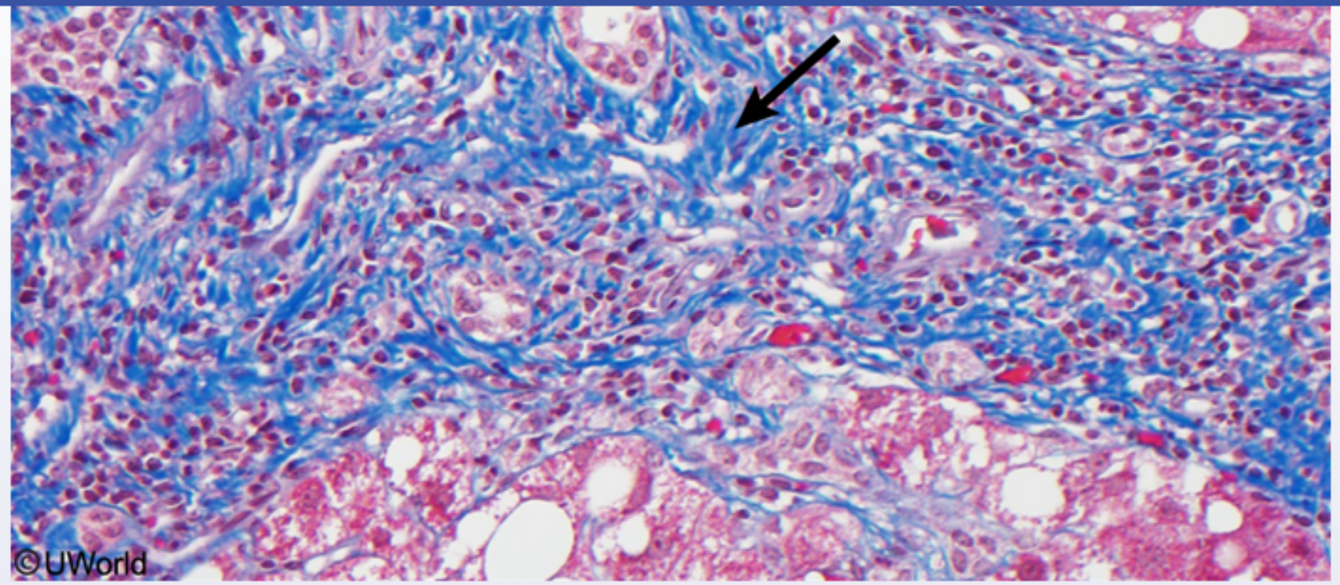

Which of the following cells is directly responsible for the histologic finding indicated by the arrow?

- A. Cholangiocytes (2%)
- B. Hepatocytes (5%)
- C. Kupffer cells (21%)
- D. Sinusoidal endothelial cells (9%)
- ✓ E. Stellate (Ito) cells (60%)

Omitted
Correct answer

60%
Answered correctly

09 secs
Time Spent

05/07/2020
Last Updated

Primary cells of the liver	
Cell type	**Function**
Cholangiocyte	• Bile duct epithelial cell • Transports solutes and electrolytes into bile
Hepatocyte	• Protein, cholesterol & bile synthesis, gluconeogenesis • Drug and fatty acid metabolism
Kupffer cell	• Macrophages within hepatic sinusoids • Phagocytosis of bacteria and RBCs
Stellate cell	• Quiescent phase: vitamin A storage • Activated phase: transform into myofibroblast to secrete collagen (primary cell involved in hepatic fibrosis)

RBC = red blood cell.

This patient with diabetes mellitus and morbid obesity has **hepatic cirrhosis**, likely due to long-standing nonalcoholic fatty liver disease (NAFLD). Cirrhosis is the end stage of multiple liver diseases and is characterized by replacement of normal lobular architecture with regenerating nodules separated by bridging fibrous septae.

Cirrhosis can be visualized histologically as **thickened collagenous bands** (which stain blue with Masson trichrome stain) separating clusters of hepatocytes. Fat infiltration (ie, hepatic steatosis, visible as clear vacuoles within the parenchyma) is commonly seen in both alcoholic fatty liver disease and NAFLD. In response to chronic injury, **stellate (Ito) cells** are activated and transform into **myofibroblasts** capable of proliferating, promoting chemotaxis, and **producing collagen** in large quantities. This leads to progressive scar formation and cirrhosis.

Manifestations of cirrhosis include jaundice, scleral icterus, spider angiomas, and elevated liver enzymes. Evidence of abnormal hepatic synthetic function (eg, abnormal coagulation parameters, hypoalbuminemia) and thrombocytopenia are also common.

(Choice A) Cholangiocytes are epithelial cells within the bile duct system. They transport ions and solutes into bile as it travels through the canaliculi.

RBC = red blood cell.

This patient with diabetes mellitus and morbid obesity has **hepatic cirrhosis**, likely due to long-standing nonalcoholic fatty liver disease (NAFLD). Cirrhosis is the end stage of multiple liver diseases and is characterized by replacement of normal lobular architecture with regenerating nodules separated by bridging fibrous septae.

Cirrhosis can be visualized histologically as **thickened collagenous bands** (which stain blue with Masson trichrome stain) separating clusters of hepatocytes. Fat infiltration (ie, hepatic steatosis, visible as clear vacuoles within the parenchyma) is commonly seen in both alcoholic fatty liver disease and NAFLD. In response to chronic injury, **stellate (Ito) cells** are activated and transform into **myofibroblasts** capable of proliferating, promoting chemotaxis, and **producing collagen** in large quantities. This leads to progressive scar formation and cirrhosis.

Manifestations of cirrhosis include jaundice, scleral icterus, spider angiomas, and elevated liver enzymes. Evidence of abnormal hepatic synthetic function (eg, abnormal coagulation parameters, hypoalbuminemia) and thrombocytopenia are also common.

(Choice A) Cholangiocytes are epithelial cells within the bile duct system. They transport ions and solutes into bile as it travels through the canaliculi.

(Choice B) Hepatocytes are located in the liver parenchyma and have many functions, including protein synthesis and storage, fatty acid metabolism, gluconeogenesis, cholesterol synthesis, and drug metabolism.

(Choice C) Kupffer cells are macrophages that reside within hepatic sinusoids. They are indirectly involved in fibrogenesis because they generate cytokines (ie, TNF-alpha) to assist in the activation of stellate cells; however, their primary function is bacterial phagocytosis and the clearance of red blood cells.

(Choice D) Sinusoidal endothelial cells, which line hepatic sinusoids, are fenestrated cells that filter solutes out of the blood and into hepatocytes. They assist in the removal of metabolic waste and other macromolecules from circulation.

Educational objective:
Stellate (Ito) cells are the primary cells involved in hepatic fibrosis. In response to hepatic injury, the stellate cells are activated and transform into myofibroblasts capable of proliferating, promoting chemotaxis, and producing large quantities of collagen. Collagen stains blue with Masson trichrome stain.

Manifestations of cirrhosis include jaundice, scleral icterus, spider angiomas, and elevated liver enzymes. Evidence of abnormal hepatic synthetic function (eg, abnormal coagulation parameters, hypoalbuminemia) and thrombocytopenia are also common.

(Choice A) Cholangiocytes are epithelial cells within the bile duct system. They transport ions and solutes into bile as it travels through the canaliculi.

(Choice B) Hepatocytes are located in the liver parenchyma and have many functions, including protein synthesis and storage, fatty acid metabolism, gluconeogenesis, cholesterol synthesis, and drug metabolism.

(Choice C) Kupffer cells are macrophages that reside within hepatic sinusoids. They are indirectly involved in fibrogenesis because they generate cytokines (ie, TNF-alpha) to assist in the activation of stellate cells; however, their primary function is bacterial phagocytosis and the clearance of red blood cells.

(Choice D) Sinusoidal endothelial cells, which line hepatic sinusoids, are fenestrated cells that filter solutes out of the blood and into hepatocytes. They assist in the removal of metabolic waste and other macromolecules from circulation.

Educational objective:
Stellate (Ito) cells are the primary cells involved in hepatic fibrosis. In response to hepatic injury, the stellate cells are activated and transform into myofibroblasts capable of proliferating, promoting chemotaxis, and producing large quantities of collagen. Collagen stains blue with Masson trichrome stain.

References

- Molecular pathogenesis of hepatic fibrosis and current therapeutic approaches.
- Physiology of cholangiocytes.
- Structural and functional aspects of the liver and liver sinusoidal cells in relation to colon carcinoma metastasis.

Histology	Gastrointestinal & Nutrition	Nonalcoholic fatty liver disease
Subject	System	Topic

Settings

1
2
3
4
5
6
7
8
9
10
11
12
13
14
15
16
17
18
19
20
21
22
23
24
25
26

Item 25 of 26
Question Id: 11890

Mark | Previous | Next | Full Screen | Tutorial | Lab Values | Notes | Calculator | Reverse Color | Text Zoom | Settings

A 34-year-old woman comes to the office with bleeding from the right nipple. The patient has noticed blood staining her undergarments on several occasions over the past week but has no fever or breast pain. She has no significant medical problems and does not take any medications. Breast examination shows no palpable masses or skin changes. Thin, blood-tinged discharge is expressed from the right nipple. There are no enlarged lymph nodes. Which of the following is the most likely histopathologic finding in this patient's right breast?

A. Atypical cells infiltrating the nipple skin

B. Cysts lined by metaplastic apocrine cells

C. Liquefactive necrosis of adipocytes with hemorrhage

D. Papillary cells with fibrovascular core

E. Stromal proliferation compressing the ducts to slits

Submit

Block Time Remaining: 00:02:34
TUTOR

8 | Feedback | Suspend | End Block

A 34-year-old woman comes to the office with bleeding from the right nipple. The patient has noticed blood staining her undergarments on several occasions over the past week but has no fever or breast pain. She has no significant medical problems and does not take any medications. Breast examination shows no palpable masses or skin changes. Thin, blood-tinged discharge is expressed from the right nipple. There are no enlarged lymph nodes. Which of the following is the most likely histopathologic finding in this patient's right breast?

- A. Atypical cells infiltrating the nipple skin (12%)
- B. Cysts lined by metaplastic apocrine cells (8%)
- C. Liquefactive necrosis of adipocytes with hemorrhage (11%)
- ✓ D. Papillary cells with fibrovascular core (55%)
- E. Stromal proliferation compressing the ducts to slits (11%)

Omitted
Correct answer
D

55%
Answered correctly

02 secs
Time Spent

02/20/2020
Last Updated

Explanation

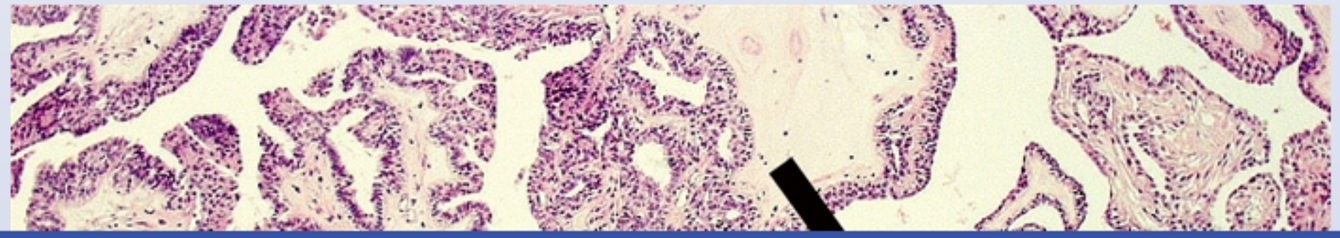

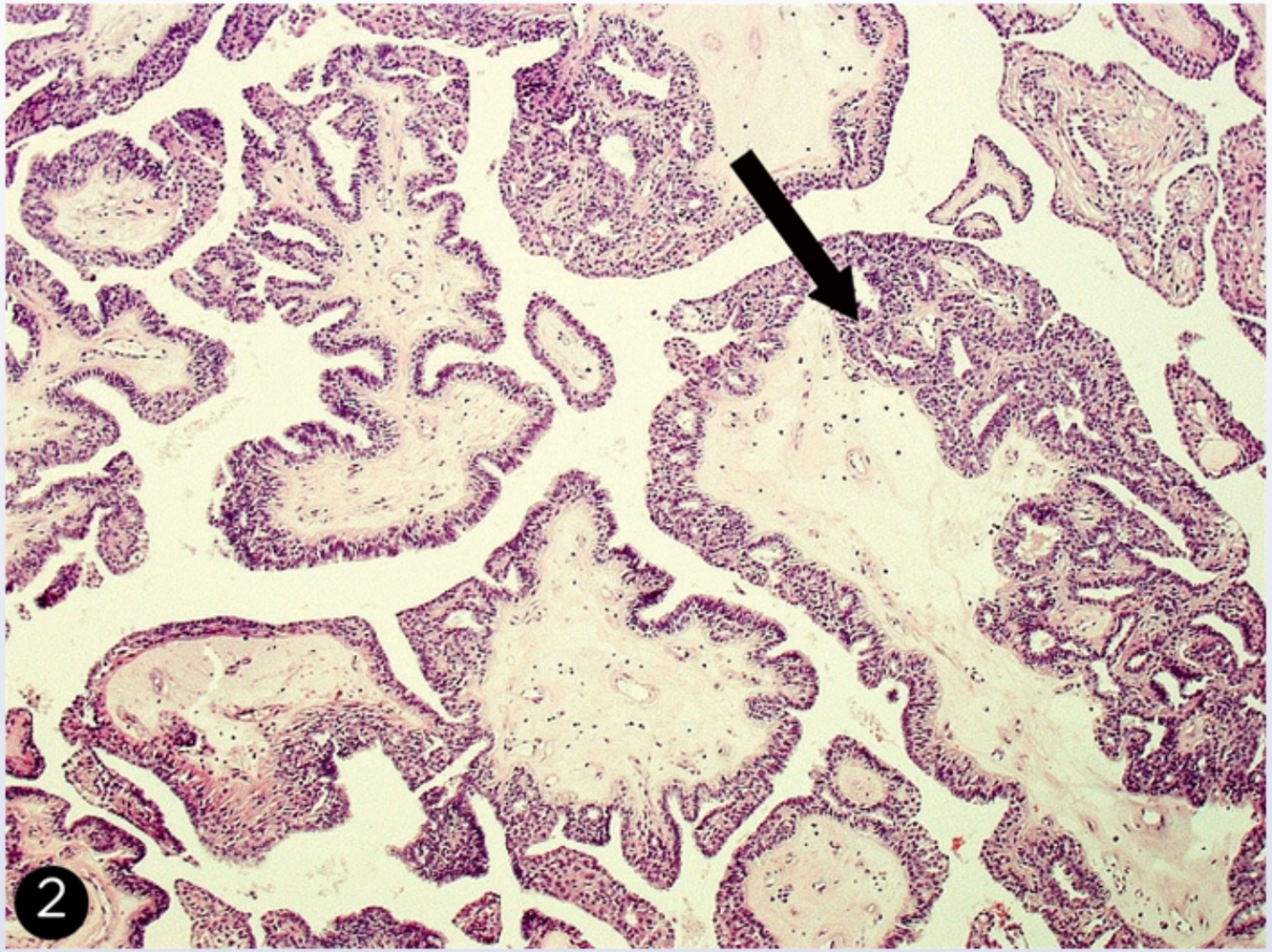

Nipple discharge can be physiologic (bilateral, nonbloody, or milky without masses or skin changes) or pathologic (**bloody** or serosanguineous and **unilateral** with/without palpable masses and skin changes). **Intraductal papilloma** is the most common cause of alarming bloody or serosanguineous (eg, blood-tinged) nipple discharge. Affected patients typically have no associated breast mass or skin changes. Intraductal

Nipple discharge can be physiologic (bilateral, nonbloody, or milky without masses or skin changes) or pathologic (**bloody** or serosanguineous and **unilateral** with/without palpable masses and skin changes). **Intraductal papilloma** is the most common cause of alarming bloody or serosanguineous (eg, blood-tinged) nipple discharge. Affected patients typically have no associated breast mass or skin changes. Intraductal papilloma is caused by a proliferation of papillary cells (black arrow) in a duct or cyst wall with a fibrovascular core and may contain foci of atypia or ductal carcinoma in situ. The bloody discharge results from twisting of the vascular stalk of the papilloma in the duct.

(Choice A) Paget disease of the nipple is characterized by an eczematous exudate over the nipple and areola and is due to ductal spread of malignant cells (black arrow) to the nipple surface. Occasionally, bloody nipple discharge may be present.

(Choice B) Fibrocystic changes of the breast involve diffuse small cysts (black arrow) with or without metaplasia and frequently cause cyclic breast pain without nipple discharge.

(Choice C) Fat necrosis is preceded by localized trauma and typically presents as an irregular breast mass without nipple discharge. Histology shows liquefactive necrosis of adipocytes (black arrow) with hemorrhage (green arrow).

(Choice E) Fibroadenomas are small, firm, and mobile breast masses that occur due to proliferation of breast stroma and ducts, with stromal proliferation compressing the ducts to slits (black arrow) on microscopic examination.

Educational objective:
Intraductal papilloma is a proliferation of papillary cells in a cyst wall or duct that may contain focal atypia. It is the most common cause of bloody nipple discharge and typically presents without breast masses or skin changes.

References

- Evaluating nipple discharge.
- Common breast problems.

Histology	Female Reproductive System & Breast	Intraductal papilloma
Subject	System	Topic

Copyright © UWorld. All rights reserved.

Settings

1
2
3
4
5
6
7
8
9
10
11
12
13
14
15
16
17
18
19
20
21
22
23
24
25
26

Item 25 of 26
Question Id: 11890

Mark | Previous | Next | Full Screen | Tutorial | Lab Values | Notes | Calculator | Reverse Color | Text Zoom | Settings

Nipple discharge can be physiologic (bilateral, nonbloody, or milky without masses or skin changes) or pathologic (**bloody** or serosanguineous

Exhibit Display

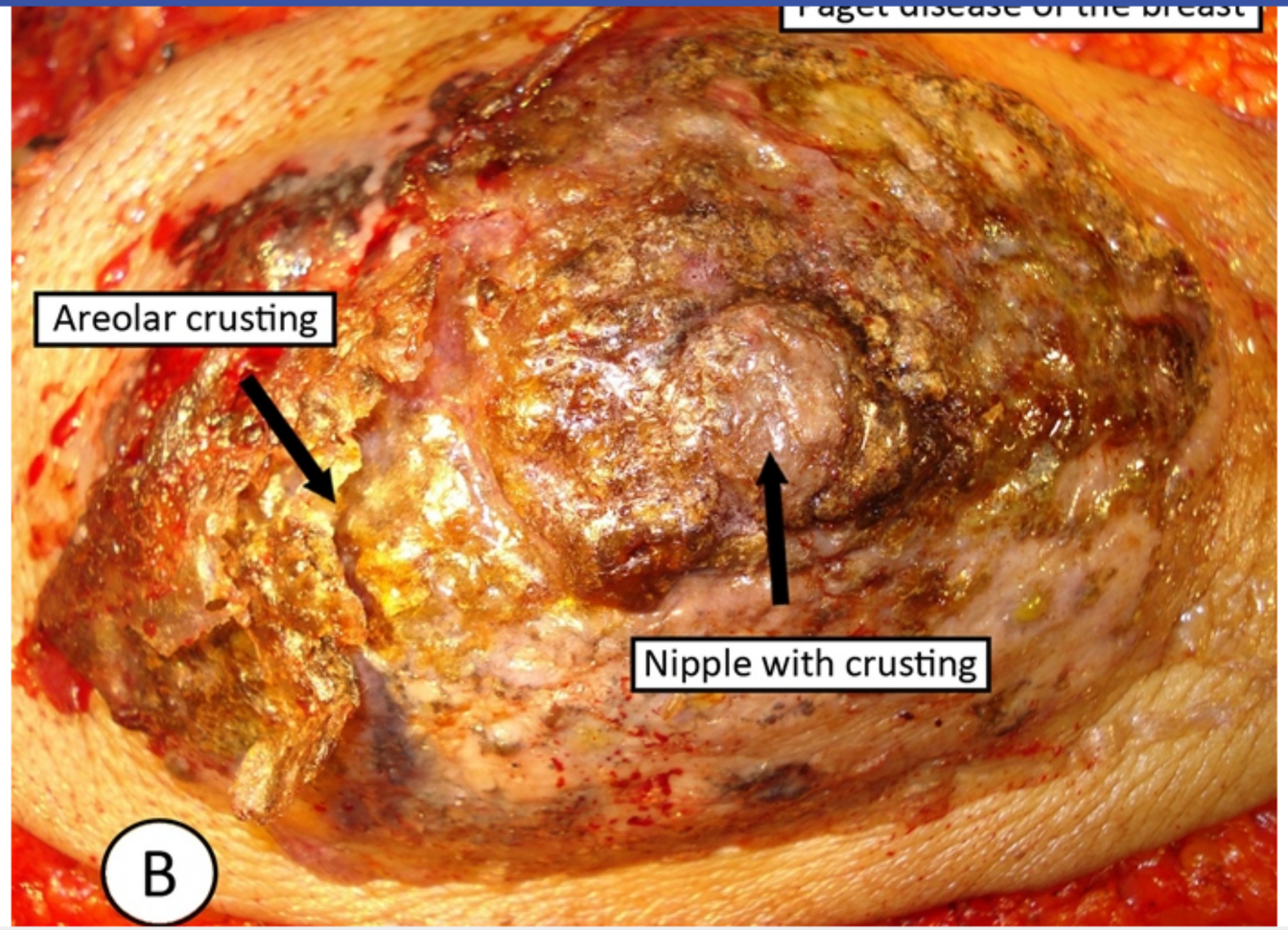

Zoom In | Zoom Out | Reset | Add To New Card | Existing Card

Block Time Remaining: 00:02:35
TUTOR

8 | Feedback | Suspend | End Block

Settings

1
2
3
4
5
6
7
8
9
10
11
12
13
14
15
16
17
18
19
20
21
22
23
24
25
26

Item 25 of 26
Question Id: 11890

Mark | Previous | Next | Full Screen | Tutorial | Lab Values | Notes | Calculator | Reverse Color | Text Zoom | Settings

Nipple discharge can be physiologic (bilateral, nonbloody, or milky without masses or skin changes) or pathologic (**bloody** or serosanguineous

Exhibit Display

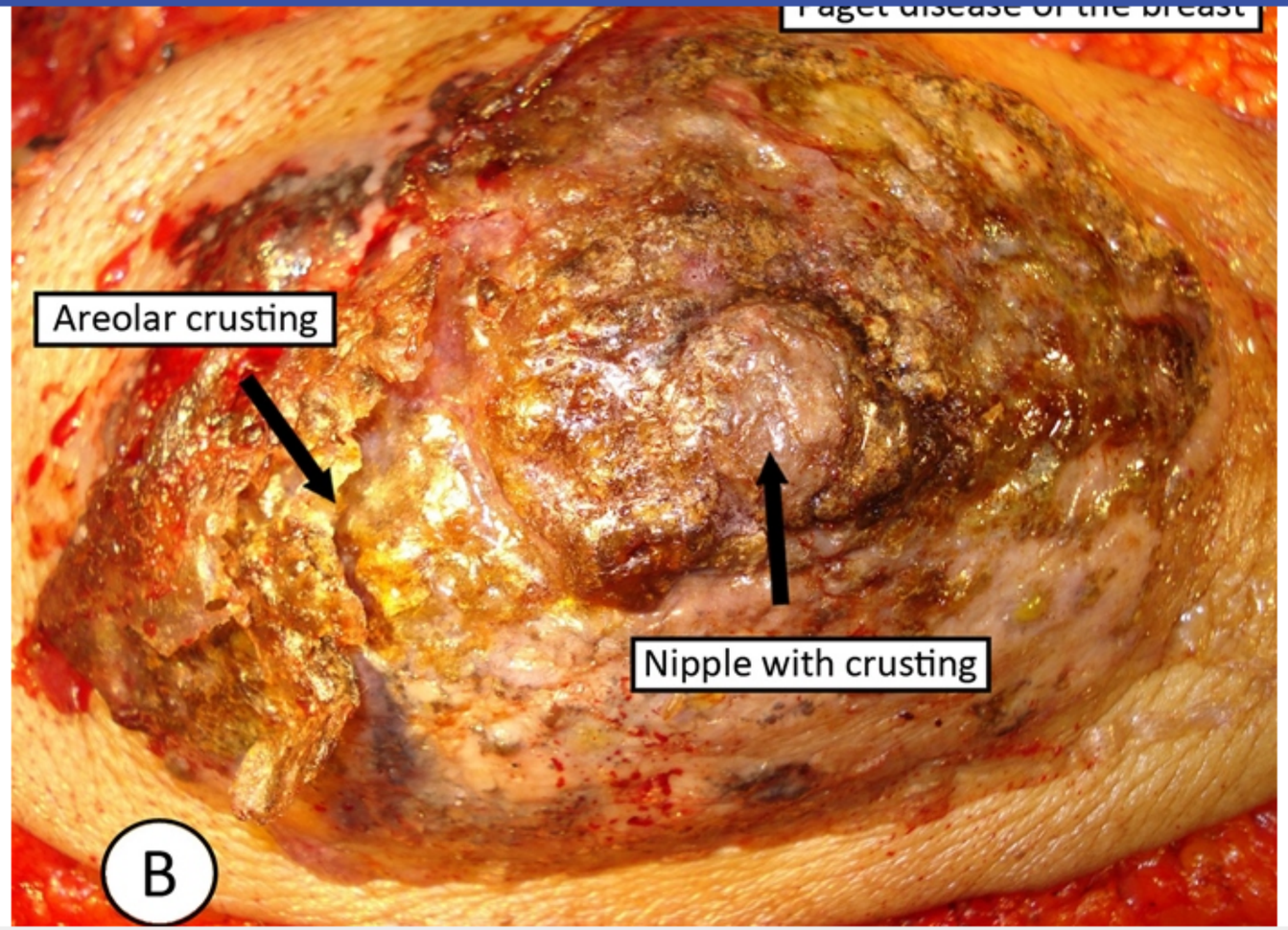

Zoom In | Zoom Out | Reset | Add To New Card | Existing Card

Block Time Remaining: 00:02:35
TUTOR

8 | Feedback | Suspend | End Block

Settings

1
2
3
4
5
6
7
8
9
10
11
12
13
14
15
16
17
18
19
20
21
22
23
24
25
26

Item 25 of 26
Question Id: 11890

Mark | Previous | Next | Full Screen | Tutorial | Lab Values | Notes | Calculator | Reverse Color | Text Zoom | Settings

Nipple discharge can be physiologic (bilateral, nonbloody, or milky without masses or skin changes) or pathologic (**bloody** or serosanguineous

Exhibit Display

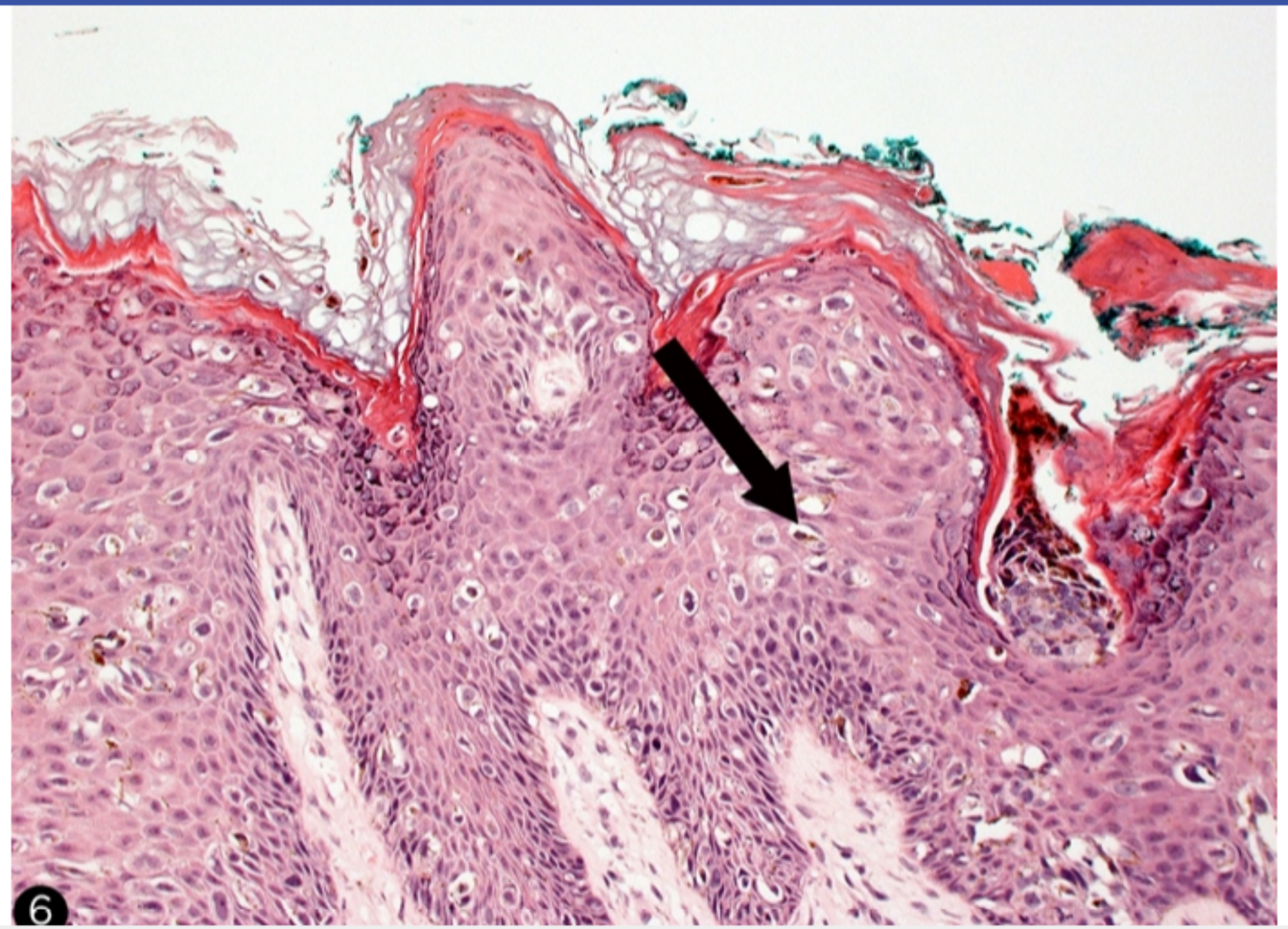

Zoom In | Zoom Out | Reset | Add To New Card | Existing Card

Block Time Remaining: 00:02:35
TUTOR

8 | Feedback | Suspend | End Block

Settings

1
2
3
4
5
6
7
8
9
10
11
12
13
14
15
16
17
18
19
20
21
22
23
24
25
26

Item 25 of 26
Question Id: 11890

Mark | Previous | Next | Full Screen | Tutorial | Lab Values | Notes | Calculator | Reverse Color | Text Zoom | Settings

Nipple discharge can be physiologic (bilateral, nonbloody, or milky without masses or skin changes) or pathologic (**bloody** or serosanguineous

Exhibit Display

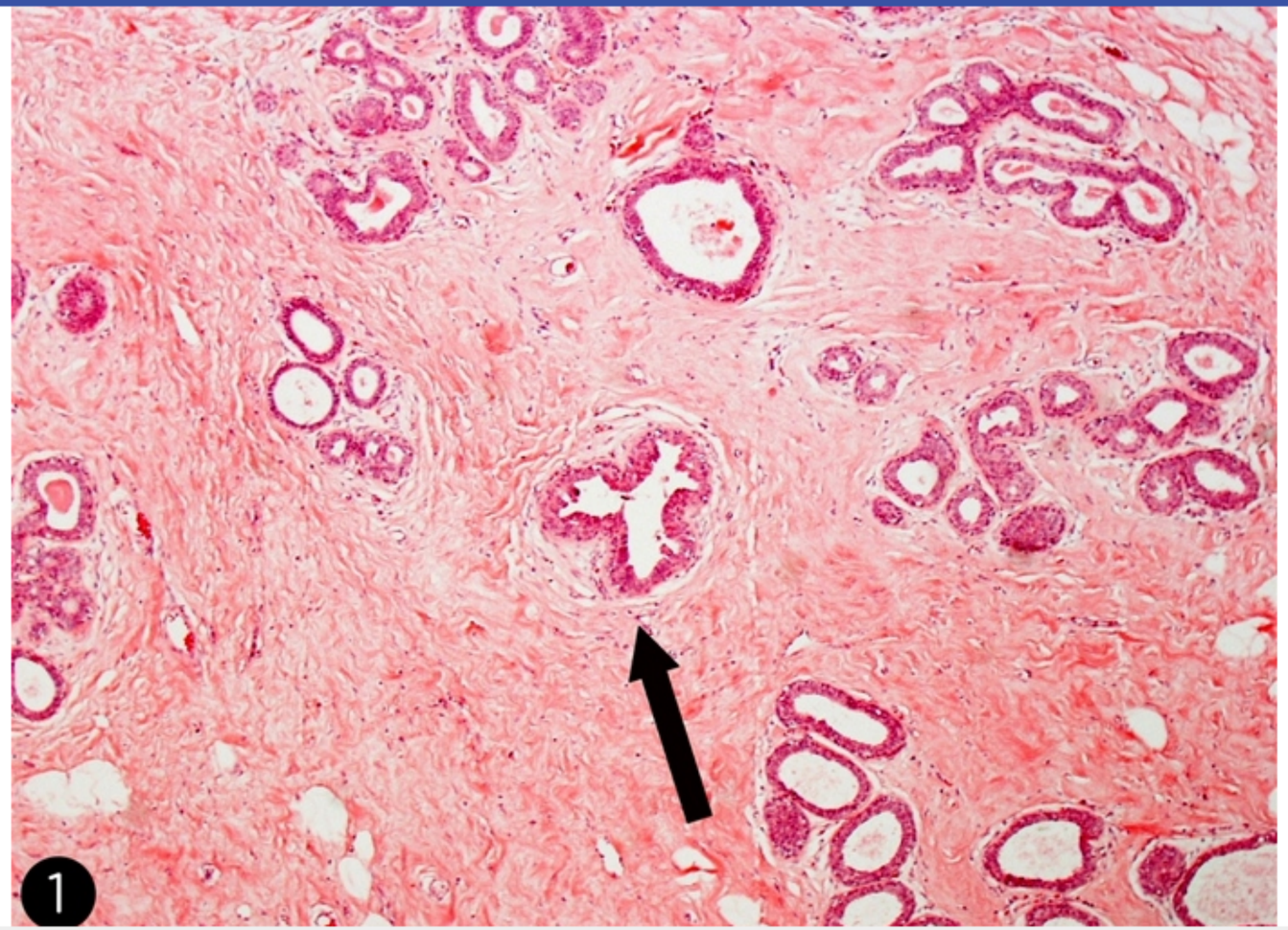

Zoom In | Zoom Out | Reset | Add To New Card | Existing Card

Block Time Remaining: 00:02:35
TUTOR

8 | Feedback | Suspend | End Block

Settings

1
2
3
4
5
6
7
8
9
10
11
12
13
14
15
16
17
18
19
20
21
22
23
24
25
26

Item 25 of 26
Question Id: 11890

Mark | Previous | Next | Full Screen | Tutorial | Lab Values | Notes | Calculator | Reverse Color | Text Zoom | Settings

Nipple discharge can be physiologic (bilateral, nonbloody, or milky without masses or skin changes) or pathologic (**bloody** or serosanguineous

Exhibit Display

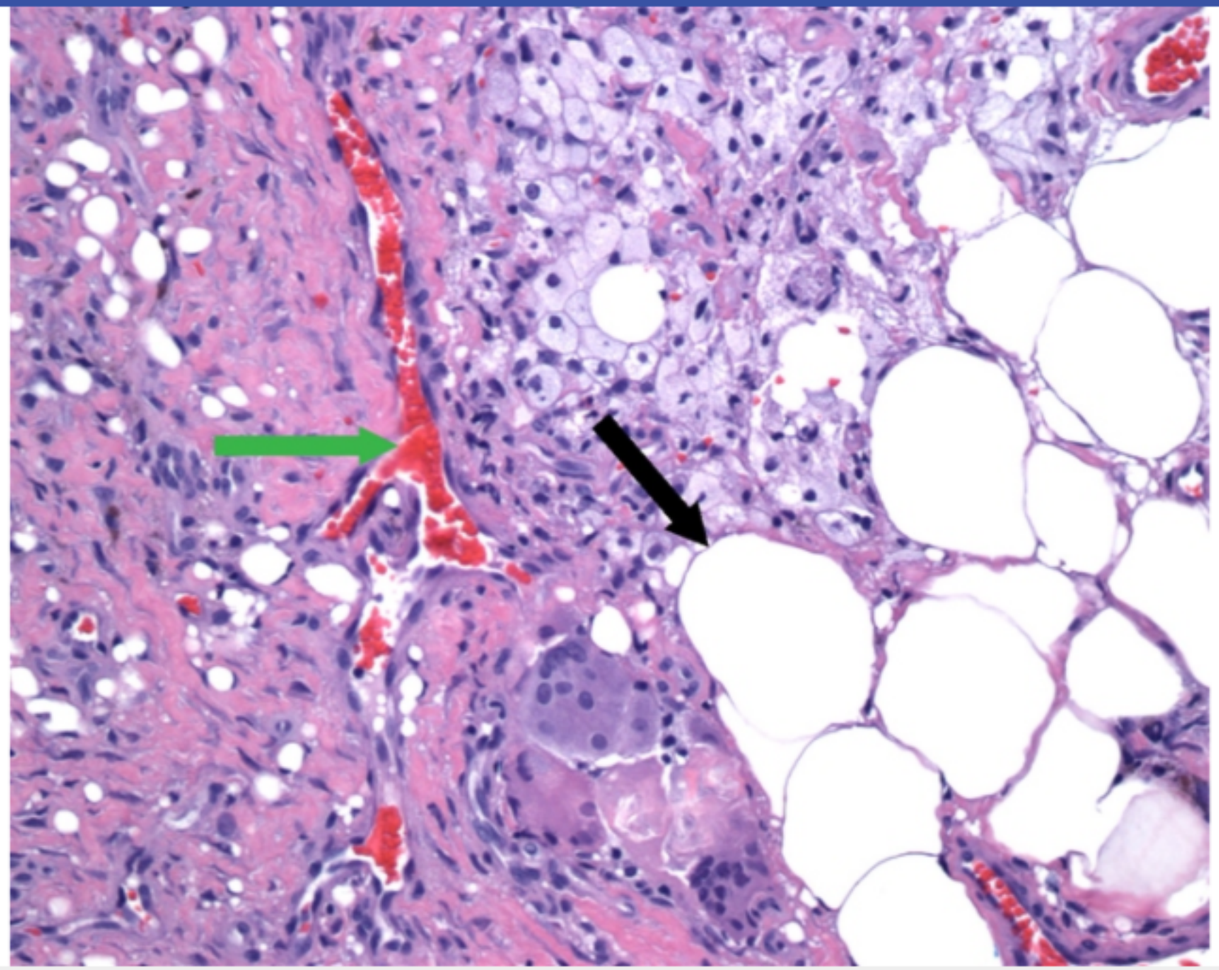

Zoom In | Zoom Out | Reset | Add To New Card | Existing Card

Block Time Remaining: 00:02:35
TUTOR

8 | Feedback | Suspend | End Block

Nipple discharge can be physiologic (bilateral, nonbloody, or milky without masses or skin changes) or pathologic (**bloody** or serosanguineous

Exhibit Display

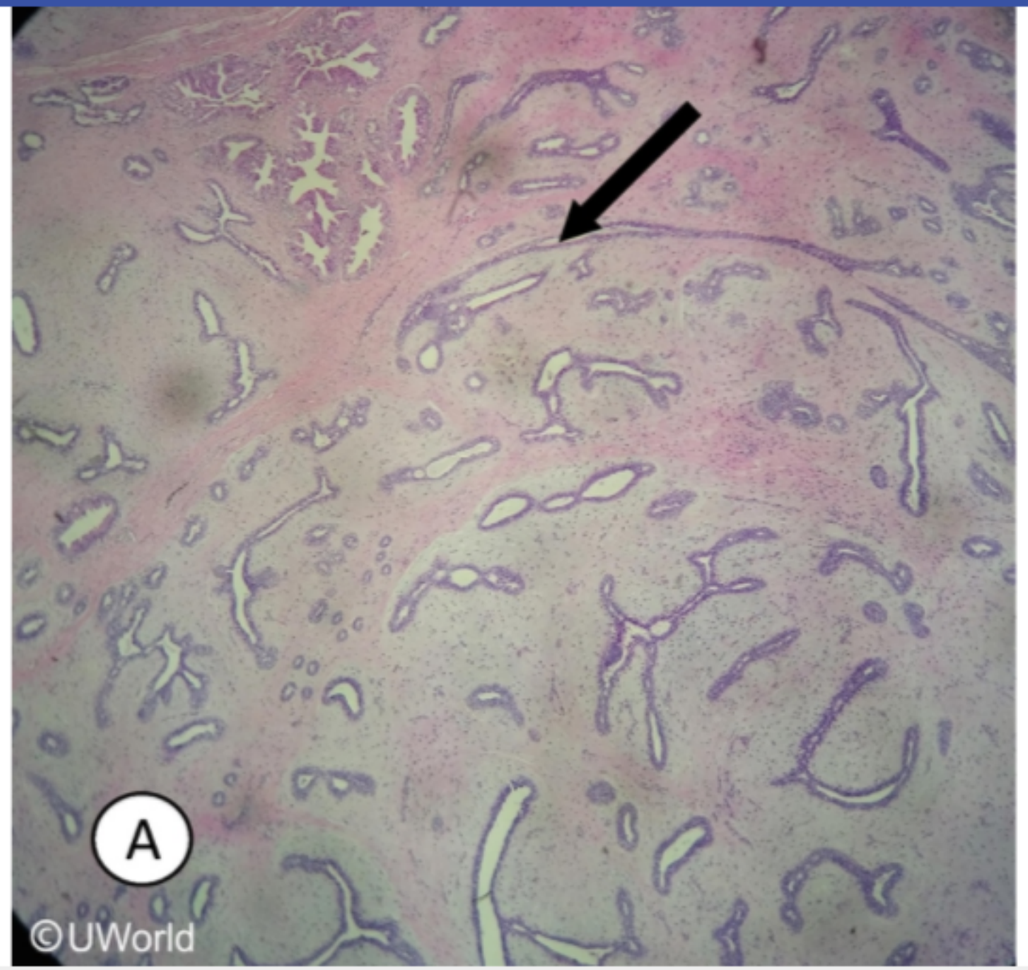

Zoom In | Zoom Out | Reset | Add To New Card | Existing Card

A 17-year-old boy comes to the office due to a facial lesion. The patient noticed a small area of rough skin on his lower lip several weeks ago, which has progressively enlarged. He reports no pain or itching. The patient had eczema during early childhood but has had no other chronic medical conditions. Vital signs are within normal limits. Physical examination findings are shown in the exhibit. There are no other skin rashes, oral lesions, or enlarged lymph nodes. Which of the following histopathological findings are most likely present in this patient's skin lesion?

A. Acantholysis and multinucleated giant epithelial cells

B. Epidermal hyperplasia and cytoplasmic vacuolization

C. Subcorneal bacterial collection and neutrophilic infiltration

D. Subepidermal linear complement deposits and separation

Submit

A 17-year-old boy comes to the office due to a facial lesion. The patient noticed a small area of rough skin on his lower lip several weeks ago, which has progressively enlarged. He reports no pain or itching. The patient had eczema during early childhood but has had no other chronic medical conditions. Vital signs are within normal limits. Physical examination findings are shown in the exhibit. There are no other skin rashes, oral lesions, or enlarged lymph nodes. Which of the following histopathological findings are most likely present in this patient's skin lesion?

A. Acantholysis and multinucleated giant epithelial cells (27%)

✓ B. Epidermal hyperplasia and cytoplasmic vacuolization (65%)

C. Subcorneal bacterial collection and neutrophilic infiltration (3%)

D. Subepidermal linear complement deposits and separation (3%)

Omitted
Correct answer
B

65%
Answered correctly

02 secs
Time Spent

05/19/2020
Last Updated

Explanation

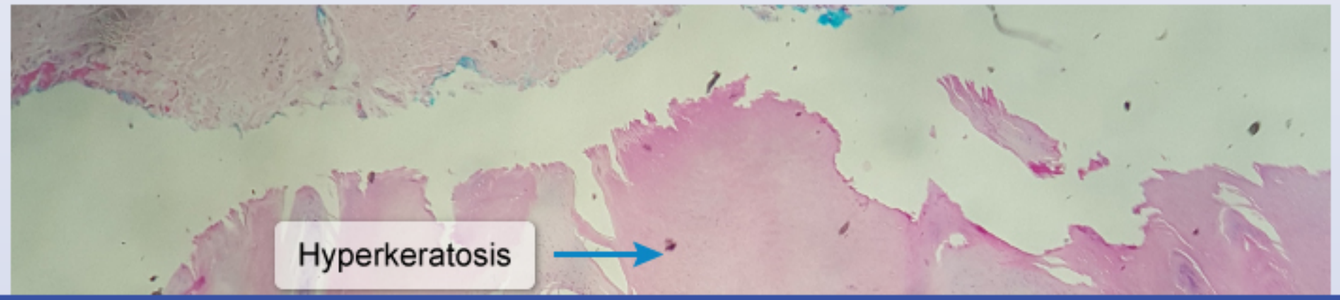

Settings

1
2
3
4
5
6
7
8
9
10
11
12
13
14
15
16
17
18
19
20
21
22
23
24
25
26

Item 26 of 26
Question Id: 15363

Mark | Previous | Next | Full Screen | Tutorial | Lab Values | Notes | Calculator | Reverse Color | Text Zoom | Settings

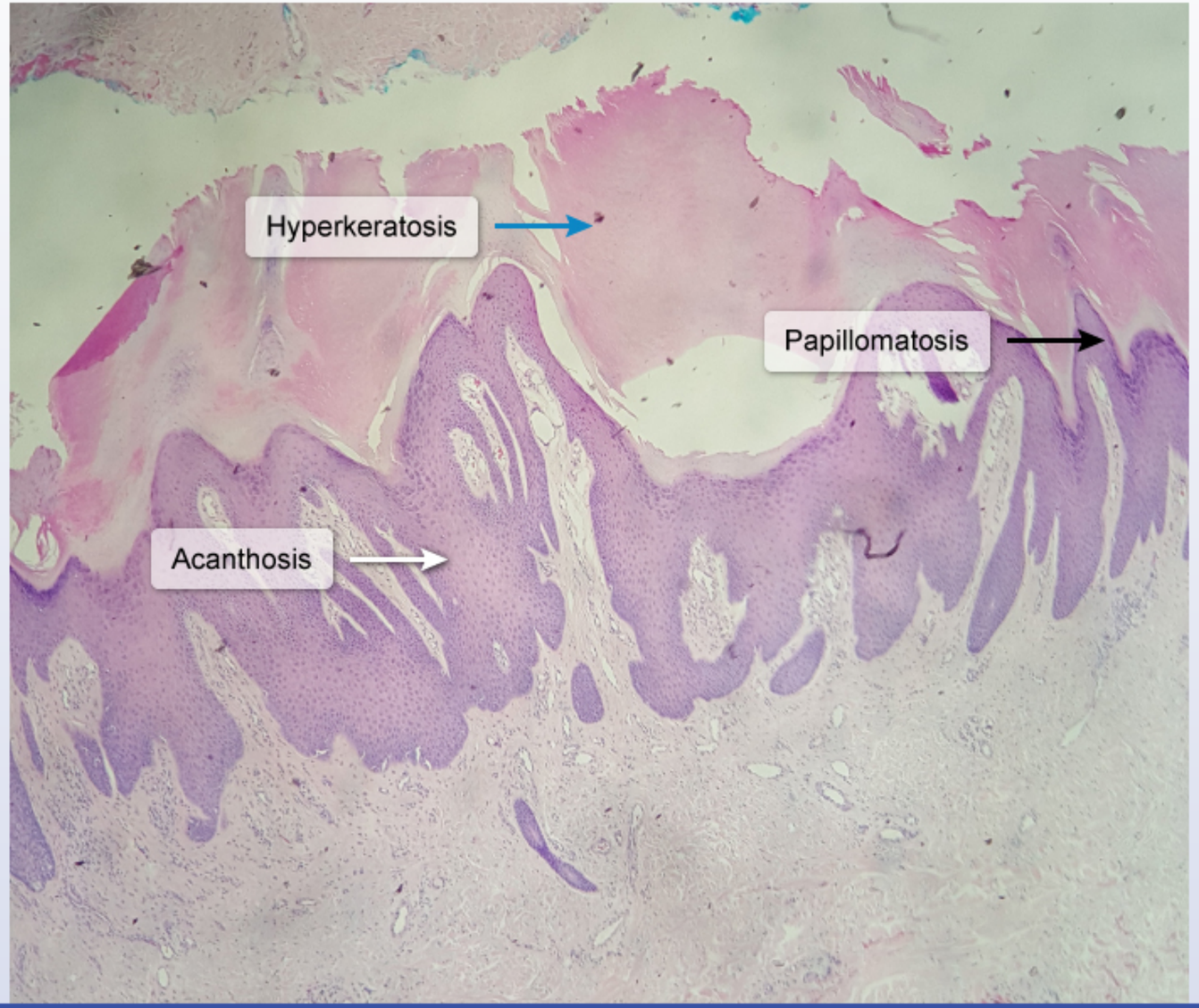

Block Time Remaining: 00:02:37
TUTOR

0 | Feedback | Suspend | End Block

Settings

1
2
3
4
5
6
7
8
9
10
11
12
13
14
15
16
17
18
19
20
21
22
23
24
25
26

Item 26 of 26
Question Id: 15363

Mark | Previous | Next | Full Screen | Tutorial | Lab Values | Notes | Calculator | Reverse Color | Text Zoom | Settings

Exhibit Display

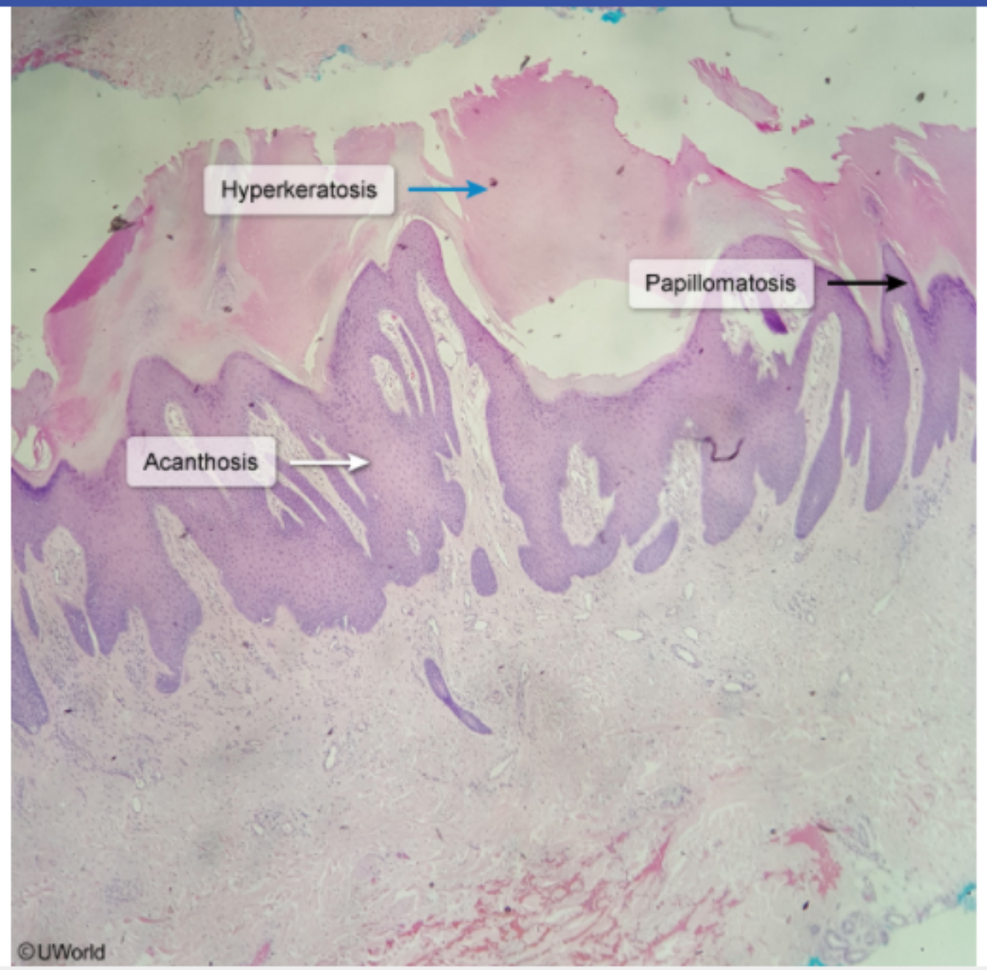

Zoom In | Zoom Out | Reset | Add To Flash Card

Block Time Remaining: 00:02:37
TUTOR

0 | Feedback | Suspend | End Block

This patient has a common **cutaneous wart** (ie, verruca vulgaris). Cutaneous warts are caused by **human papillomavirus**, which also causes anogenital warts (ie, condyloma acuminata). The virus is usually transmitted by direct contact and is most common in children, adolescents, and young adults.

Cutaneous warts typically present as **skin-colored papules** or well-circumscribed plaques. They may also form complex filiform lesions. On the palms or soles (ie, palmar, plantar warts), they commonly present as tender plaques or nodules that disrupt the normal skin striae.

The diagnosis of cutaneous warts is often apparent based on gross findings. Key findings on magnified view (ie, dermoscopy) include a roughened surface and **small black dots** representing **thrombosed capillaries**. Biopsy is usually not needed but can confirm the diagnosis in atypical cases. Histopathologic findings include:

- **Epidermal hyperplasia** (acanthosis) with eosinophilic inclusions and keratohyaline granules
- Thickened stratum corneum (**hyperkeratosis**)
- **Papilloma** formation
- Perinuclear **cytoplasmic vacuolization** (koilocytosis)

(Choice A) Intraepidermal fracturing (acantholysis) and formation of multinucleated cells are seen in herpes simplex labialis. Although this condition is often found on the lips and perioral skin, it presents with acute/recurrent blisters and ulcers.

(Choice C) Impetigo is a gram-positive skin infection that generates a neutrophilic infiltrate. It presents with erythema, blistering, and shallow ulcers with honey-colored crusts.

(Choice D) Bullous pemphigoid is an autoimmune disorder associated with antibodies against hemidesmosomes, leading to subepidermal complement activation and cleavage. It is most common at age >60 and typically presents with pruritic plaques, erosions, and tense bullae.

Educational objective:
Cutaneous warts (ie, verruca vulgaris) are caused by human papillomavirus and typically present as rough, skin-colored papules. If necessary, biopsy can confirm the diagnosis and shows epidermal hyperplasia, thickened stratum corneum, papilloma formation, and cytoplasmic vacuolization.

References

Settings

1
2
3
4
5
6
7
8
9
10
11
12
13
14
15
16
17
18
19
20
21
22
23
24
25
26

Item 26 of 26
Question Id: 15363

Mark | Previous | Next | Full Screen | Tutorial | Lab Values | Notes | Calculator | Reverse Color | Text Zoom | Settings

Exhibit Display

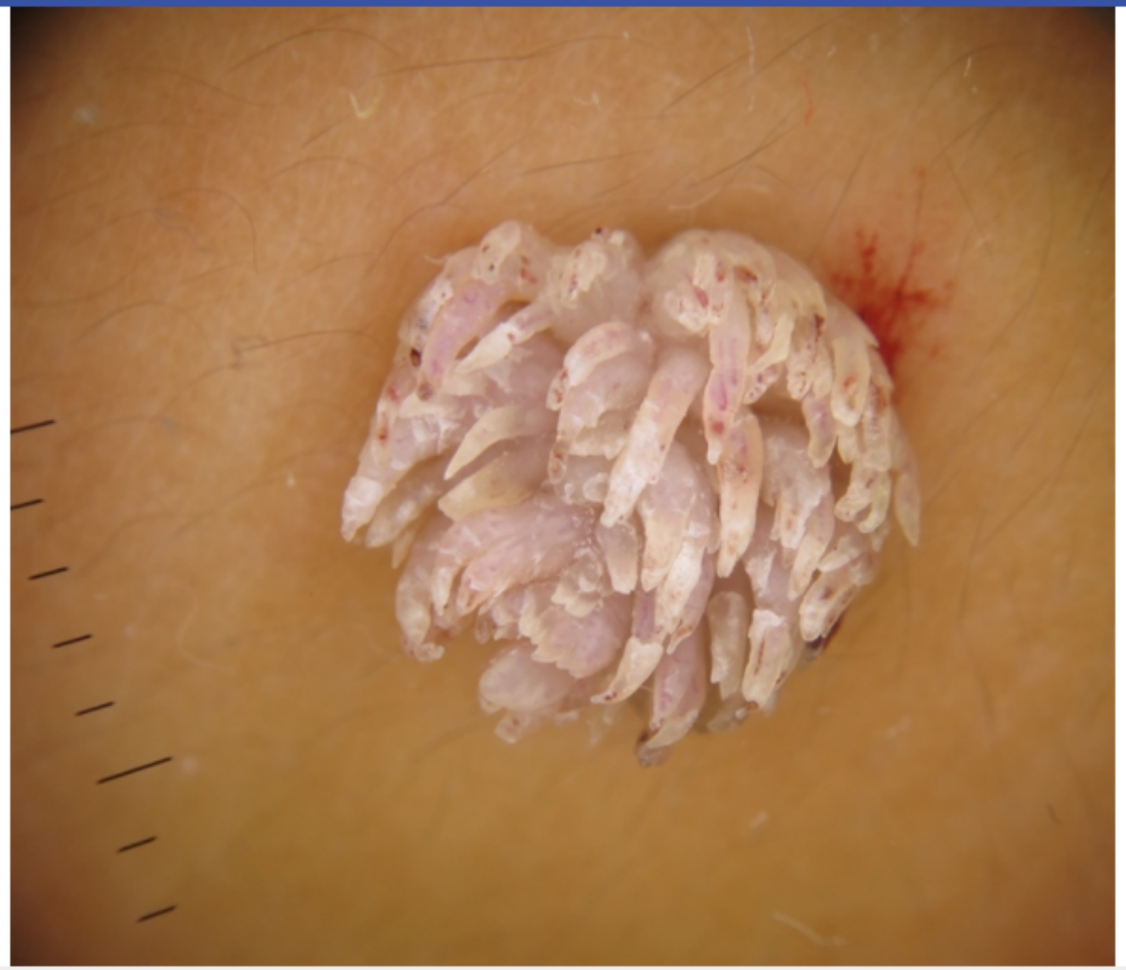

Zoom In | Zoom Out | Reset | Add To Flash Card

References

Block Time Remaining: 00:02:37
TUTOR

0 | Feedback | Suspend | End Block

Settings

1
2
3
4
5
6
7
8
9
10
11
12
13
14
15
16
17
18
19
20
21
22
23
24
25
26

Item 26 of 26
Question Id: 15363

Mark | Previous | Next | Full Screen | Tutorial | Lab Values | Notes | Calculator | Reverse Color | Text Zoom | Settings

Exhibit Display

Zoom In | Zoom Out | Reset | Add To Flash Card

References

Block Time Remaining: 00:02:37
TUTOR

0 | Feedback | Suspend | End Block

Settings

1
2
3
4
5
6
7
8
9
10
11
12
13
14
15
16
17
18
19
20
21
22
23
24
25
26

Item 26 of 26
Question Id: 15363

Mark | Previous | Next | Full Screen | Tutorial | Lab Values | Notes | Calculator | Reverse Color | Text Zoom | Settings

Exhibit Display

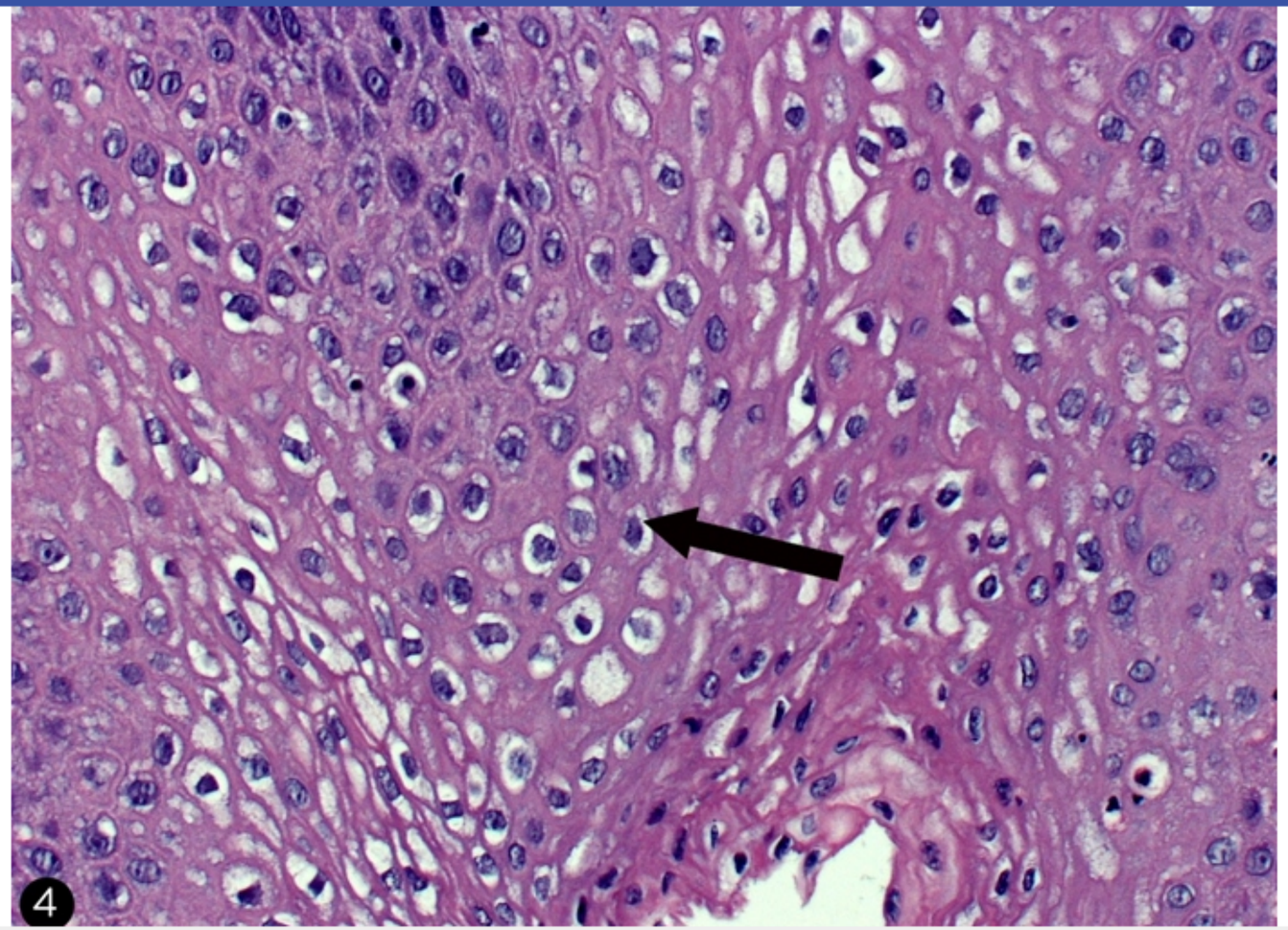

Zoom In | Zoom Out | Reset | Add To Flash Card

References

Block Time Remaining: 00:02:37
TUTOR

0 | Feedback | Suspend | End Block

Settings

1
2
3
4
5
6
7
8
9
10
11
12
13
14
15
16
17
18
19
20
21
22
23
24
25
26

Item 26 of 26
Question Id: 15363

Mark | Previous | Next | Full Screen | Tutorial | Lab Values | Notes | Calculator | Reverse Color | Text Zoom | Settings

Exhibit Display

Zoom In | Zoom Out | Reset | Add To Flash Card

References

Block Time Remaining: 00:02:37
TUTOR

0 | Feedback | Suspend | End Block

Settings

1
2
3
4
5
6
7
8
9
10
11
12
13
14
15
16
17
18
19
20
21
22
23
24
25
26

Item 26 of 26
Question Id: 15363

Mark | Previous | Next | Full Screen | Tutorial | Lab Values | Notes | Calculator | Reverse Color | Text Zoom | Settings

anogenital warts (ie, condyloma acuminata). The virus is usually transmitted by direct contact and is most common in children, adolescents, and

Exhibit Display

Zoom In | Zoom Out | Reset | Add To Flash Card

Block Time Remaining: 00:02:37
TUTOR

0 | Feedback | Suspend | End Block

Settings

1
2
3
4
5
6
7
8
9
10
11
12
13
14
15
16
17
18
19
20
21
22
23
24
25
26

Item 26 of 26
Question Id: 15363

Mark | Previous | Next | Full Screen | Tutorial | Lab Values | Notes | Calculator | Reverse Color | Text Zoom | Settings

anogenital warts (ie, condyloma acuminata). The virus is usually transmitted by direct contact and is most common in children, adolescents, and

Exhibit Display

Zoom In | Zoom Out | Reset | Add To Flash Card

Block Time Remaining: 00:02:37
TUTOR

0 | Feedback | Suspend | End Block